



DATE PRESENTING CLINICAL SIGNS

05/15/26 Patient History: Elevated ALP and cholesterol on pre-op BW for removal of sebaceous epithelioma.

PATIENT Current Medications: None.

Labwork Results: Labwork attached.

Rocky Kaifer Date of Previous IntraPet Ultrasound: No previous.

Sedation: Not required to complete full diagnostic ultrasound.

Stat Report: Declined at this time.

SPECIES Imaging Performed by: Stephanie Warga RDCS, RVT.

Canine

ULTRASONOGRAPHIC EXAMINATION OF THE ABDOMEN

BREED *Urinary System*

Goldendoodle The urinary bladder is moderately distended with anechoic urine. The bladder wall, trigone, ureteral papillae and visible urethra (to a depth of 2.0 cm) appear normal with no evidence of wall thickening, mucosal irregularities, masses or cystic calculi.

SEX

Neutered Male

The prostate is normal in size (0.78 cm) and shape for this neutered male dog. The parenchyma is homogenous and the external margins are smooth. The prostatic urethra appears normal with no evidence of irregularity, invasion, mass effect or calculi.

AGE

05/07/16

The left kidney has a normal shape and size (6.57 cm). Overall echogenicity is normal with adequate corticomedullary distinction and a typical 1:3 cortex:medulla ratio. There is no evidence of focal perinephric inflammation or effusion. There is no evidence of pyelectasia, nephroliths, infarcts or hydroureter. Renal vasculature is normal.

WEIGHT

46 lbs

The right kidney has a normal shape and size (7.14 cm). Overall echogenicity is normal with adequate corticomedullary distinction and a typical 1:3 cortex:medulla ratio. There is no evidence of focal perinephric inflammation or effusion. There is no evidence of pyelectasia, nephroliths, infarcts or hydroureter. Renal vasculature is normal.

INTERPRETED BY

Kathleen Sennello
DVM, MS, Diplomate
ACVIM (Small animal
Internal Medicine)

Adrenal Glands

The left adrenal gland is normal in size measuring 0.79 cm at the cranial pole and 0.7 cm at the caudal pole. It is observed in its normal position cranial to the left renal artery. It is normal in appearance (uniformly hypoechoic) and shape with no evidence of a mass effect.

HOSPITAL NAME

Fallston Veterinary
Clinic

The right adrenal gland is normal in size measuring 0.74 cm at the cranial pole and 0.52 cm at the caudal pole. It is observed in its normal position between the cranial aspect of the right kidney and the caudal vena cava. It is normal in appearance (uniformly hypoechoic) and shape with no evidence of a mass effect.

REFERRING VET

Dr. Harvey

Spleen

The spleen is subjectively normal in size, echotexture is homogenous, and the splenic capsule is smooth with no irregularities. The blood flow through the hilus and splenic parenchyma appears normal. No focal parenchymal abnormalities are visualized. The spleen measures 2.51 cm width.

INVOICE

16250

Liver

The liver is subjectively large in size, and echogenicity with smooth peripheral margins. The parenchyma is heterogenous in echotexture with subtle, indistinct focal mottling. The visible portions of the vasculature and biliary tract appear normal. No focal nodules or cystic lesions are observed

The gall bladder lumen is moderately distended. The wall of the gall bladder is not thickened and has a smooth mucosal surface. There is a moderate amount of non-organized echogenic debris. The cystic and common bile ducts are normal/not visible.

Gastrointestinal

The stomach contains minimal luminal contents. It measures at a normal thickness of 0.21 cm with some variability due to the presence of rugal folds. The distinction of the gastric wall layers is adequate and there is no impression of reduced peristaltic activity. No masses or focal lesions were observed.

The visualized areas of duodenum, jejunum and ileum have a relatively uniform diameter with minimal fluid distension. Wall thickness is normal. Bowel loops follow a curvilinear path with distinct wall layering maintaining the typical 1:3 muscularis: mucosa layer ratio. The duodenum measured as normal (0.51 in wall thickness) and the jejunum measured as normal (0.35 cm) Visualized peristalsis appears appropriate. There were no focal lesions consistent with obstruction or a mass effect observed.

Sections of colon are visualized with formed fecal material and gas shadowing distally. There is no observed focal or generalized colon wall thickening or loss of layering.

Pancreas

The pancreas is visible/mildly mottled in the right limb compared to the surrounding isoechoic mesentery. There is no evidence of nodules or cystic lesions. There is no evidence of regional mesenteric inflammation or fluid.

Free Abdomen

Evaluation of the peritoneal cavity did not reveal any evidence of effusion, or subjective lymphadenomegaly. The omentum is of normal uniform echogenicity. An iliac lymph node is visualized measuring 0.42 cm.

ULTRASONOGRAPHIC FINDINGS

- Pancreatic changes consistent with mild pancreatic remodeling.
- Heterogeneous liver- The diffuse hepatic changes are non-specific and could be consistent with vacuolar hepatopathy, nodular hyperplasia, inflammatory/immune-mediated disease, infiltrative neoplasia (less likely) or other hepatopathy.
- Moderate gallbladder debris- The significance of the aggregated gallbladder debris is unclear. This could represent an early mucocele, cholestasis, or may be secondary to fasting but seems unlikely to be causing a current issue. Recommend continued monitoring.

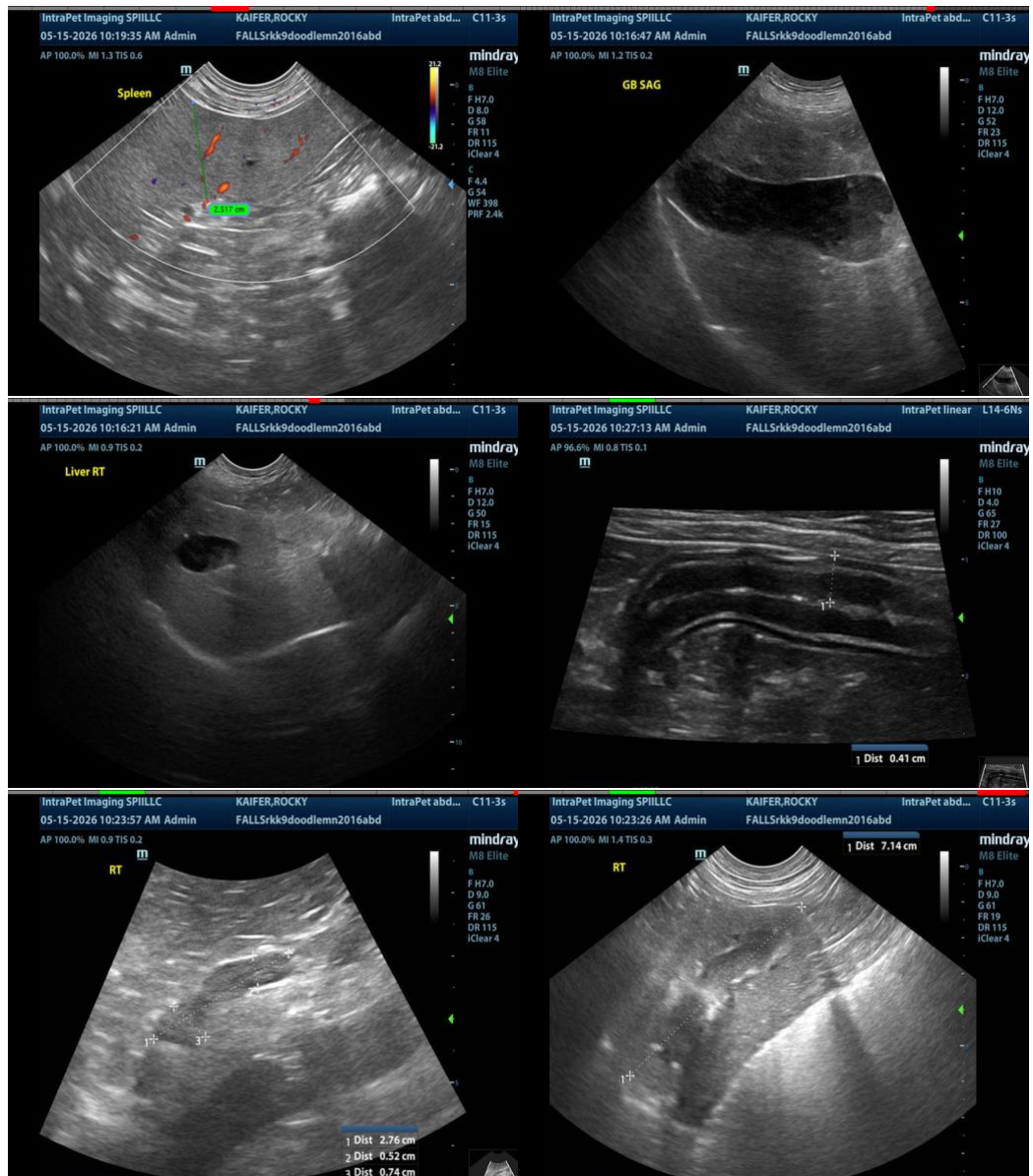
INTERPRETATION OF THE FINDINGS & FURTHER RECOMMENDATIONS

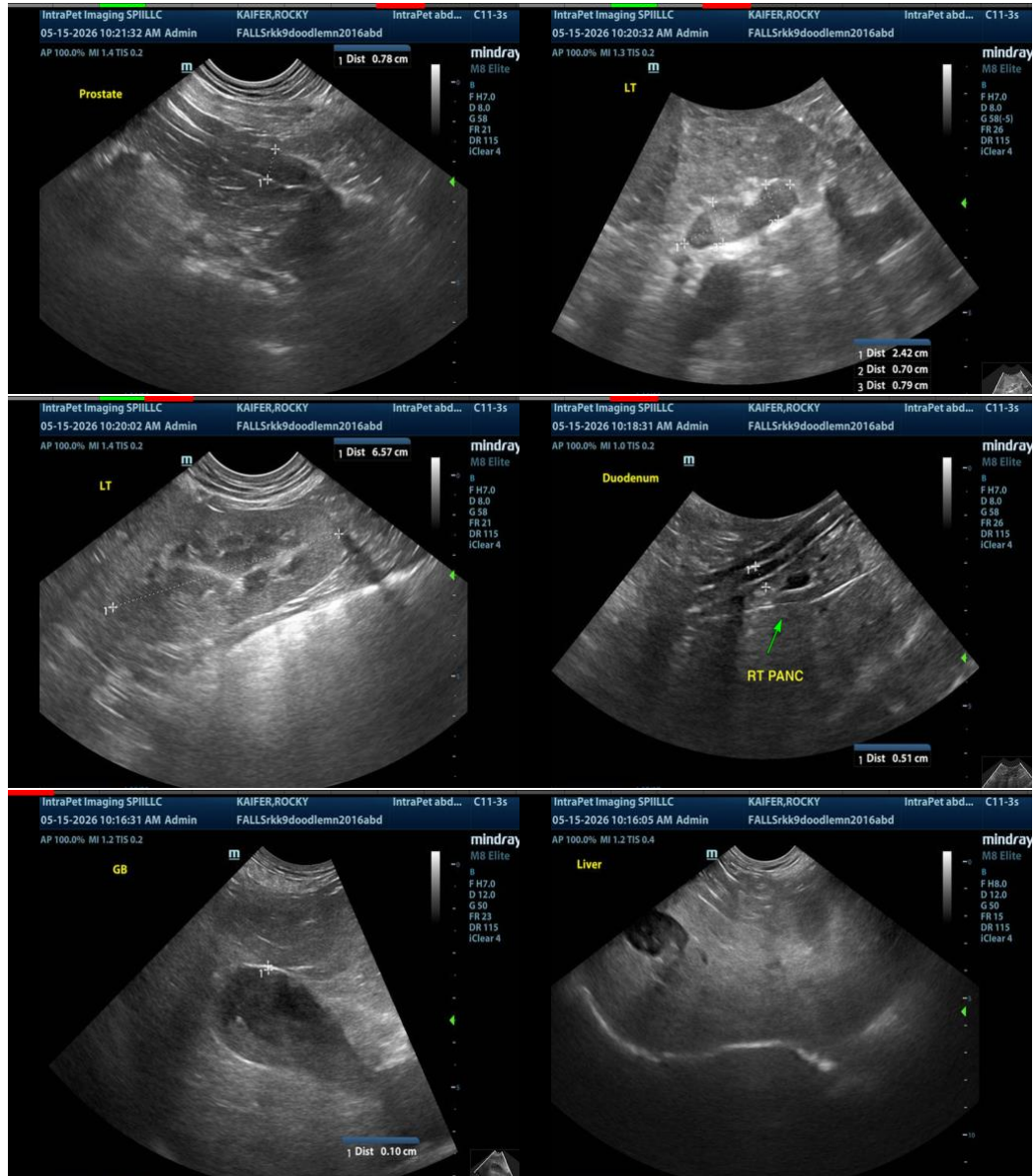
No significant focal lesions are visually associated with the liver. The parenchyma appears diffusely heterogeneous. Given the elevation in ALP, a vacuolar hepatopathy would be most likely, although other

hepatopathies are possible. If further evaluation is desired (particularly for anesthesia), consider pre- and postprandial bile acids to assess liver function and a fine needle aspirate the liver.

There's moderate amount of gallbladder debris, but no evidence of wall thickening or significant inflammation at this time. Options would include continued monitoring or initiating Ursodiol therapy.

Recommend continued monitoring of the liver, particularly if ALP levels continue to progress.





The information and recommendations provided are based on the images presented by the referring veterinarian/sonographer. No evaluation can be communicated regarding pathology that was not visible in the image/video clips provided.

Thank you for this referral. If the clinical or image interpretation does not parallel your findings or if I can be of any further assistance, please contact me.

Kathleen Sennello DVM, MS, Diplomate ACVIM (Small animal Internal Medicine)

info@sonopath.com

