



PATIENT

Zen Weiner

SPECIES

Canine

BREED

Yorkie x

SEX

Neutered Male

AGE

12 Years

WEIGHT

5.8 kg

INTERPRETED BY

Kathleen Sennello DVM,
 MS, Diplomate ACVIM
 (Small Animal Internal
 Medicine)

IMAGING PERFORMED BY

Amanda Stewart

HOSPITAL NAME

Preston Animal Clinic

REFERRING VET

Dr. Coghlan

INVOICE

75148

DATE

5/14/26

PRESENTING CLINICAL SIGNS

Routine wellness testing shows a very increased cPL, this has been noted in the past to be elevated but not this high. Zen currently is not exhibiting any clinical signs. Current Medications: no. What does the pancreas look like?

ULTRASONOGRAPHIC EXAMINATION OF THE ABDOMEN

Urinary System

The urinary bladder is moderately distended with anechoic urine. The Bladder wall, trigone, ureteral papillae and visible urethra (to a depth of 2cm) appear normal with no evidence of wall thickening, mucosal irregularities, masses or cystic calculi.

The prostate is normal in size (0.78 cm) and shape for this neutered male dog. The parenchyma is homogenous and the external margins are smooth. The prostatic urethra appears normal with no evidence of irregularity, invasion, mass effect or calculi.

The left kidney has a normal shape and size (3.77 cm). Overall echogenicity is normal with adequate corticomedullary distinction and a typical 1:3 cortex:medulla ratio. There is no evidence of focal perinephric inflammation or effusion. There is no evidence of pyelectasia, nephroliths, infarcts or hydroureter. Renal vasculature is normal.

The right kidney has a normal shape and size (3.53 cm). Overall echogenicity is normal with adequate corticomedullary distinction and a typical 1:3 cortex:medulla ratio. There is no evidence of focal perinephric inflammation or effusion. There is no evidence of pyelectasia, nephroliths, infarcts or hydroureter. Renal vasculature is normal.

Adrenal Glands

The left adrenal gland is normal in size measuring 0.47 cm at the cranial pole and 0.49 cm at the caudal pole. It is observed in its normal position cranial to the left renal artery. It is normal in appearance (uniformly hypoechoic) and shape with no evidence of a mass effect.

The right adrenal gland is normal in size measuring 0.75 cm at the cranial pole and 0.43 cm at the caudal pole. It is observed in its normal position between the cranial aspect of the right kidney and the caudal vena cava. It is normal in appearance (uniformly hypoechoic) and shape with no evidence of a mass effect.

Spleen

The spleen is subjectively normal in size (1.28 cm), echotexture is homogenous, and the splenic capsule is smooth with no irregularities. The blood flow through the hilus and splenic parenchyma appears normal. No focal parenchymal abnormalities are visualized.

Liver

The liver is subjectively normal in size, and echogenicity with smooth peripheral margins. The parenchyma is homogenous echotexture. The visible portions of the vasculature and biliary tract appear normal. No focal nodules or cystic lesions are observed.



PATIENT

Zen Weiner

The gall bladder lumen is moderately distended. The wall of the gall bladder is not thickened and has a smooth mucosal surface. There is a moderate amount of non-organized echogenic debris. The cystic and common bile ducts are normal/not visible.

SPECIES

Canine

Gastrointestinal

The stomach contains moderate fluid and shadowing ingesta. It measures at a normal thickness of <0.7cm with some variability due to the presence of rugal folds. The distinction of the gastric wall layers is adequate and there is no impression of reduced peristaltic activity. No masses or focal lesions were observed.

BREED

Yorkie x

The visualized areas of duodenum, jejunum and ileum have a relatively uniform diameter with minimal to moderate fluid and gas distension. Wall thickness is normal. Bowel loops follow a curvilinear path with distinct wall layering maintaining the typical 1:3 muscularis:mucosa layer ratio. Duodenum wall measures 0.33 cm. Jejunum wall measures 0.31 cm. Visualized peristalsis appears appropriate. There were no focal lesions consistent with obstruction or a mass effect observed.

SEX

Neutered Male

Sections of colon are visualized with formed fecal material and gas shadowing distally. There is no observed focal or generalized colon wall thickening or loss of layering.

AGE

12 Years

Pancreas

The pancreas is normal and isoechoic to surrounding mesentery. There is no evidence of nodules or cystic lesions. There is no evidence of regional mesenteric inflammation or fluid.

WEIGHT

5.8 kg

INTERPRETED BY

Kathleen Sennello DVM,
 MS, Diplomate ACVIM
 (Small Animal Internal
 Medicine)

Free Abdomen

Evaluation of the peritoneal cavity did not reveal any evidence of effusion, or subjective lymphadenomegaly. The Medial iliac nodes appear normal and there was no evidence of a caudal aortic thrombus at the bifurcation. The omentum is of normal uniform echogenicity.

IMAGING PERFORMED BY

Amanda Stewart

ULTRASONOGRAPHIC FINDINGS

- Moderate gallbladder debris – The significance of the aggregated gallbladder debris is unclear. This could represent an early mucocele, cholestasis, or may be secondary to fasting but seems unlikely to be causing a current issue. Recommend continued monitoring.
- Fluid, gas and shadowing ingesta visualized within the stomach and some sections of small intestine – Findings are most consistent with a post-prandial patient. If the patient was adequately fasted, consider the possibility of gastric ileus or an unseen focal gastrointestinal lesion.

HOSPITAL NAME

Preston Animal Clinic

INTERPRETATION OF THE FINDINGS & FURTHER RECOMMENDATIONS

The changes observed on today's scan are mild. The visualized areas of pancreas appear normal. A small unseen focal area of inflammation cannot be definitively ruled out, but there is no indication of inflammation in the region. There is fluid and shadowing ingesta visualized within the stomach, and the bowel in the caudal abdomen appears somewhat "gassy". I suspect these changes are most consistent with a non-fasted patient, although mild gastric ileus or similar cannot be ruled out.

REFERRING VET

Dr. Coghlan

INVOICE

75148

DATE

5/14/26



PATIENT

Zen Weiner

SPECIES

Canine

BREED

Yorkie x

SEX

Neutered Male

AGE

12 Years

WEIGHT

5.8 kg

INTERPRETED BY

Kathleen Sennello DVM,
 MS, Diplomate ACVIM
 (Small Animal Internal
 Medicine)

**IMAGING
 PERFORMED BY**

Amanda Stewart

HOSPITAL NAME

Preston Animal Clinic

REFERRING VET

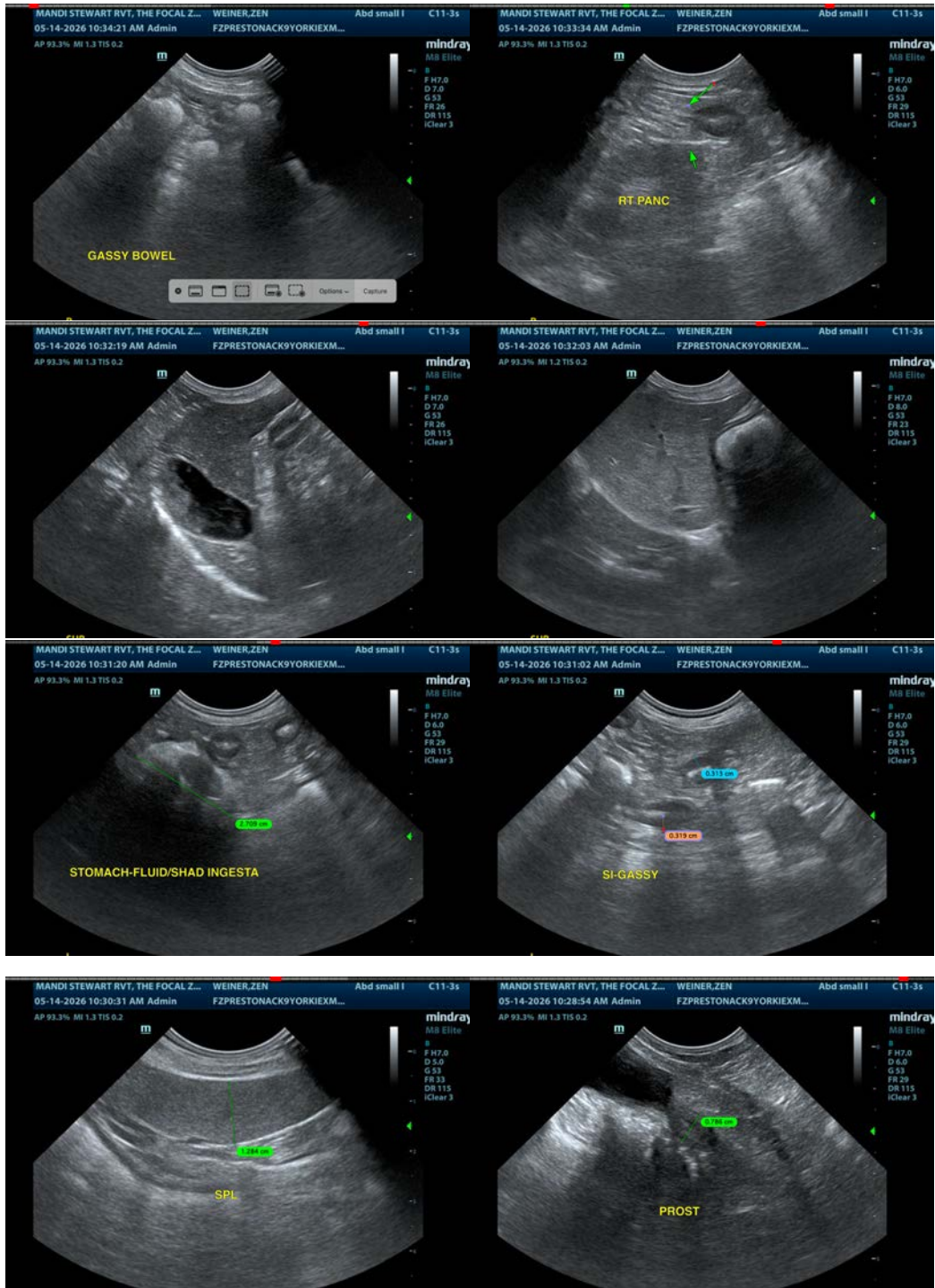
Dr. Coghlan

INVOICE

75148

DATE

5/14/26





PATIENT

Zen Weiner

SPECIES

Canine

BREED

Yorkie x

SEX

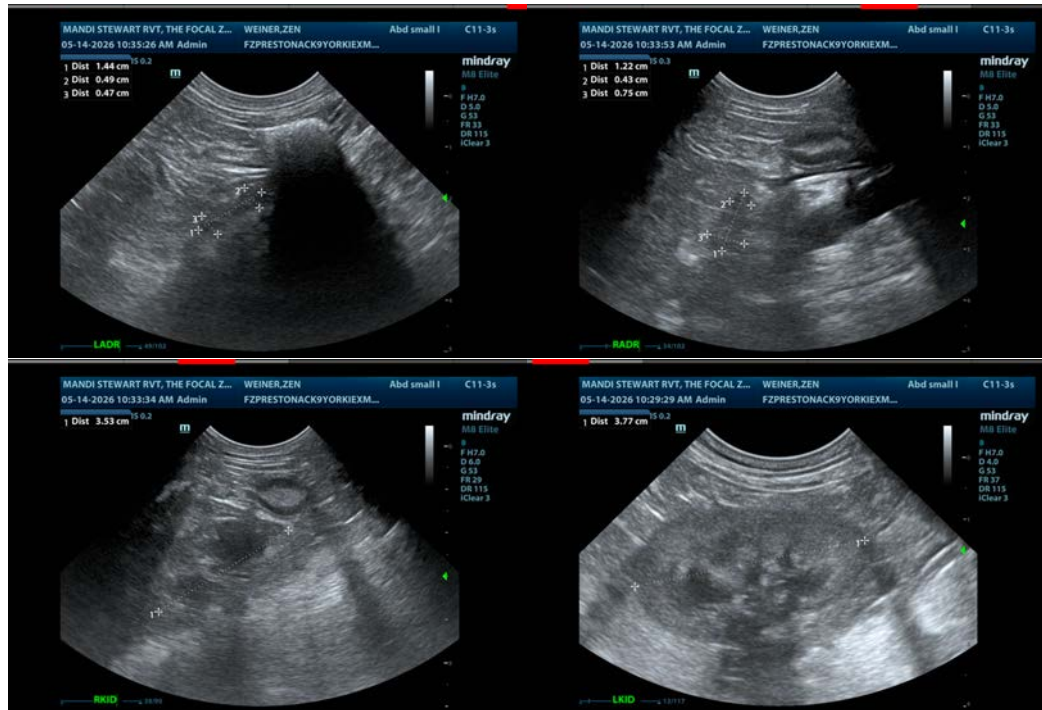
Neutered Male

AGE

12 Years

WEIGHT

5.8 kg



INTERPRETED BY

Kathleen Sennello DVM,
 MS, Diplomate ACVIM
 (Small Animal Internal
 Medicine)

The information and recommendations provided are based on the images presented by the referring veterinarian/sonographer. No evaluation can be communicated regarding pathology that was not visible in the image/video clips provided.

Thank you for this referral. If the clinical or image interpretation does not parallel your findings or if I can be of any further assistance please contact me.

IMAGING PERFORMED BY

Amanda Stewart

Kathleen Sennello DVM,MS, Diplomate ACVIM (Small animal Internal Medicine)
 info@sonopath.com

HOSPITAL NAME

Preston Animal Clinic

REFERRING VET

Dr. Coghlan

INVOICE

75148

DATE

5/14/26