

PATIENT

Brigh Coleman

SPECIES

Canine

BREED

Bull Mastiff

SEX

Spayed Female

AGE

8 Years

WEIGHT

96 lbs

INTERPRETED BY

Kathleen Sennello DVM,
MS, Diplomate ACVIM
(Small Animal Internal
Medicine)

**IMAGING
PERFORMED BY**

Loetitia Saint-Jacques,
LVT

HOSPITAL NAME

South Reno Vet

REFERRING VET

Dr. Schmitt

INVOICE

75180

DATE

5/14/26

PRESENTING CLINICAL SIGNS

No sedation-Hx: Owner reports no vomiting diarrhea coughing sneezing. Eating and drinking normal. Mobility and activity normal. Patient has slowed down. Scratching a lot. Owner has noticed some discharge from underneath the skin and gums do not look normal. Owner's have experienced some of their own health problems and been unable to go to veterinary dermatologist but will schedule. 15lb weight loss

Abnormal PE/Chem/CBC/UA Results: Chemistry SDMA15.3. Decreased protein 7.8and albumin2.3. Increased globulin 5.5 AMY 1291, PrePSL 22 CBC: Hemogram values lower end of normal. Heartworm test antigen: No Antigen Detected Fecal: All undetected Urinalysis: Increased protein and bilirubin along with white blood cells. A: Urine is concentrated but SD MA slightly increased with normal BUN and creatinine. Hypoproteinemia and hypoalbuminemia along with hyperglobulinemia. DDX: Possibly do to blood loss but cannot rule out reflexive from chronic infection versus inflammation causing hyperglobulinemia. Also possible neoplasia. RADS-A: Cranial abdominal mass DDX: Splenic versus hepatic versus other. Also severe arthritis of right carpal joint.

ULTRASONOGRAPHIC EXAMINATION OF THE ABDOMEN

Urinary System

The urinary bladder is moderately distended with anechoic urine. The Bladder wall, trigone, ureteral papillae and visible urethra (to a depth of 2cm) appear normal with no evidence of wall thickening, mucosal irregularities, masses or cystic calculi. There is a cystic structure visualized cranial to the urinary bladder measuring 2.48 cm in diameter. A direct association with the apex of the urinary bladder is not clearly visualized but cannot be ruled out.

The left kidney has a normal shape and size (6.65 cm). Overall echogenicity is normal with adequate corticomedullary distinction and a typical 1:3 cortex:medulla ratio. There is no evidence of focal perinephric inflammation or effusion. There is no evidence of pyelectasia, nephroliths, infarcts or hydroureter. Renal vasculature is normal.

The right kidney has a normal shape and size (7.11 cm). Overall echogenicity is normal with adequate corticomedullary distinction and a typical 1:3 cortex:medulla ratio. There is no evidence of focal perinephric inflammation or effusion. There is no evidence of pyelectasia, nephroliths, infarcts or hydroureter. Renal vasculature is normal.

Adrenal Glands

The left adrenal gland is normal in size measuring 0.78 cm at the cranial pole and 0.74 cm at the caudal pole. It is observed in its normal position cranial to the left renal artery. It is normal in appearance (uniformly hypoechoic) and shape with no evidence of a mass effect.

The right adrenal gland is normal in size measuring 0.74 cm at the cranial pole and 0.66 cm at the caudal pole. It is observed in its normal position between the cranial aspect of the right kidney and the caudal vena cava. It is normal in appearance (uniformly hypoechoic) and shape with no evidence of a mass effect.



PATIENT

Brigh Coleman

SPECIES

Canine

BREED

Bull Mastiff

SEX

Spayed Female

AGE

8 Years

WEIGHT

96 lbs

INTERPRETED BY

Kathleen Sennello DVM,
MS, Diplomate ACVIM
(Small Animal Internal
Medicine)

**IMAGING
PERFORMED BY**

Loetitia Saint-Jacques,
LVT

HOSPITAL NAME

South Reno Vet

REFERRING VET

Dr. Schmitt

INVOICE

75180

DATE

5/14/26

Spleen

The spleen is subjectively normal in size (2.06 cm), echotexture is homogenous, and the splenic capsule is smooth with no irregularities. The blood flow through the hilus and splenic parenchyma appears normal. No focal parenchymal abnormalities are visualized.

Liver

The liver is subjectively normal in size, and echogenicity with smooth peripheral margins. The parenchyma is homogenous echotexture. The visible portions of the vasculature and biliary tract appear normal. No focal nodules or cystic lesions are observed.

The gall bladder lumen is moderately distended. The wall of the gall bladder is not thickened and has a smooth mucosal surface. Luminal contents are mild and likely incidental at this time. The cystic and common bile ducts are normal/not visible.

Gastrointestinal

The stomach contains mild fluid/gas. It measures at a normal thickness of 0.65 cm with some variability due to the presence of rugal folds. The distinction of the gastric wall layers is adequate and there is no impression of reduced peristaltic activity.

The visualized areas of duodenum, jejunum and ileum have a relatively uniform diameter with minimal fluid distension. Wall thickness is normal. Bowel loops follow a curvilinear path with distinct wall layering maintaining the typical 1:3 muscularis:mucosa layer ratio. Duodenum wall measures 0.44 cm. Jejunum wall measures 0.37 cm. Visualized peristalsis appears appropriate. There were no focal lesions consistent with obstruction or a mass effect observed.

Sections of colon are visualized with formed fecal material and gas shadowing distally. There is no observed focal or generalized colon wall thickening or loss of layering.

Pancreas

The area of the pancreas is normal and isoechoic to surrounding mesentery. There is no evidence of nodules or cystic lesions. There is no evidence of regional mesenteric inflammation or fluid.

Free Abdomen

Evaluation of the peritoneal cavity did not reveal any evidence of effusion, or subjective lymphadenomegaly. The Medial iliac nodes appear normal and there was no evidence of a caudal aortic thrombus at the bifurcation. The omentum is of normal uniform echogenicity.

ULTRASONOGRAPHIC FINDINGS

- Cystic structure visualized cranial to the urinary bladder – The location and appearance of this lesion could be concerning for a urachal defect. A direct association with the urinary bladder is not clearly visualized.

INTERPRETATION OF THE FINDINGS & FURTHER RECOMMENDATIONS

There is a cystic lesion visualized near the apex of the urinary bladder. The location and nature of the structure could be consistent with a urachal defect such as urachal cyst, diverticulum, etc. A contrast study would likely be necessary to further evaluate (contrast cystogram or contrast CT scan). These can be incidental in some individuals or be associated with chronic urinary tract infections, etc. An alternate



PATIENT

Brigh Coleman

SPECIES

Canine

BREED

Bull Mastiff

SEX

Spayed Female

AGE

8 Years

WEIGHT

96 lbs

INTERPRETED BY

Kathleen Sennello DVM,
MS, Diplomate ACVIM
(Small Animal Internal
Medicine)

IMAGING PERFORMED BY

Loetitia Saint-Jacques,
LVT

HOSPITAL NAME

South Reno Vet

REFERRING VET

Dr. Schmitt

INVOICE

75180

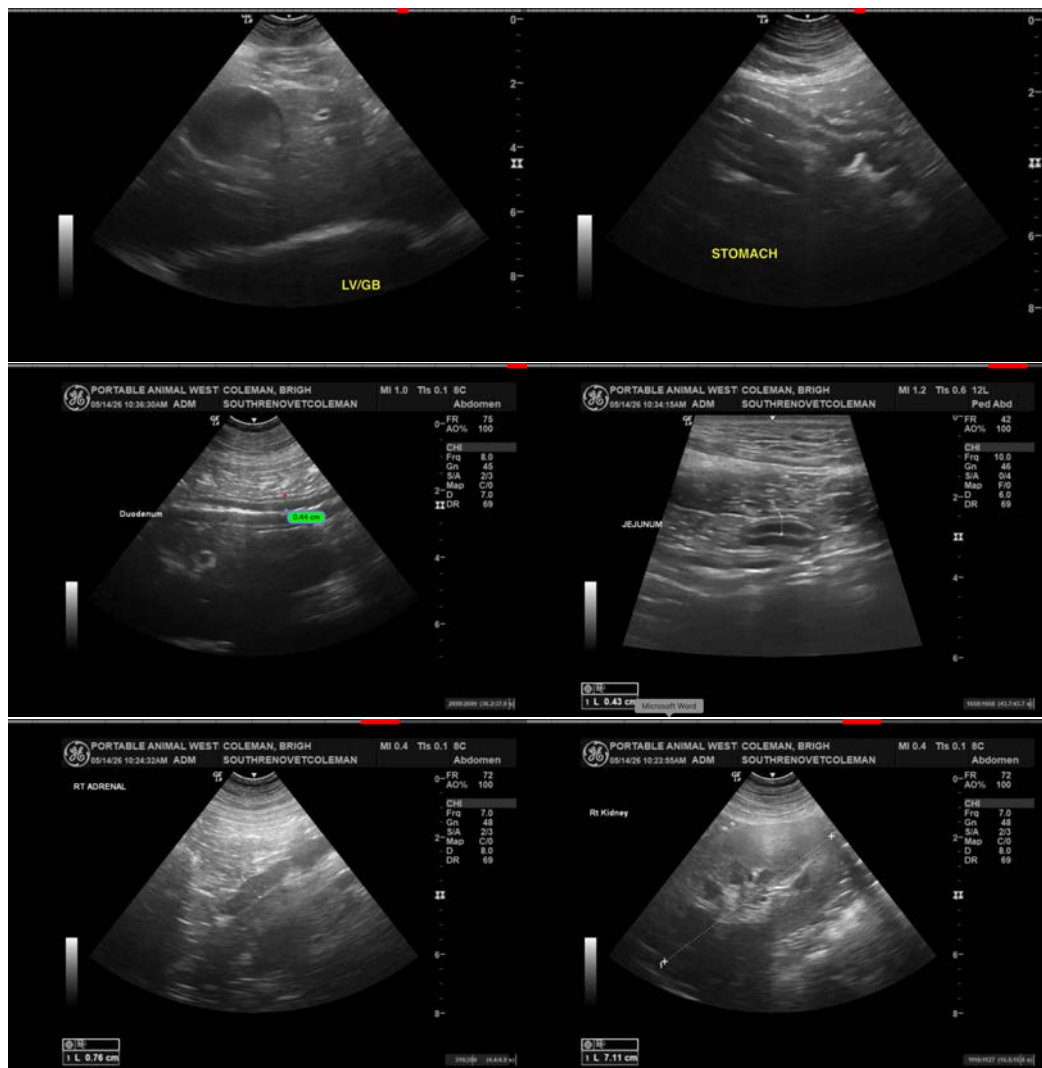
DATE

5/14/26

differential would be an omental cyst or similar.

An obvious lesion responsible for the hypoalbuminemia is not clearly visualized on today's exam. Given the normal globulin levels, a gastrointestinal lesion is less likely. If not already done recommend a urine protein to creatinine ratio, looking for excessive proteinuria. Additionally, you could consider pre- and post-prandial bile acids to assess for possible liver dysfunction. Additionally, further evaluation for chronic inflammatory or infectious disease could be considered such as ehrlichiosis, etc.

Recommend three view thoracic radiographs to evaluate for possible concurrent thoracic disease/involvement (disregard if this has already been done).





PATIENT

Brigh Coleman

SPECIES

Canine

BREED

Bull Mastiff

SEX

Spayed Female

AGE

8 Years

WEIGHT

96 lbs

INTERPRETED BY

Kathleen Sennello DVM,
MS, Diplomate ACVIM
(Small Animal Internal
Medicine)

IMAGING PERFORMED BY

Loetitia Saint-Jacques,
LVT

HOSPITAL NAME

South Reno Vet

REFERRING VET

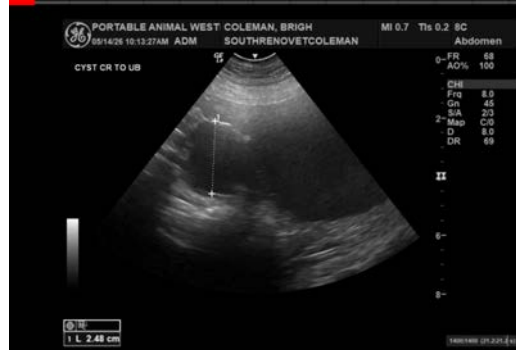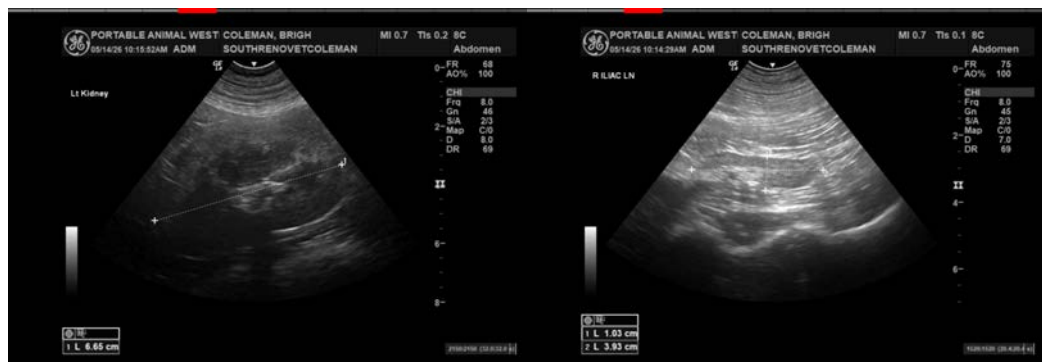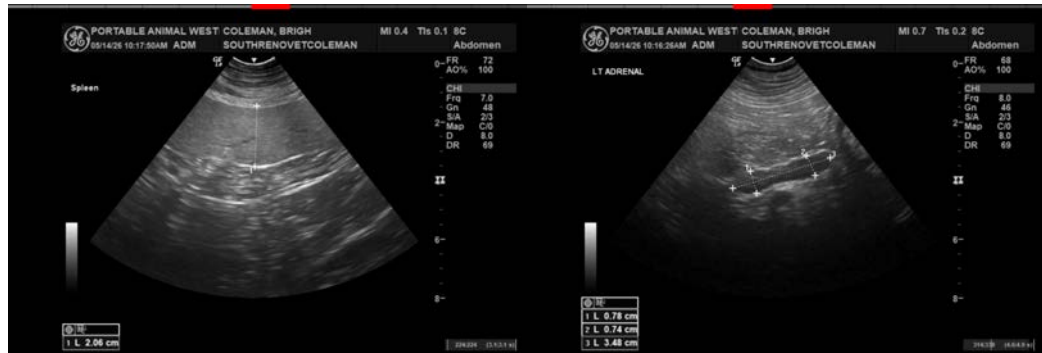
Dr. Schmitt

INVOICE

75180

DATE

5/14/26



The information and recommendations provided are based on the images presented by the referring veterinarian/sonographer. No evaluation can be communicated regarding pathology that was not visible in the image/video clips provided.

Thank you for this referral. If the clinical or image interpretation does not parallel your findings or if I can be of any further assistance please contact me.

Kathleen Sennello DVM,MS, Diplomate ACVIM (Small animal Internal Medicine)

info@sonopath.com