

**PATIENT**

Alex Tokarz

PRESENTING CLINICAL SIGNS

Patient presents for weight loss and lethargy. Mid abdominal mass effect is palpable.

SPECIES

Feline

ULTRASONOGRAPHIC EXAMINATION OF THE ABDOMEN**Urinary System****BREED**

DSH

The urinary bladder is moderately distended with a moderate amount of primarily suspended echogenic debris present. The Bladder wall, trigone, ureteral papillae and visible urethra (to a depth of 2cm) appear normal with no evidence of wall thickening, mucosal irregularities, masses or calculi. Echogenic debris of this type can be associated with small crystals, cellular debris and proteinaceous debris.

SEX

Neutered Male

The left kidney has a normal shape and size (4.42 cm). Overall echogenicity is slightly hyperechoic with poor corticomedullary distinction and a typical 1:3 cortex:medulla ratio. There is no evidence of focal perinephric inflammation or effusion. There is no evidence of pyelectasia, nephroliths, infarcts or hydroureter. Renal vasculature is normal.

AGE

8 Years

The right kidney has a normal shape and size (3.32 cm). Overall echogenicity is slightly hyperechoic with poor corticomedullary distinction and a typical 1:3 cortex:medulla ratio. There is no evidence of focal perinephric inflammation or effusion. There is no evidence of pyelectasia, nephroliths, infarcts or hydroureter. Renal vasculature is normal.

WEIGHT

10 lbs

Adrenal Glands**INTERPRETED BY**

Kathleen Sennello DVM,
MS, Diplomate ACVIM
(Small Animal Internal
Medicine)

The left adrenal gland is normal in size measuring 0.51 cm at the caudal pole. It is observed in its normal position cranial to the left renal artery. It is normal in appearance (uniformly hypoechoic) and shape with no evidence of a mass effect.

The region of the right adrenal (between right cranial kidney and vena cava) is unremarkable, but the adrenal is not distinctly visualized. No evidence of a mass effect is visualized.

IMAGING PERFORMED BY

Julia Bakker, DVM

Spleen

The spleen is subjectively normal in size (0.91 cm), echotexture is homogenous, and the splenic capsule is smooth with no irregularities. The blood flow through the hilus and splenic parenchyma appears normal. No focal parenchymal abnormalities are visualized.

HOSPITAL NAME

Orange Blossom
Veterinary Imaging

Liver

The liver is subjectively normal in size with smooth peripheral margins. The parenchyma is hyperechoic and homogenous in echotexture. The visible portions of the vasculature and biliary tract appear normal. No focal nodules or cystic lesions are observed.

REFERRING VET

Stephen Romero, DVM

The gall bladder lumen is moderately distended. The wall of the gall bladder is not thickened and has a smooth mucosal surface. There is a moderate amount of non-organized echogenic debris. The cystic and common bile ducts are normal/not visible.

INVOICE

75171

Gastrointestinal**DATE**

5/14/26

The stomach contains minimal luminal contents. It measures at a normal thickness of <0.36cm with some variability due to the presence of rugal folds. The distinction of the gastric wall layers is adequate and there is no impression of reduced peristaltic activity. No masses or focal lesions were observed.



PATIENT

Alex Tokarz

SPECIES

Feline

BREED

DSH

SEX

Neutered Male

AGE

8 Years

WEIGHT

10 lbs

INTERPRETED BY

Kathleen Sennello DVM,
MS, Diplomate ACVIM
(Small Animal Internal
Medicine)

IMAGING PERFORMED BY

Julia Bakker, DVM

HOSPITAL NAME

Orange Blossom
Veterinary Imaging

REFERRING VET

Stephen Romero, DVM

INVOICE

75171

DATE

5/14/26

The visualized areas of duodenum, jejunum and ileum have a uniform diameter with minimal fluid distension. Wall thickness is increased. Bowel loops follow a typical curvilinear path. Some areas have reduced detail of wall layering. Jejunum wall measures 0.23 cm. Visualized peristalsis appears appropriate. There is a large area of focal bowel thickening with complete loss of layering creating a mass effect in this region, extending for at least 6.0 cm. Bowel wall measures 1.2 cm in thickness. A small intestinal lesion is suspected but cannot be confirmed.

The ileocecal junction was visualized and exhibited normal intact wall layering and is subjectively of normal thickness. Sections of colon are visualized with formed fecal material and gas shadowing distally. There is no observed focal or generalized colon wall thickening or loss of layering.

Pancreas

The pancreas is prominent, hypoechoic and mottled in the left limb. There is no evidence of nodules or cystic lesions. There is no evidence of regional mesenteric inflammation or fluid.

Free Abdomen

There is a moderate amount of free abdominal fluid. No lymphadenopathy. The omentum is diffusely hyperechoic.

Other

Pleural effusion is suspected.

PRIMARY FINDINGS

- Large, focal bowel mass effect with complete loss of layering – Findings are concerning for neoplastic infiltration (round cell neoplasia, carcinoma, other). Other differentials are possible.
- Pancreatic changes most consistent with chronic pancreatic remodeling +/- chronic pancreatitis.
- Moderate volume free abdominal fluid and suspect pleural effusion. Recommend fluid analysis and cytology.

SECONDARY FINDINGS

- Suspended echogenic debris in the urinary bladder – The echogenic debris in the bladder lumen could be consistent with cells, crystals, and/or mucus.
- Age related changes visualized associated with both kidneys.
- Moderate gallbladder debris – The significance of the aggregated gallbladder debris is unclear. This could represent an early mucocele, cholestasis, or may be secondary to fasting. Incidental gall bladder debris is less common in cats.

INTERPRETATION OF THE FINDINGS & FURTHER RECOMMENDATIONS

There is a large mid abdominal bowel mass effect featuring complete loss of layering. The lesion is extensive. Recommend a fine needle aspirate of the bowel wall. If a cytologic diagnosis can be obtained, recommend consultation with a veterinary oncologist. Based on the size and extent of bowel involved, surgical options may be limited. If resection is considered, consider a contrast CT scan to better



PATIENT

Alex Tokarz

SPECIES

Feline

BREED

DSH

SEX

Neutered Male

AGE

8 Years

WEIGHT

10 lbs

INTERPRETED BY

Kathleen Sennello DVM,
MS, Diplomate ACVIM
(Small Animal Internal
Medicine)

**IMAGING
PERFORMED BY**

Julia Bakker, DVM

HOSPITAL NAME

Orange Blossom
Veterinary Imaging

REFERRING VET

Stephen Romero, DVM

INVOICE

75171

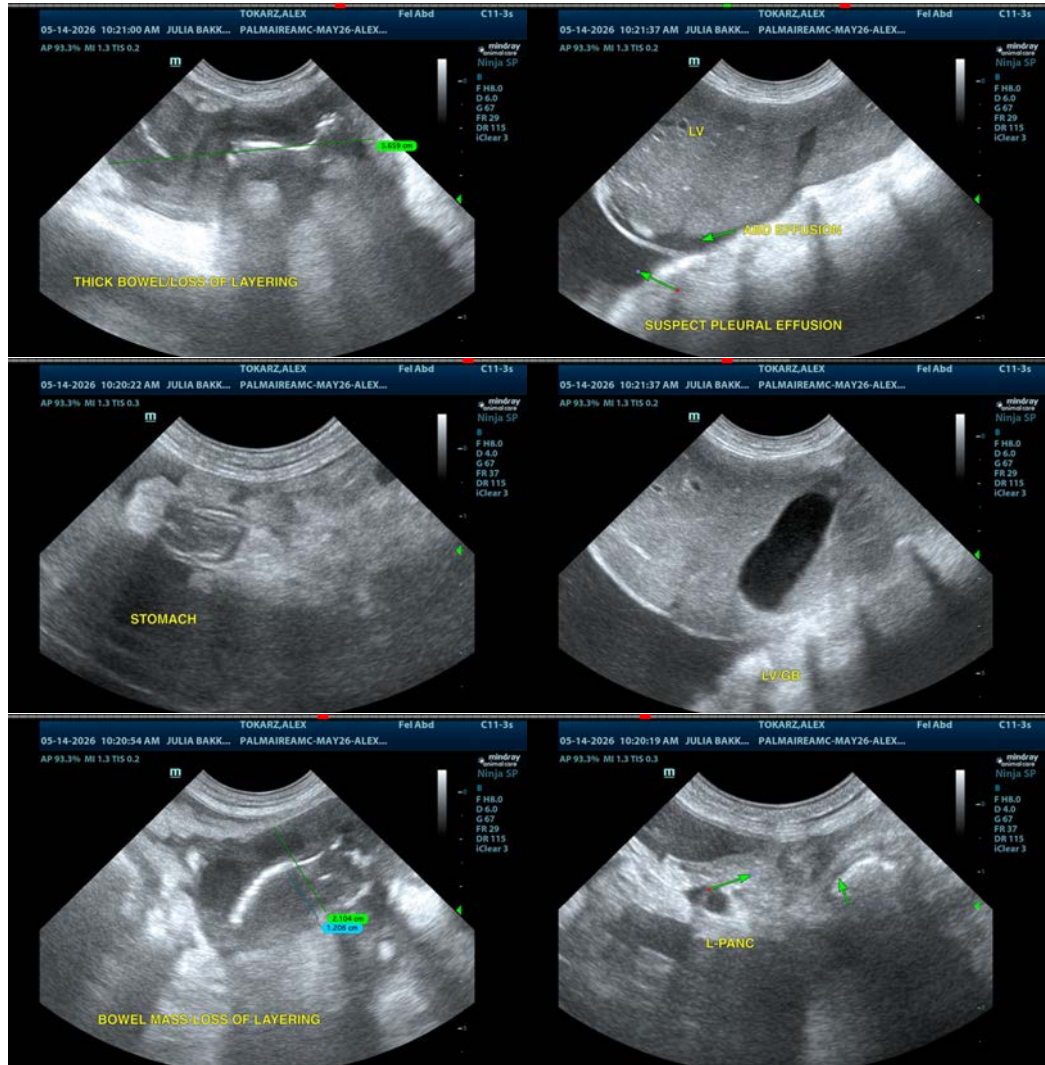
DATE

5/14/26

determine the extent of the lesion and if there are additional areas of bowel involved.

The liver is subjectively hyperechoic. The significance is uncertain. Correlate with current lab work. A fine needle aspirate could be considered if there is concern for possible neoplastic infiltration (provided coagulation parameter are normal).

Recommend 3-view thoracic radiographs.





PATIENT

Alex Tokarz

SPECIES

Feline

BREED

DSH

SEX

Neutered Male

AGE

8 Years

WEIGHT

10 lbs

INTERPRETED BY

Kathleen Sennello DVM,
MS, Diplomate ACVIM
(Small Animal Internal
Medicine)

**IMAGING
PERFORMED BY**

Julia Bakker, DVM

HOSPITAL NAME

Orange Blossom
Veterinary Imaging

REFERRING VET

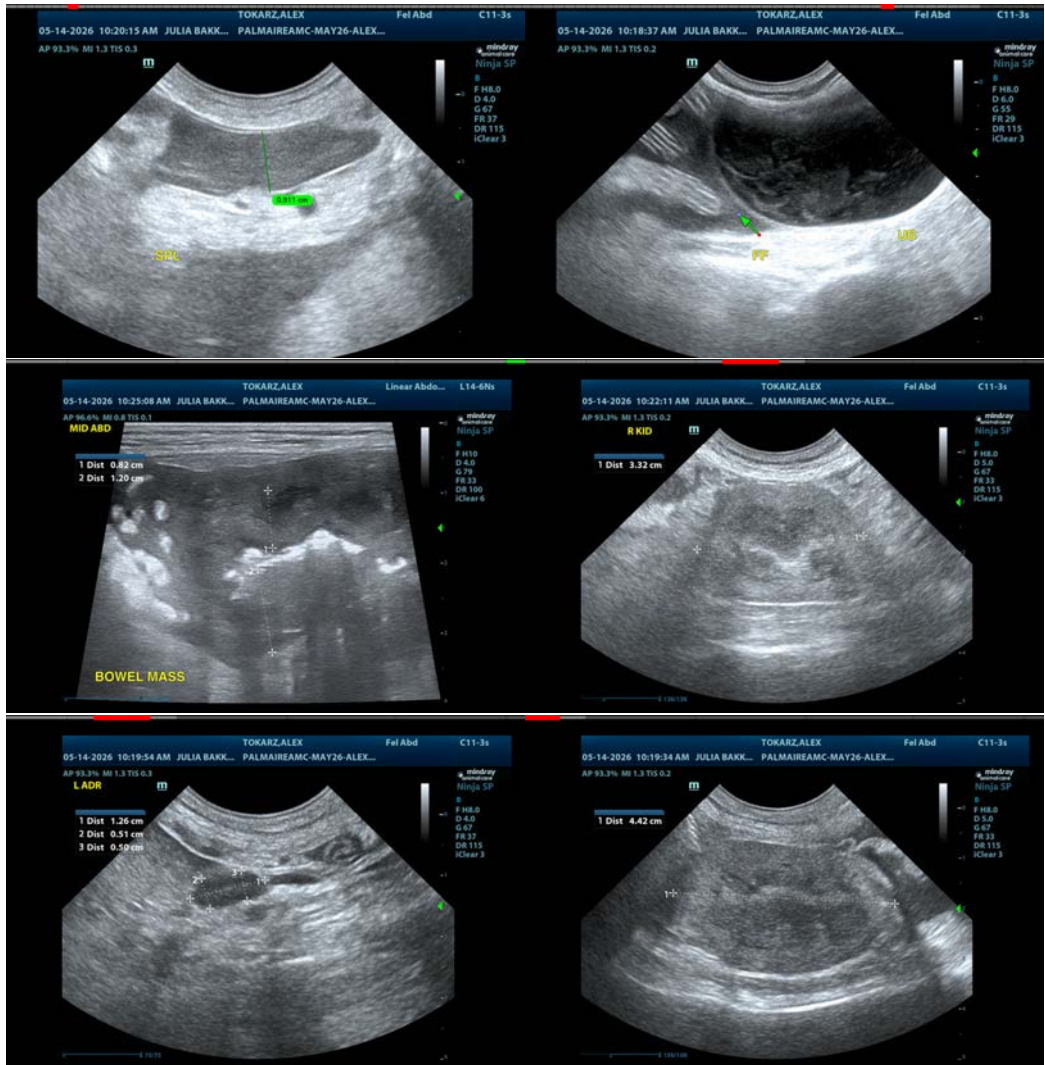
Stephen Romero, DVM

INVOICE

75171

DATE

5/14/26



The information and recommendations provided are based on the images presented by the referring veterinarian/sonographer. No evaluation can be communicated regarding pathology that was not visible in the image/video clips provided.

Thank you for this referral. If the clinical or image interpretation does not parallel your findings or if I can be of any further assistance please contact me.

Kathleen Sennello DVM,MS, Diplomate ACVIM (Small animal Internal Medicine)

info@sonopath.com