



PATIENT

Abby Geshinsky

SPECIES

Canine

BREED

Maltese Poodle

SEX

Spayed Female

AGE

7

WEIGHT

18.4 lbs

INTERPRETED BY

Kathleen Sennello DVM,
MS, Diplomate ACVIM
(Small Animal Internal
Medicine)

IMAGING PERFORMED BY

Dr. Shane Stafford

HOSPITAL NAME

West Newton Animal
Clinic

REFERRING VET

Dr. Shane Stafford

INVOICE

75145

DATE

5/14/26

PRESENTING CLINICAL SIGNS

Patient was present for a recheck abdominal ultrasound after having one done on 8/14/2025 to look at the cause of liver values that was elevated. Report showed moderate biliary sludge without gallbladder wall thickening or biliary duct dilation. Liver values were done recently and are attached have improved but shows the bilirubin was increased slightly

Abnormal PE/Chem/CBC/UA Results: PE remains static please see attached labs.

ULTRASONOGRAPHIC EXAMINATION OF THE ABDOMEN

Urinary System

The urinary bladder is moderately distended with anechoic urine. The Bladder wall, trigone, ureteral papillae and visible urethra (to a depth of 2cm) appear normal with no evidence of wall thickening, mucosal irregularities, masses or cystic calculi.

The left kidney has a normal shape and size (3.7 cm). Overall echogenicity is normal with adequate corticomedullary distinction and a typical 1:3 cortex:medulla ratio. There is no evidence of focal perinephric inflammation or effusion. There is no evidence of pyelectasia, nephroliths, infarcts or hydroureter. Renal vasculature is normal.

The right kidney has a normal shape and size (4.2 cm). Overall echogenicity is normal with adequate corticomedullary distinction and a typical 1:3 cortex:medulla ratio. There is no evidence of focal perinephric inflammation or effusion. There is no evidence of pyelectasia, nephroliths, infarcts or hydroureter. Renal vasculature is normal.

Adrenal Glands

The left adrenal gland is normal in size measuring 0.38 cm at the cranial pole and 0.40 cm at the caudal pole. It is observed in its normal position cranial to the left renal artery. It is normal in appearance (uniformly hypoechoic) and shape with no evidence of a mass effect.

The caudal pole of the right adrenal gland is normal in size at 0.48 cm. It is observed in its normal position between the cranial aspect of the right kidney and the caudal vena cava. It is normal in appearance (uniformly hypoechoic) and shape with no evidence of a mass effect. The cranial pole is not clearly visualized.

Spleen

The spleen is subjectively normal in size (1.62 cm), echotexture is homogenous, and the splenic capsule is smooth with no irregularities. The blood flow through the hilus and splenic parenchyma appears normal. No focal parenchymal abnormalities are visualized.

Liver

The liver is subjectively normal in size, and echogenicity with smooth peripheral margins. The parenchyma is homogenous echotexture. The visible portions of the vasculature and biliary tract appear normal. No focal nodules or cystic lesions are observed.



PATIENT

Abby Geshinsky

The gall bladder lumen is moderately distended. The wall of the gall bladder is not thickened and has a smooth mucosal surface. There is a moderate amount of non-organized echogenic debris. The cystic and common bile ducts are normal/not visible.

SPECIES

Canine

Gastrointestinal

The stomach contains minimal luminal contents. It measures at a normal thickness of <0.7cm with some variability due to the presence of rugal folds. The distinction of the gastric wall layers is adequate and there is no impression of reduced peristaltic activity. No masses or focal lesions were observed.

BREED

Maltese Poodle

The visualized areas of duodenum, jejunum and ileum have a relatively uniform diameter with minimal fluid distension. Wall thickness is normal. Bowel loops follow a curvilinear path with distinct wall layering maintaining the typical 1:3 muscularis:mucosa layer ratio. Duodenum wall measures 0.45 cm. Jejunum wall measures 0.29 cm. Visualized peristalsis appears appropriate. There were no focal lesions consistent with obstruction or a mass effect observed.

SEX

Spayed Female

AGE

7

Sections of colon are visualized with formed fecal material and gas shadowing distally. There is no observed focal or generalized colon wall thickening or loss of layering.

Pancreas

WEIGHT

18.4 lbs

The pancreas is normal and isoechoic to surrounding mesentery. There is no evidence of nodules or cystic lesions. There is no evidence of regional mesenteric inflammation or fluid.

Free Abdomen

INTERPRETED BY

Kathleen Sennello DVM,
MS, Diplomate ACVIM
(Small Animal Internal
Medicine)

Evaluation of the peritoneal cavity did not reveal any evidence of effusion, or subjective lymphadenomegaly. The Medial iliac nodes appear normal and there was no evidence of a caudal aortic thrombus at the bifurcation. The omentum is of normal uniform echogenicity.

ULTRASONOGRAPHIC FINDINGS

- Moderate gallbladder debris – The significance of the aggregated gallbladder debris is unclear. This could represent an early mucocele, cholestasis, or may be secondary to fasting but seems unlikely to be causing a current issue. Recommend continued monitoring.

IMAGING PERFORMED BY

Dr. Shane Stafford

INTERPRETATION OF THE FINDINGS & FURTHER RECOMMENDATIONS

HOSPITAL NAME

West Newton Animal
Clinic

Today's scan is very similar to the previously described scan from 8/14/25. There is a moderate amount of debris in the gallbladder with no evidence of wall thickening or surrounding inflammation. Options include continued monitoring +/- chronic Ursodiol therapy.

REFERRING VET

Dr. Shane Stafford

The elevation in bilirubin reported is likely secondary to the hemolysis and lipemia noted associated with the sample. Consider reevaluation of a fasted non-hemolyzed sample for evaluation.

INVOICE

75145

DATE

5/14/26



PATIENT

Abby Geshinsky

SPECIES

Canine

BREED

Maltese Poodle

SEX

Spayed Female

AGE

7

WEIGHT

18.4 lbs

INTERPRETED BY

Kathleen Sennello DVM,
MS, Diplomate ACVIM
(Small Animal Internal
Medicine)

**IMAGING
PERFORMED BY**

Dr. Shane Stafford

HOSPITAL NAME

West Newton Animal
Clinic

REFERRING VET

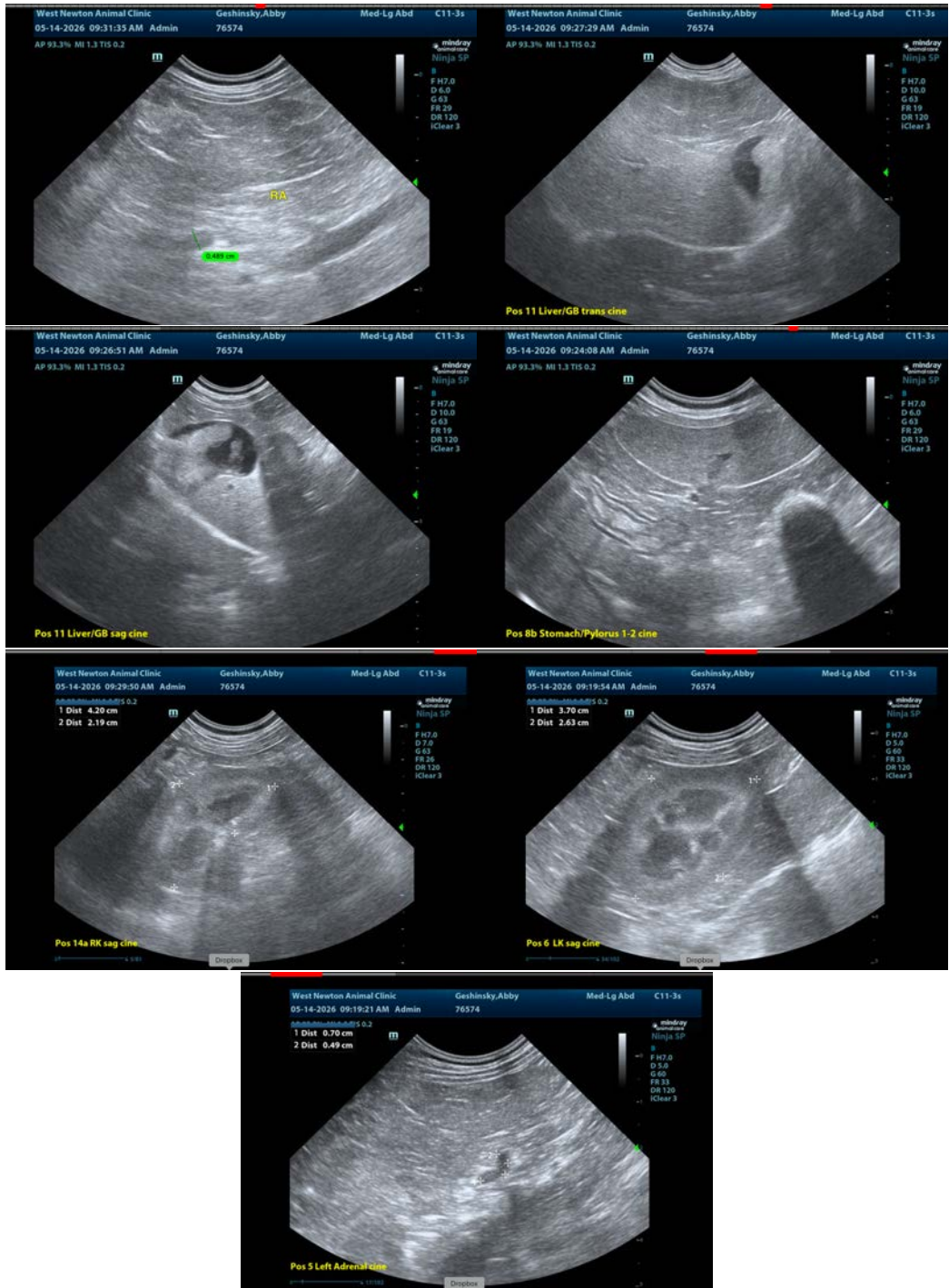
Dr. Shane Stafford

INVOICE

75145

DATE

5/14/26





PATIENT

Abby Geshinsky

SPECIES

Canine

BREED

Maltese Poodle

SEX

Spayed Female

AGE

7

WEIGHT

18.4 lbs

INTERPRETED BY

Kathleen Sennello DVM,
MS, Diplomate ACVIM
(Small Animal Internal
Medicine)

IMAGING PERFORMED BY

Dr. Shane Stafford

HOSPITAL NAME

West Newton Animal
Clinic

REFERRING VET

Dr. Shane Stafford

INVOICE

75145

DATE

5/14/26

The information and recommendations provided are based on the images presented by the referring veterinarian/sonographer. No evaluation can be communicated regarding pathology that was not visible in the image/video clips provided.

Thank you for this referral. If the clinical or image interpretation does not parallel your findings or if I can be of any further assistance please contact me.

Kathleen Sennello DVM,MS, Diplomate ACVIM (Small animal Internal Medicine)

info@sonopath.com