



**PATIENT PRESENTING CLINICAL SIGNS**

**Tia Burton** History: Species: Canine Gender(altered?) S Age: 4Y Weight in #: 10.1 Breed: Terrier mix History: 2-3 month history of hyporexia. Everything else clinically is WNL. No c/s/v/d. Energy is great Physical exam findings: no significant findings on PE Abnormal CBC values: lymphocytes are higher than the other white blood cells, but they are not elevated Abnormal Chemistry Values: mild increase in CK. All else WNL Abnormal UA Values: well concentrated. Mild proteinuria Radiograph Findings(email radiographs if available): No significant findings on abdominal radiographs Reason for Ultrasound: Evaluating for cause of hyporexia.

**ULTRASONOGRAPHIC EXAMINATION OF THE ABDOMEN**

Terrier Mix

**Urinary System**

**SEX**

Spayed Female

The urinary bladder is moderately distended with anechoic urine. The Bladder wall, trigone, ureteral papillae and visible urethra (to a depth of 2.0 cm) appear normal with no evidence of wall thickening, mucosal irregularities, masses or cystic calculi.

**AGE**

4 Years

The left kidney has a normal shape and size (3.42 cm). Overall echogenicity is normal with adequate corticomedullary distinction and a typical 1:3 cortex:medulla ratio. There is no evidence of perinephric inflammation or effusion. The cortex appears somewhat hyperechoic, creating the impression of corticomedullary rim sign. There is no evidence of pyelectasia, nephroliths, infarcts or hydroureter. Renal vasculature is normal.

**WEIGHT**

10 Pounds

The right kidney has a normal shape and size (3.74 cm). Overall echogenicity is normal with adequate corticomedullary distinction and a typical 1:3 cortex:medulla ratio. There is no evidence of perinephric inflammation or effusion. The cortex appears somewhat hyperechoic, creating the impression of corticomedullary rim sign. There is no evidence of pyelectasia, nephroliths, infarcts or hydroureter. Renal vasculature is normal.

**INTERPRETED BY**

Kathleen Sennello DVM,  
MS, Diplomate ACVIM  
(Small Animal Internal  
Medicine)

**Adrenal Glands**

The left adrenal gland is normal in size measuring 0.41 cm at the caudal pole. It is observed in its normal position cranial to the left renal artery. It is normal in appearance (uniformly hypoechoic) and shape with no evidence of a mass effect.

**IMAGING PERFORMED BY**

Loetitia Saint-Jacques, RVT

The right adrenal gland is normal in size measuring 0.34 cm at the caudal pole. It is observed in its normal position between the cranial aspect of the right kidney and the caudal vena cava. It is normal in appearance (uniformly hypoechoic) and shape with no evidence of a mass effect.

**HOSPITAL NAME**

Alpine AH

**Spleen**

The spleen is subjectively normal in size, echotexture is homogenous, and the splenic capsule is smooth with no irregularities. The blood flow through the hilus and splenic parenchyma appears normal. No focal parenchymal abnormalities are visualized.

**REFERRING VET**

Dr. Lindsay Sjoin

**Liver**

**INVOICE**

15156

The liver is subjectively normal in size, and echogenicity with smooth peripheral margins. The parenchyma is homogenous echotexture. The visible portions of the vasculature and biliary tract appear normal. No focal nodules or cystic lesions are observed. The gall bladder lumen is moderately

**DATE**

5/13/22



**PATIENT** distended. The wall of the gall bladder is not thickened and has a smooth mucosal surface. Luminal contents are primarily anechoic. The cystic and common bile ducts are normal/not visible.

Tia Burton

***Gastrointestinal***

**SPECIES** The stomach is moderately dilated with fluid and irregular shadowing material most consistent with normal ingesta and gas. It measures at a normal thickness of <0.7cm with some variability due to the presence of rugal folds. The distinction of the gastric wall layering is adequate and there is no impression of reduced peristaltic activity. No masses or focal lesions were observed.

Canine

**BREED**

The visualized areas of duodenum, jejunum and ileum have a relatively uniform diameter with minimal fluid distension. Wall thickness is normal. Bowel loops follow a curvilinear path with distinct wall layering maintaining the typical 1:3 muscularis: mucosa layer ratio. The duodenum measured as normal (0.41 cm in wall thickness) and the jejunum measured as normal (0.3 cm, 0.32 cm) Visualized peristalsis appears appropriate. There were no focal lesions consistent with obstruction or a mass effect observed.

Terrier Mix

**SEX**

The ileocecal junction was visualized and exhibited normal intact wall layering and is subjectively of normal thickness. Sections of colon are visualized with formed fecal material and gas shadowing distally. There is no observed focal or generalized colon wall thickening or loss of layering.

Spayed Female

**AGE**

***Pancreas***

4 Years

The pancreas is prominent and mottled compared to the surrounding isoechoic mesentery. There is no evidence of nodules or cystic lesions. There is no evidence of regional mesenteric inflammation or fluid.

**WEIGHT**

10 Pounds

***Free Abdomen***

**INTERPRETED BY**

Evaluation of the peritoneal cavity did not reveal any evidence of effusion, or subjective lymphadenomegaly. The Medial iliac nodes appear normal and there was no evidence of a caudal aortic thrombus at the bifurcation. The omentum is of normal uniform echogenicity.

Kathleen Sennello DVM,  
MS, Diplomate ACVIM  
(Small Animal Internal  
Medicine)

**ULTRASONOGRAPHIC FINDINGS**

**IMAGING PERFORMED BY**

- Corticomedullary rim sign visualized in both kidneys. Clinical significance uncertain, can be seen in normal patients and in cases of ethylene glycol toxicity, FIP, chronic interstitial nephritis, and leptospirosis.
- Mildly prominent mottled pancreas. The pancreatic changes are most consistent with age-related parenchymal remodeling, potentially secondary to a prior inflammatory episode, early fibrosis or chronic pancreatitis.
- Mild fluid distention of the stomach. This could be consistent with a recent drink, delayed gastric emptying or a partial outflow tract obstruction (none observed).

Loetitia Saint-Jacques, RVT

**HOSPITAL NAME**

Alpine AH

**REFERRING VET**

Dr. Lindsay Sjloun

**INTERPRETATION OF THE FINDINGS & FURTHER RECOMMENDATIONS**

**INVOICE**

Today's scan is largely normal for this 4-year-old dog. The changes observed are likely incidental and represent normal variation. An obvious cause for the hyporexia noted is not observed. In these situations, I will often do a liver function test, just to confirm there is no elevation of bile acids

15156

**DATE**

5/13/22



**PATIENT**

Tia Burton

indicating liver dysfunction and I'll often run a GI panel (to Texas A & M) to look for evidence of chronic pancreatitis or evidence of small intestinal disease. Otherwise, I'll often switch to a novel protein/hydrolyzed protein hydrolyzed protein prescription canned diet, which is hopefully more palatable and continue to monitor symptoms and lab work findings, in hopes more specific symptoms develop if the patient is not feeling better.

**SPECIES**

Canine

**BREED**

Terrier Mix

**SEX**

Spayed Female

**AGE**

4 Years

**WEIGHT**

10 Pounds

**INTERPRETED BY**

Kathleen Sennello DVM,  
MS, Diplomate ACVIM  
(Small Animal Internal  
Medicine)

**IMAGING PERFORMED BY**

Loetitia Saint-Jacques, RVT

**HOSPITAL NAME**

Alpine AH

**REFERRING VET**

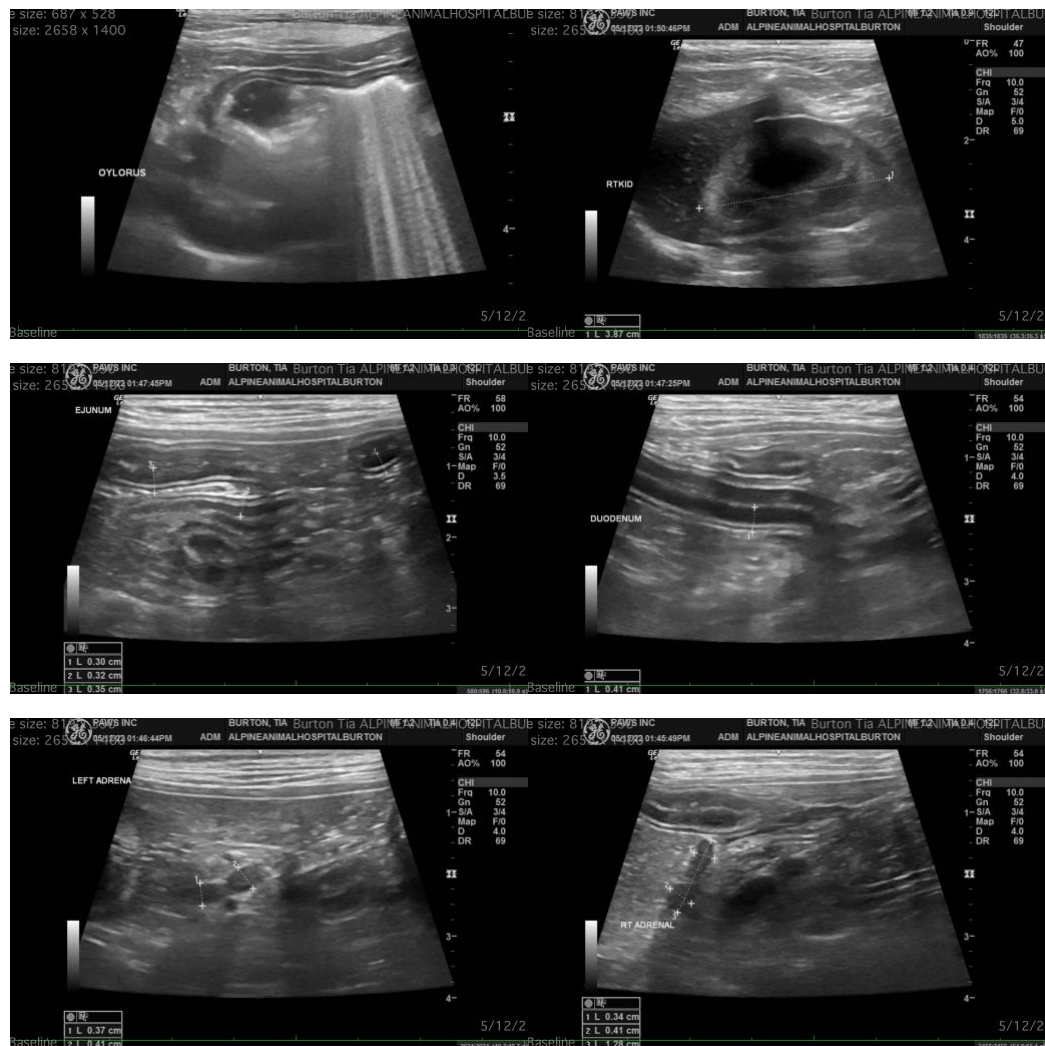
Dr. Lindsay Sjlain

**INVOICE**

15156

**DATE**

5/13/22





**PATIENT**

Tia Burton

**SPECIES**

Canine

**BREED**

Terrier Mix

**SEX**

Spayed Female

**AGE**

4 Years

**WEIGHT**

10 Pounds

**INTERPRETED BY**

Kathleen Sennello DVM,  
MS, Diplomate ACVIM  
(Small Animal Internal  
Medicine)

**IMAGING PERFORMED BY**

Loetitia Saint-Jacques, RVT

**HOSPITAL NAME**

Alpine AH

**REFERRING VET**

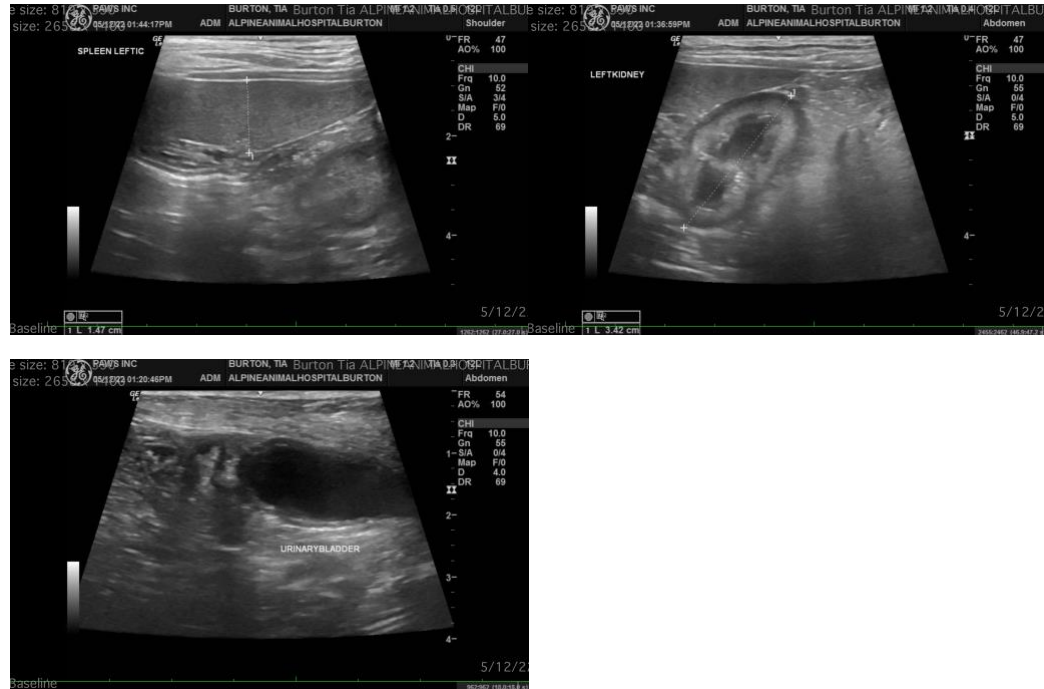
Dr. Lindsay Sjloin

**INVOICE**

15156

**DATE**

5/13/22



The information and recommendations provided are based on the images presented by the referring veterinarian. No evaluation can be communicated regarding pathology that was not visible in the image/video clips provided.

Thank you for this referral. If the clinical or image interpretation does not parallel your findings or if I can be of any further assistance please contact me.

Kathleen Sennello DVM, MS, Diplomate ACVIM (Small animal Internal Medicine)  
kathleen.sennello@sonopath.com