



PATIENT PRESENTING CLINICAL SIGNS

Gracie Yant History: Gracie has a history of mild azotemia and his vaccine current. As expected she is a spayed female age unknown but probably at least 10 and last week we had on her was 7 1/2 pounds. She had minor dehydration, and a fluidy feel to her abdomen and it felt like there was some fluid. You have the most recent bloodwork and urinalysis. She was on supportive care including sub Q fluids and mirtazapine

SPECIES

Feline

Abnormal PE/Chem/CBC/UA Results: LABS attached

BREED

ULTRASONOGRAPHIC EXAMINATION OF THE ABDOMEN

Domestic Shorthair

Urinary System

SEX

Spayed Female

The urinary bladder is moderately distended with anechoic urine. The Bladder wall, trigone, ureteral papillae and visible urethra (to a depth of 2cm) appear normal with no evidence of wall thickening, mucosal irregularities, masses or cystic calculi.

AGE

7 Years

The left kidney has a normal shape and size (3.85 cm). Overall echogenicity is slightly hyperechoic with poor corticomedullary distinction and a typical 1:3 cortex:medulla ratio. There is no evidence of perinephric inflammation or effusion. There is no evidence of pyelectasia, nephroliths, infarcts or hydroureter. Renal vasculature is normal.

WEIGHT

7.5 Pounds

The right kidney has a normal shape and size (3.4 cm). Overall echogenicity is normal with adequate corticomedullary distinction and a typical 1:3 cortex:medulla ratio. There is no evidence of perinephric inflammation or effusion. There is no evidence of pyelectasia, nephroliths, infarcts or hydroureter. Renal vasculature is normal.

Adrenal Glands

INTERPRETED BY

Kathleen Sennello DVM,
MS, Diplomate ACVIM
(Small Animal Internal
Medicine)

The left adrenal gland is normal in size measuring 0.45 cm at the caudal pole. It is observed in its normal position cranial to the left renal artery. It is normal in appearance (uniformly hypoechoic) and shape with no evidence of a mass effect.

The region of the right adrenal (between right cranial kidney and vena cava) is unremarkable, but the adrenal is not distinctly visualized. No evidence of a mass effect.

IMAGING PERFORMED BY

Loetitia Saint-Jacques, RVT

Spleen

HOSPITAL NAME

Dr. Stacie Baker

The spleen is subjectively normal in size, echotexture is homogenous, and the splenic capsule is smooth with no irregularities. The blood flow through the hilus and splenic parenchyma appears normal. No focal parenchymal abnormalities are visualized.

Liver

REFERRING VET

Dr. Stacie Baker

The liver is subjectively normal in size, and echogenicity with smooth peripheral margins. The parenchyma is homogenous echotexture. The visible portions of the vasculature and biliary tract appear normal. No focal nodules or cystic lesions are observed.

INVOICE

15154

The gall bladder lumen is moderately distended. The wall of the gall bladder is not thickened and has a smooth mucosal surface. Luminal contents are primarily anechoic. The bile duct is visualized and somewhat prominent, measuring 0.36 cm.

Gastrointestinal

DATE

5/13/22



PATIENT The stomach contains minimal luminal contents. It measures at a normal thickness of <0.7cm with some variability due to the presence of rugal folds. The distinction of the gastric wall layers is adequate and there is no impression of reduced peristaltic activity. No masses or focal lesions were observed.

Gracie Yant

SPECIES The visualized areas of duodenum, jejunum and ileum have a uniform diameter with minimal fluid distension. Wall thickness is normal to slightly increased. Bowel loops follow a typical curvilinear path with distinct wall layering, but some areas display a prominent muscularis layer which does not display the typical 1:3 muscularis:mucosa layer ratio. The jejunum measured 0.29, 0.3 cm in diameter.

Feline

BREED Visualized peristalsis appears appropriate. There were no focal lesions consistent with obstruction or a mass effect observed.

Domestic Shorthair

SEX The ileocecal junction was visualized and exhibited normal intact wall layering and is subjectively of normal thickness. Sections of colon are visualized with formed fecal material and gas shadowing distally. There is no observed focal or generalized colon wall thickening or loss of layering.

Spayed Female

Pancreas

AGE The (pancreas/region of the pancreas) is normal and isoechoic to surrounding mesentery. There is no evidence of nodules or cystic lesions. There is no evidence of regional mesenteric inflammation or fluid.

7 Years

Free Abdomen

WEIGHT There is no free fluid. There is a significant diffuse mesenteric lymphadenopathy with mesenteric lymph nodes measuring 0.76 cm, 0.51 cm, 0.34 cm in diameter and the omentum is generally of increased echogenicity, particularly around the prominent lymph nodes.

7.5 Pounds

INTERPRETED BY

Kathleen Sennello DVM,
MS, Diplomate ACVIM
(Small Animal Internal
Medicine)

ULTRASONOGRAPHIC FINDINGS

- Decreased corticomedullary distinction in both kidneys. The bilateral renal findings are consistent with age-related change.
- Diffuse mesenteric lymphadenopathy. The prominent abdominal lymph nodes are most consistent with reactive lymphadenitis or lymphoid hyperplasia. Neoplastic infiltration is considered less likely.
- Subjectively thickened small intestine with prominent muscularis layer. The small intestinal wall changes are most consistent with an inflammatory process (i.e., inflammatory bowel disease) with a low possibility of emerging lymphoma

IMAGING PERFORMED BY

Loetitia Saint-Jacques, RVT

HOSPITAL NAME

Dr. Stacie Baker

INTERPRETATION OF THE FINDINGS & FURTHER RECOMMENDATIONS

REFERRING VET

Dr. Stacie Baker

The lab work submitted with this case indicates a significant hypoalbuminemia. This is most likely secondary to either GI disease, hepatic disease or renal disease. Based on the lack of protein in the urinalysis, a protein-losing nephropathy seems unlikely and the liver appears generally fairly normal. I would strongly suspect a protein-losing enteropathy based on the appearance of the small intestine, then diffuse mesenteric lymphadenopathy. The most common causes for a protein-losing enteropathy include IBD, lymphangiectasia and intestinal neoplasia. Other possibilities exist.

INVOICE

15154

- I recommend pre-and post-prandial bile acids to confirm normal liver function
- I recommend a GI panel (to Texas A & M) for a qualitative fPLI, TLI, cobalamin and folate to

DATE

5/13/22



PATIENT

Gracie Yant

SPECIES

Feline

BREED

Domestic Shorthair

SEX

Spayed Female

AGE

7 Years

WEIGHT

7.5 Pounds

INTERPRETED BY

Kathleen Sennello DVM,
MS, Diplomate ACVIM
(Small Animal Internal
Medicine)

IMAGING PERFORMED BY

Loetitia Saint-Jacques, RVT

HOSPITAL NAME

Dr. Stacie Baker

REFERRING VET

Dr. Stacie Baker

INVOICE

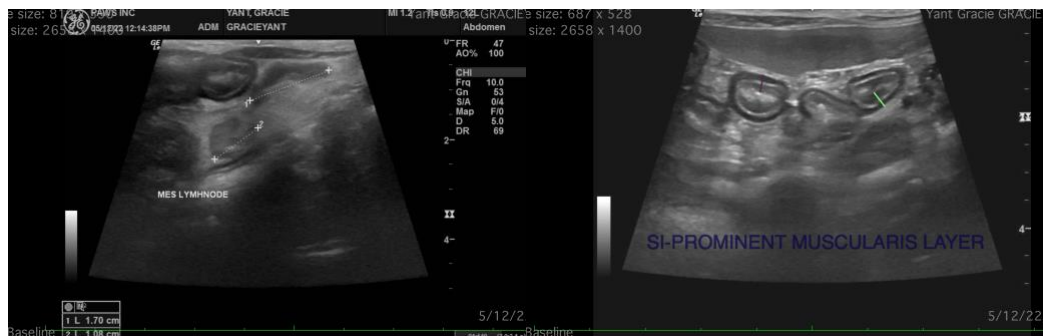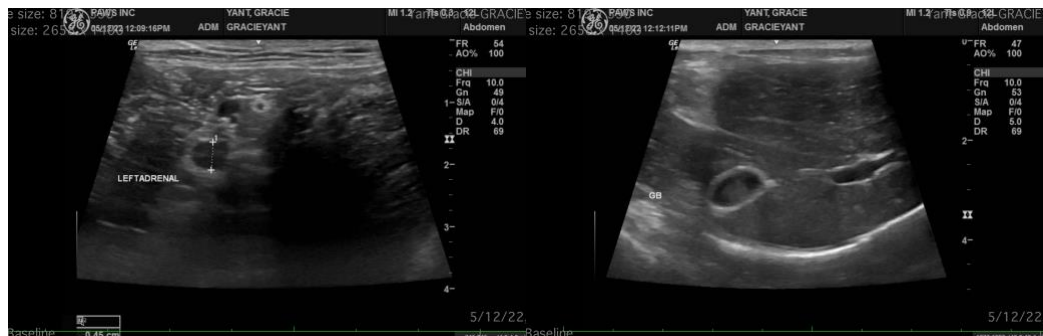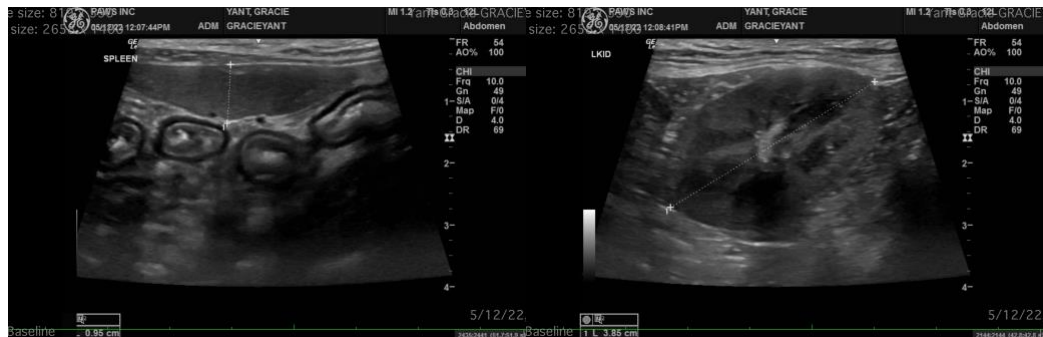15154

DATE

5/13/22

look for additional evidence of small intestinal disease.

- I recommend three-view thoracic radiographs
- Consider a fine needle aspirate of a mesenteric lymph node
- Initiate either a hydrolyzed protein/novel protein prescription diet or an ultra low-fat diet
- I would strongly recommend pursuing upper and lower GI endoscopy to obtain biopsies to determine a diagnosis, which will help to provide a better prognosis and help to better guide treatment protocols.





PATIENT

Gracie Yant

SPECIES

Feline

BREED

Domestic Shorthair

SEX

Spayed Female

AGE

7 Years

WEIGHT

7.5 Pounds

INTERPRETED BY

Kathleen Sennello DVM,
MS, Diplomate ACVIM
(Small Animal Internal
Medicine)

**IMAGING PERFORMED
BY**

Loetitia Saint-Jacques, RVT

HOSPITAL NAME

Dr. Stacie Baker

REFERRING VET

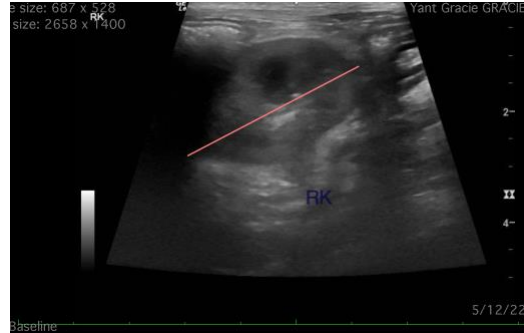
Dr. Stacie Baker

INVOICE

15154

DATE

5/13/22



The information and recommendations provided are based on the images presented by the referring veterinarian. No evaluation can be communicated regarding pathology that was not visible in the image/video clips provided.

Thank you for this referral. If the clinical or image interpretation does not parallel your findings or if I can be of any further assistance please contact me.

Kathleen Sennello DVM,MS, Diplomate ACVIM (Small animal Internal Medicine)
kathleen.sennello@sonopath.com