



## PATIENT

Tutu Kao

## SPECIES

Feline

## BREED

DSH

## SEX

Neutered Male

## AGE

12 Years 9 Months

## WEIGHT

11.7 lbs

## INTERPRETED BY

Kathleen Sennello DVM,  
MS, Diplomate ACVIM  
(Small Animal Internal  
Medicine)

## IMAGING PERFORMED BY

Megan Cassels-  
Conway, DVM

## HOSPITAL NAME

Central Broward  
Animal Hospital

## REFERRING VET

Janeen Lezcano, DVM

## INVOICE

75092

## DATE

5/12/26

## PRESENTING CLINICAL SIGNS

P presented for wellness exam. Prior to that pet was last seen pet in 1/2023. On PE a non-painful large kidney/mass in mid dorsal abdomen was palpated. Per owner p is doing well at home, no concerns. No v/d/s. Eating well, currently on RC satiety. In past p was markedly overweight. O does report for several years p has coughed/hacked on occasion.

Abnormal PE/Chem/CBC/UA Results: CBC: WNL, Chem: BUN: 25, creat: 1.3, choles: 225H, T4: 2.2, UA: SG: 1.049, 2+ prot, hematuria. Chest/Abd rads: Radiographic Conclusions/Recommendations: 1.Mild diffuse bronchial pulmonary pattern. Consider chronic bronchitis vs age-related change. 2.Small mineral opacities projecting over the left renal silhouette consistent with nephrolithiasis. 3.Subjectively small right kidney. Findings are most consistent with chronic renal change (e.g., chronic kidney disease or prior insult). Abdominal ultrasound is recommended to further evaluate renal architecture, confirm suspected nephroliths, and assess for underlying chronic renal disease.

## ULTRASONOGRAPHIC EXAMINATION OF THE ABDOMEN

### Urinary System

The urinary bladder is moderately distended with mildly echogenic urine. The Bladder wall largely appears of normal thickness with a smooth mucosal surface. In the apical ventral region there is some hyperechoic irregularity possibly consistent with adhered debris or abnormal tissue. In the transverse view this measures 0.38 cm x 1.57 cm. In the sagittal view this measures 1.19 cm x 0.75 cm. The region of the trigone, ureteral papillae and proximal urethra appear free of any mass lesions or calculi.

The left kidney is borderline large at 4.86 cm with occasional pinpoint mineralizations noted. Overall echogenicity is slightly hyperechoic with mildly reduced corticomedullary distinction and a typical 1:3 cortex:medulla ratio. There is no evidence of focal perinephric inflammation or effusion. There is no evidence of pyelectasia, infarcts or hydroureter. Renal vasculature is normal.

The right kidney is normal/borderline small (compared to the left kidney), measuring 3.9 cm, with significant pyelectasia at 0.40 cm and numerous small nephroliths. Overall echogenicity is slightly hyperechoic with poor corticomedullary distinction and a typical 1:3 cortex:medulla ratio. There is no evidence of focal perinephric inflammation or effusion. There is no evidence of infarcts. Renal vasculature is normal. The proximal ureter is significantly distended, measuring at 0.71 cm with surrounding reactive mesentery. It is lost to visualization distally.

### Adrenal Glands

The left adrenal gland is normal in size measuring 0.22 cm at the caudal pole. It is observed in its normal position cranial to the left renal artery. It is normal in appearance (uniformly hypoechoic) and shape with no evidence of a mass effect.

The right adrenal gland is normal in size measuring 0.36 cm at the caudal pole. It is observed in its normal position between the cranial aspect of the right kidney and the caudal vena cava. It is normal in appearance (uniformly hypoechoic) and shape with no evidence of a mass effect.



## PATIENT

Tutu Kao

## SPECIES

Feline

## BREED

DSH

## SEX

Neutered Male

## AGE

12 Years 9 Months

## WEIGHT

11.7 lbs

## INTERPRETED BY

Kathleen Sennello DVM,  
MS, Diplomate ACVIM  
(Small Animal Internal  
Medicine)

## IMAGING PERFORMED BY

Megan Cassels-  
Conway, DVM

## HOSPITAL NAME

Central Broward  
Animal Hospital

## REFERRING VET

Janeen Lezcano, DVM

## INVOICE

75092

## DATE

5/12/26

### *Spleen*

The spleen is subjectively normal in size (1.14 cm), echotexture is homogenous, and the splenic capsule is smooth with no irregularities. The blood flow through the hilus and splenic parenchyma appears normal. No focal parenchymal abnormalities are visualized.

### *Liver*

The liver is subjectively normal in size, and echogenicity with smooth peripheral margins. The parenchyma is homogenous echotexture. The visible portions of the vasculature and biliary tract appear normal. No focal nodules or cystic lesions are observed.

The gall bladder lumen is moderately distended. The wall of the gall bladder is not thickened and has a smooth mucosal surface. Luminal contents are mild and likely incidental at this time. The cystic and common bile ducts are normal/not visible.

### *Gastrointestinal*

The stomach contains minimal luminal contents. It measures at a normal thickness of <0.36cm with some variability due to the presence of rugal folds. The distinction of the gastric wall layers is adequate and there is no impression of reduced peristaltic activity. No masses or focal lesions were observed.

The visualized areas of duodenum, jejunum and ileum have a uniform diameter with minimal to mild fluid distension. Wall thickness is normal to slightly increased. Bowel loops follow a typical curvilinear path with distinct wall layering, but some areas display a prominent muscularis layer which does not display the typical 1:3 muscularis:mucosa layer ratio. Duodenum wall measures 0.22 cm. Jejunum wall measures 0.17 cm. Visualized peristalsis appears appropriate. There were no focal lesions consistent with obstruction or a mass effect observed.

The ileocecal junction was visualized and exhibited normal intact wall layering and is subjectively of normal thickness. Sections of colon are visualized with formed fecal material and gas shadowing distally. There is no observed focal or generalized colon wall thickening or loss of layering.

### *Pancreas*

The left limb of the pancreas is prominent and mottled compared to the surrounding isoechoic mesentery. There is no evidence of nodules or cystic lesions. There is no evidence of regional mesenteric inflammation or fluid.

### *Free Abdomen*

Evaluation of the peritoneal cavity did not reveal any evidence of effusion. No significant lymphadenopathy noted. The omentum is slightly hyperechoic around the right ureter.

## ULTRASONOGRAPHIC FINDINGS

- Mild suspended echogenic debris in the urinary bladder and irregular, hyperechoic debris/tissue visualized in the apical ventral region. Correlate with a urinalysis and culture.
- Borderline large left kidney with mildly reduced corticomedullary distinction and a much smaller somewhat atrophied appearing right kidney with pyelectasia and hydroureter, and small mineralizations/nephroliths in both kidneys – Findings are most consistent with bilateral



## PATIENT

Tutu Kao

## SPECIES

Feline

## BREED

DSH

## SEX

Neutered Male

## AGE

12 Years 9 Months

## WEIGHT

11.7 lbs

## INTERPRETED BY

Kathleen Sennello DVM,  
MS, Diplomate ACVIM  
(Small Animal Internal  
Medicine)

## IMAGING PERFORMED BY

Megan Cassels-  
Conway, DVM

## HOSPITAL NAME

Central Broward  
Animal Hospital

## REFERRING VET

Janeen Lezcano, DVM

## INVOICE

75092

## DATE

5/12/26

chronic renal injury, right renal atrophy and possible right-sided obstructive disease.

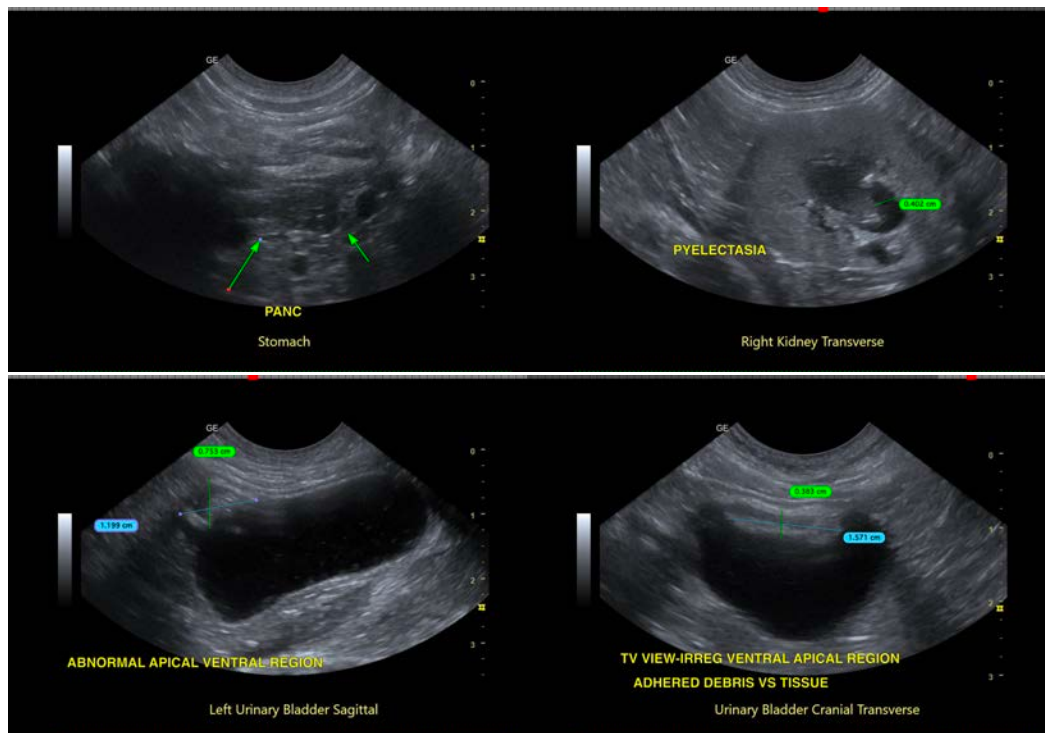
- Pancreatic changes most consistent with chronic pancreatic remodeling.
- Mildly “ropey” small intestine with some areas exhibiting a prominent muscularis layer – The small intestinal wall changes are most consistent with an inflammatory process (i.e., inflammatory bowel disease) with a low possibility of emerging lymphoma.

## INTERPRETATION OF THE FINDINGS & FURTHER RECOMMENDATIONS

Both kidneys have mildly reduced corticomedullary distinction. The right kidney in particular is smaller with more significant parenchymal change and significant pyelectasia and hydroureter. The distal ureter is lost to visualization. Findings are concerning for a possible obstructive lesion (stricture, small stone, mucus plug, etc.). Consider a contrast study (contrast CT scan, excretory urogram, etc.) to further evaluate in efforts to maintain a functioning right kidney. Additionally recommend a blood pressure, urinalysis and culture to further evaluate for possible pyelonephritis, hypertension, etc.

There is some irregular hyperechoic tissue/debris visualized in the apical ventral region of the urinary bladder. Consider evaluation with power doppler, looking for blood flow, and possible reevaluation over time, looking for improvement or progression of these changes. A mass effect seems less likely but cannot be ruled out in this region.

Some areas of small intestine appear somewhat “ropey”, possibly with mild inflammatory type changes. If underlying gastrointestinal disease is suspected, you could consider a GI panel to Texas A&M for a qualitative fPLI, TLI, cobalamin and folate to further evaluate.





**PATIENT**

Tutu Kao

**SPECIES**

Feline

**BREED**

DSH

**SEX**

Neutered Male

**AGE**

12 Years 9 Months

**WEIGHT**

11.7 lbs

**INTERPRETED BY**

Kathleen Sennello DVM,  
MS, Diplomate ACVIM  
(Small Animal Internal  
Medicine)

**IMAGING  
PERFORMED BY**

Megan Cassels-  
Conway, DVM

**HOSPITAL NAME**

Central Broward  
Animal Hospital

**REFERRING VET**

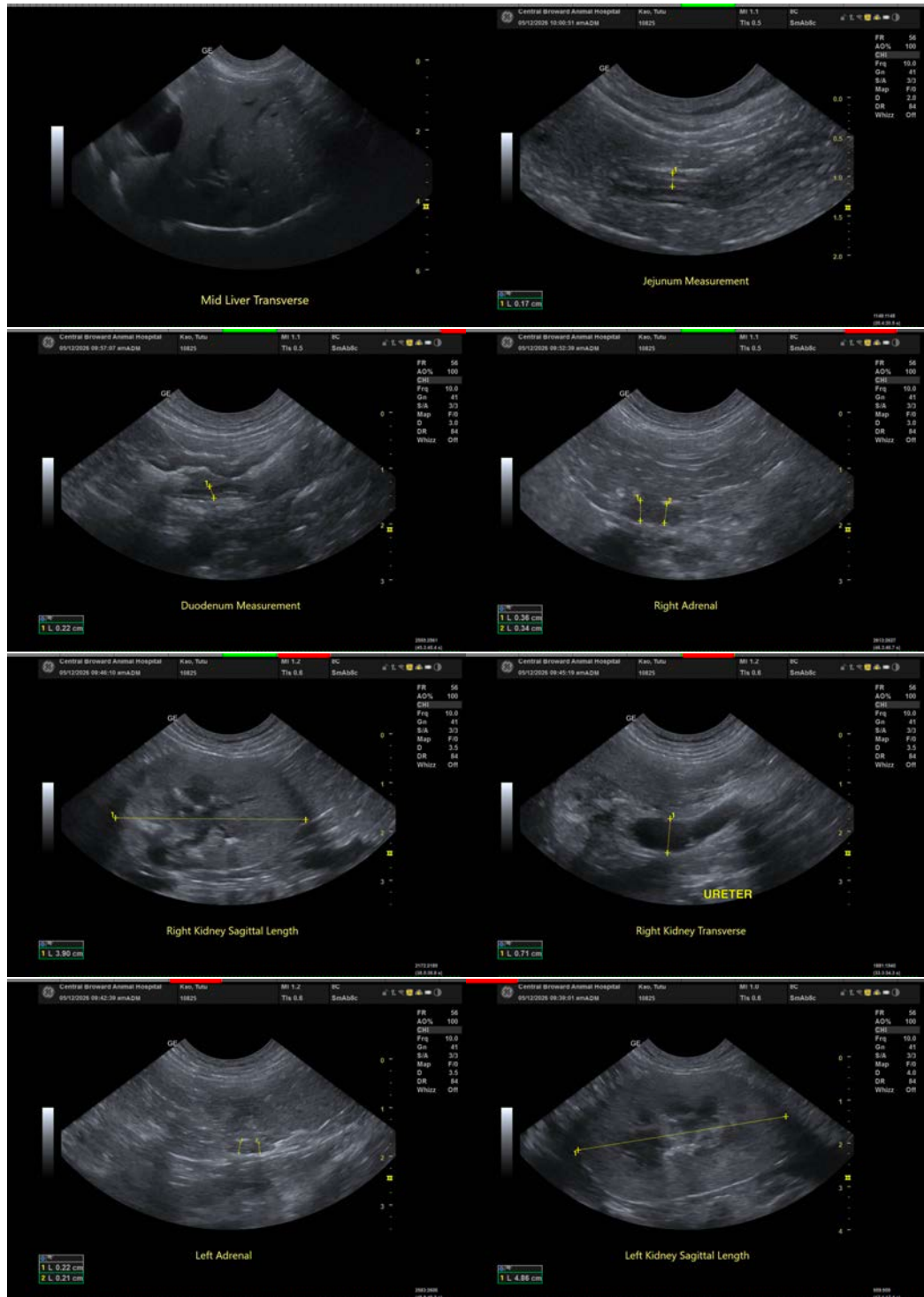
Janeen Lezcano, DVM

**INVOICE**

75092

**DATE**

5/12/26





## PATIENT

Tutu Kao

## SPECIES

Feline

## BREED

DSH

## SEX

Neutered Male

## AGE

12 Years 9 Months

## WEIGHT

11.7 lbs

## INTERPRETED BY

Kathleen Sennello DVM,  
MS, Diplomate ACVIM  
(Small Animal Internal  
Medicine)

## IMAGING PERFORMED BY

Megan Cassels-  
Conway, DVM

## HOSPITAL NAME

Central Broward  
Animal Hospital

## REFERRING VET

Janeen Lezcano, DVM

## INVOICE

75092

## DATE

5/12/26

The information and recommendations provided are based on the images presented by the referring veterinarian/sonographer. No evaluation can be communicated regarding pathology that was not visible in the image/video clips provided.

Thank you for this referral. If the clinical or image interpretation does not parallel your findings or if I can be of any further assistance please contact me.

Kathleen Sennello DVM,MS, Diplomate ACVIM (Small animal Internal Medicine)

info@sonopath.com