



## PATIENT

Mya Conroy

## SPECIES

Canine

## BREED

Terrier x

## SEX

Spayed Female

## AGE

9 Years

## WEIGHT

27 lbs

## INTERPRETED BY

Kathleen Sennello DVM,  
MS, Diplomate ACVIM  
(Small Animal Internal  
Medicine)

## IMAGING PERFORMED BY

Dr. Elaina Petrone

## HOSPITAL NAME

Long Branch Animal  
Hospital

## REFERRING VET

Dr. Elaina Petrone

## INVOICE

75078

## DATE

5/12/26

## PRESENTING CLINICAL SIGNS

- Intermittent gastroenteritis (vomiting, diarrhea)
- Mildly elevated ALP (164), cholesterol (404), and PSL (326) of unclear significance

## ULTRASONOGRAPHIC EXAMINATION OF THE ABDOMEN

### Urinary System

The urinary bladder is moderately distended with anechoic urine. The Bladder wall, trigone, ureteral papillae and visible urethra (to a depth of 2cm) appear normal with no evidence of wall thickening, mucosal irregularities, masses or cystic calculi.

The left kidney has a normal shape and size (4.81 cm). Overall echogenicity is normal with adequate corticomedullary distinction and a typical 1:3 cortex:medulla ratio. There is no evidence of focal perinephric inflammation or effusion. There is no evidence of pyelectasia, nephroliths, infarcts or hydroureter. Renal vasculature is normal.

The right kidney has a normal shape and size (4.34 cm). Overall echogenicity is normal with adequate corticomedullary distinction and a typical 1:3 cortex:medulla ratio. There is no evidence of focal perinephric inflammation or effusion. There is no evidence of pyelectasia, nephroliths, infarcts or hydroureter. Renal vasculature is normal.

### Adrenal Glands

The left adrenal gland is normal in size measuring 0.58 cm at the cranial pole and 0.53 cm at the caudal pole. It is observed in its normal position cranial to the left renal artery. It is normal in appearance (uniformly hypoechoic) and shape with no evidence of a mass effect.

The right adrenal gland is normal in size measuring 0.53 cm at the cranial pole and 0.62 cm at the caudal pole. It is observed in its normal position between the cranial aspect of the right kidney and the caudal vena cava. It is normal in appearance (uniformly hypoechoic) and shape with no evidence of a mass effect.

### Spleen

The spleen is subjectively normal in size (1.38 cm), echotexture is homogenous, and the splenic capsule is smooth with no irregularities. The blood flow through the hilus and splenic parenchyma appears normal. No focal parenchymal abnormalities are visualized.

### Liver

The liver is subjectively normal in size, and echogenicity with smooth peripheral margins. The parenchyma is homogenous echotexture. The visible portions of the vasculature and biliary tract appear normal. No focal nodules or cystic lesions are observed.

The gall bladder lumen is moderately distended. The wall of the gall bladder is not thickened and has a smooth mucosal surface. Luminal contents are mild and likely incidental at this time. The cystic and common bile ducts are normal/not visible.

### Gastrointestinal



## PATIENT

Mya Conroy

## SPECIES

Canine

## BREED

Terrier x

## SEX

Spayed Female

## AGE

9 Years

## WEIGHT

27 lbs

## INTERPRETED BY

Kathleen Sennello DVM,  
MS, Diplomate ACVIM  
(Small Animal Internal  
Medicine)

## IMAGING PERFORMED BY

Dr. Elaina Petrone

## HOSPITAL NAME

Long Branch Animal  
Hospital

## REFERRING VET

Dr. Elaina Petrone

## INVOICE

75078

## DATE

5/12/26

The stomach contains mild/moderate shadowing ingesta. It measures at a normal thickness of 0.42 cm with some variability due to the presence of rugal folds. The distinction of the gastric wall layers is adequate and there is no impression of reduced peristaltic activity. No masses or focal lesions were observed.

The visualized areas of duodenum, jejunum and ileum have a uniform diameter with minimal fluid distension. Wall appears subjectively, mildly increased. Bowel loops follow a typical curvilinear path with distinct wall layering. Duodenum wall measures 0.46 cm. Jejunum wall measures 0.30 cm.

Visualized peristalsis appears appropriate. There were no focal lesions consistent with obstruction or a mass effect observed.

Sections of colon are visualized with formed fecal material and gas shadowing distally. There is no observed focal or generalized colon wall thickening or loss of layering.

### ***Pancreas***

The pancreas is normal and isoechoic to surrounding mesentery. There is no evidence of nodules or cystic lesions. There is no evidence of regional mesenteric inflammation or fluid.

### ***Free Abdomen***

Evaluation of the peritoneal cavity did not reveal any evidence of effusion, or subjective lymphadenomegaly. The Medial iliac nodes appear normal and there was no evidence of a caudal aortic thrombus at the bifurcation. The omentum is of normal uniform echogenicity.

## ULTRASONOGRAPHIC FINDINGS

- Mild shadowing ingesta visualized within the gastric lumen – Correlate with feeding history. If the patient was adequately fasted this could represent a small amount of retained ingesta, ingested foreign material, etc.
- Slightly prominent/mildly thickened small intestine – The mild small intestinal wall changes may be a normal variant in this patient or could be consistent with an inflammatory process (e.g., inflammatory bowel disease).

## INTERPRETATION OF THE FINDINGS & FURTHER RECOMMENDATIONS

The changes observed on today's scan are mild. Subjectively the small intestine appears slightly tickened, most consistent with mild inflammatory type change. No significant focal lesions are visualized. There is a small amount of shadowing ingesta visualized within the stomach. This could represent a small amount of ingesta, delayed gastric emptying, etc. Correlate with the feeding history. A small outflow tract obstruction or thickening cannot be ruled out in this region. Consider the following for further evaluation:

- Consider a novel protein/hydrolyzed protein diet (exclusively at least 4-6 weeks)
- Consider a GI panel to Texas A&M for evaluation of B12 levels, folate, PLI/TLI etc.. to further evaluate for pancreatic/small intestinal disease.
- Recommend chronic probiotic therapy.



**PATIENT**

Mya Conroy

**SPECIES**

Canine

**BREED**

Terrier x

**SEX**

Spayed Female

**AGE**

9 Years

**WEIGHT**

27 lbs

**INTERPRETED BY**

Kathleen Sennello DVM,  
MS, Diplomate ACVIM  
(Small Animal Internal  
Medicine)

**IMAGING  
PERFORMED BY**

Dr. Elaina Petrone

**HOSPITAL NAME**

Long Branch Animal  
Hospital

**REFERRING VET**

Dr. Elaina Petrone

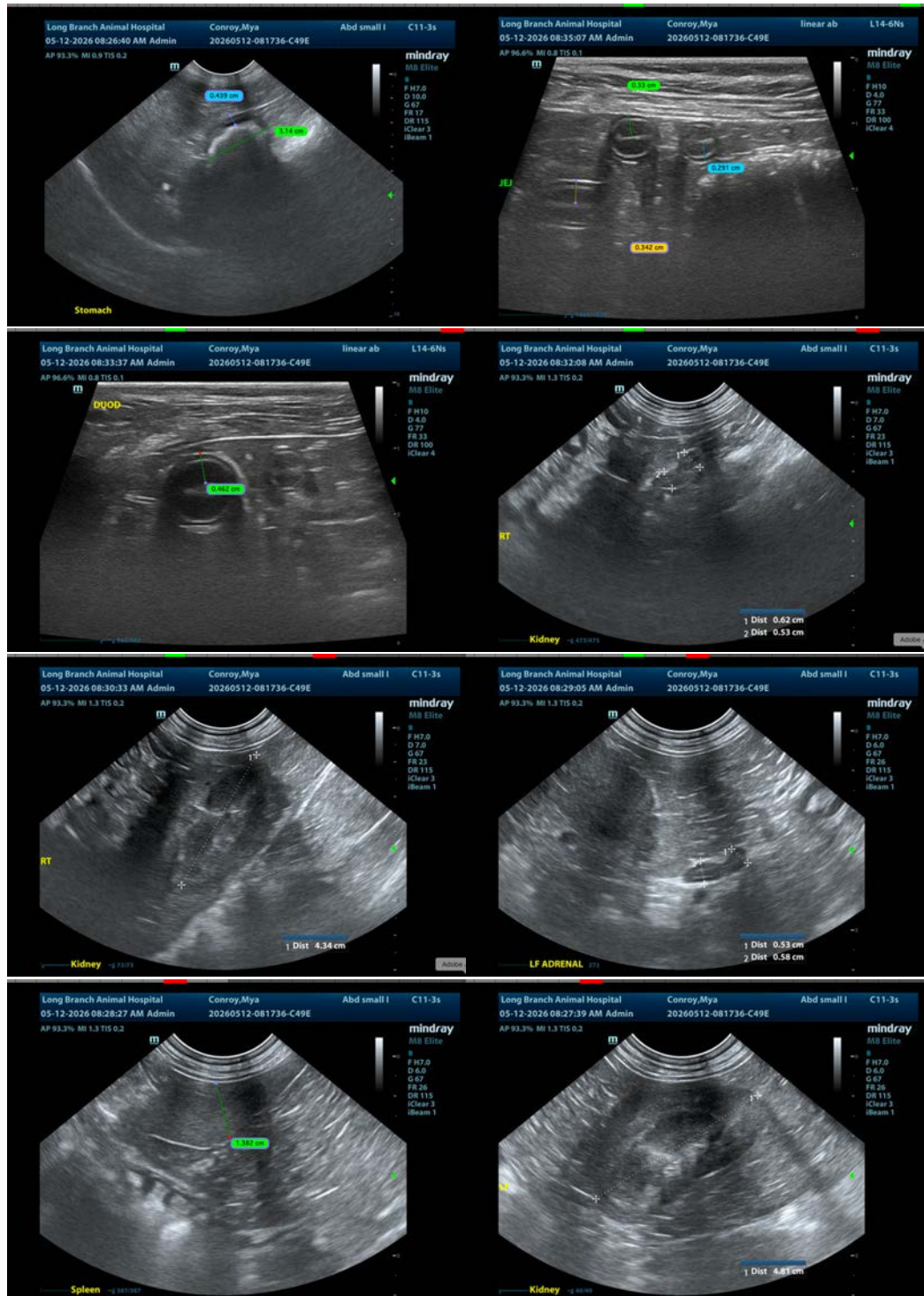
**INVOICE**

75078

**DATE**

5/12/26

If symptoms are persistent, ultimately biopsies of the GI tract may be warranted. Additionally, you could consider repeat imaging in the future, looking for the progression of today's lesions or the development of new lesions.





## PATIENT

Mya Conroy

## SPECIES

Canine

## BREED

Terrier x

## SEX

Spayed Female

## AGE

9 Years

## WEIGHT

27 lbs

## INTERPRETED BY

Kathleen Sennello DVM,  
MS, Diplomate ACVIM  
(Small Animal Internal  
Medicine)

## IMAGING PERFORMED BY

Dr. Elaina Petrone

## HOSPITAL NAME

Long Branch Animal  
Hospital

## REFERRING VET

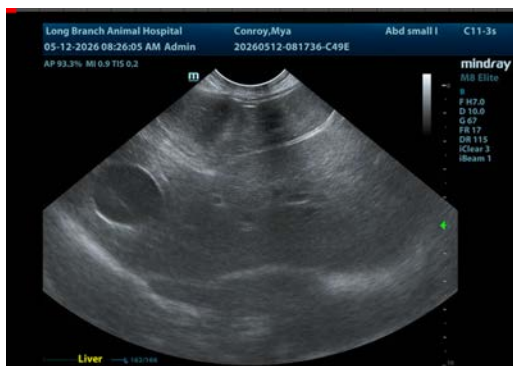Dr. Elaina Petrone

## INVOICE

75078

## DATE

5/12/26



The information and recommendations provided are based on the images presented by the referring veterinarian/sonographer. No evaluation can be communicated regarding pathology that was not visible in the image/video clips provided.

Thank you for this referral. If the clinical or image interpretation does not parallel your findings or if I can be of any further assistance please contact me.

Kathleen Sennello DVM,MS, Diplomate ACVIM (Small animal Internal Medicine)

info@sonopath.com