



PATIENT

Cooper Abernethy

SPECIES

Canine

BREED

Jack Russell Terrier

SEX

MN

AGE

13 years

WEIGHT

20 lbs

INTERPRETED BY

Kathleen Sennello DVM,
MS, Diplomate ACVIM
(Small Animal Internal
Medicine)

IMAGING PERFORMED BY

Dr. Danielle Shemanski

HOSPITAL NAME

Western New York
Veterinary Services

REFERRING VET

Dr. Catrina Turner

INVOICE

11937

DATE

5/12/2026

PRESENTING CLINICAL SIGNS

Mast cell tumor on lateral thorax (low grade per cytologist.)

CLINICAL SIGNS: None.

MEDICATIONS: Simparica Trio, Famotidine, Diphenhydramine.

Abnormal PE/Chem/CBC/UA Results: 4DX negative Mast cell tumor on lateral thorax (low grade per cytologist.)

ULTRASONOGRAPHIC EXAMINATION OF THE ABDOMEN

Urinary System

The urinary bladder is moderately distended with anechoic urine. The Bladder wall, trigone, ureteral papillae and visible urethra (to a depth of 2cm) appear normal with no evidence of wall thickening, mucosal irregularities, masses or cystic calculi.

The prostate is normal in size (0.86 cm) and shape for this neutered male dog. The parenchyma is homogenous and the external margins are smooth. The prostatic urethra appears normal with no evidence of irregularity, invasion, mass effect or calculi.

The left kidney has a normal shape and size (4.82 cm). Overall echogenicity is normal with adequate corticomedullary distinction and a typical 1:3 cortex:medulla ratio. There is no evidence of focal perinephric inflammation or effusion. There is no evidence of pyelectasia, nephroliths, infarcts or hydroureter. Renal vasculature is normal.

The right kidney has a normal shape and size (4.97 cm). Overall echogenicity is normal with adequate corticomedullary distinction and a typical 1:3 cortex:medulla ratio. There is no evidence of focal perinephric inflammation or effusion. There is no evidence of pyelectasia, nephroliths, infarcts or hydroureter. Renal vasculature is normal.

Adrenal Glands

The left adrenal gland is normal in size measuring 0.58 cm at the cranial pole and 0.71 cm at the caudal pole. It is observed in its normal position cranial to the left renal artery. It is normal in appearance (uniformly hypoechoic) and shape with no evidence of a mass effect.

The right adrenal gland is normal in size measuring 0.5 cm at the cranial pole and 0.53 cm at the caudal pole. It is observed in its normal position between the cranial aspect of the right kidney and the caudal vena cava. It is normal in appearance (uniformly hypoechoic) and shape with no evidence of a mass effect.

Spleen

The spleen is subjectively normal in size (2.07 cm) and the echotexture is homogenous. The splenic capsule is smooth with no visible irregularities. The blood flow through the hilus and splenic parenchyma appears normal. No focal parenchymal abnormalities are visualized.

Liver



PATIENT

Cooper Abernethy

SPECIES

Canine

BREED

Jack Russell Terrier

SEX

MN

AGE

13 years

WEIGHT

20 lbs

INTERPRETED BY

Kathleen Sennello DVM,
MS, Diplomate ACVIM
(Small Animal Internal
Medicine)

IMAGING PERFORMED BY

Dr. Danielle Shemanski

HOSPITAL NAME

Western New York
Veterinary Services

REFERRING VET

Dr. Catrina Turner

INVOICE

11937

DATE

5/12/2026

The liver is subjectively normal in size, and echogenicity with smooth peripheral margins. The parenchyma is homogenous echotexture. The visible portions of the vasculature and biliary tract appear normal. No focal nodules or cystic lesions are observed.

The gall bladder lumen is moderately distended. The wall of the gall bladder is not thickened and has a smooth mucosal surface. There is a moderate amount of non-organized echogenic debris. The cystic and common bile ducts are normal/not visible.

Gastrointestinal

The stomach is moderately dilated with fluid and irregular shadowing material most consistent with normal ingesta and gas. It measures at a normal thickness of <0.7cm with some variability due to the presence of rugal folds. The distinction of the gastric wall layering is adequate and there is no impression of reduced peristaltic activity. No masses or focal lesions were observed.

The visualized areas of duodenum, jejunum and ileum have a relatively uniform diameter with minimal fluid distension. Wall thickness is normal. Bowel loops follow a curvilinear path with distinct wall layering maintaining the typical 1:3 muscularis:mucosa layer ratio. The duodenum measured as normal (0.32 cm in wall thickness) and the jejunum measured as normal (0.22 cm.) Visualized peristalsis appears appropriate. There were no focal lesions consistent with obstruction or a mass effect observed.

Sections of colon are visualized with formed fecal material and gas shadowing distally. There is no observed focal or generalized colon wall thickening or loss of layering.

Pancreas

The pancreas is mildly mottled in the left limb. There is no evidence of nodules or cystic lesions. There is no evidence of regional mesenteric inflammation or fluid.

Free Abdomen

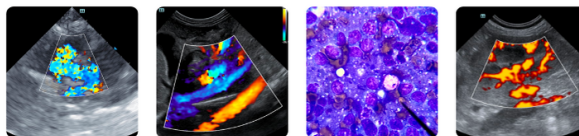
Evaluation of the peritoneal cavity did not reveal any evidence of effusion, or subjective lymphadenomegaly. The Medial iliac nodes appear normal and there was no evidence of a caudal aortic thrombus at the bifurcation. The omentum is of normal uniform echogenicity.

ULTRASONOGRAPHIC FINDINGS

- Pancreatic changes most consistent with chronic pancreatic remodeling in the left limb.
- Moderate gallbladder debris. The significance of the aggregated gallbladder debris is unclear. This could represent an early mucocele, cholestasis, or may be secondary to fasting but seems unlikely to be causing a current issue. Recommend continued monitoring.
- Moderate fluid/ingesta visualized within the gastric lumen, correlate with the feeding history. If the patient was adequately fasted, this could represent delayed gastric emptying.

INTERPRETATION OF THE FINDINGS & FURTHER RECOMMENDATIONS

Today's scan is likely within normal limits for this patient. There are mild changes visualized associated with the pancreas, with no active inflammation noted and there's a small amount of debris in the gallbladder with no evidence of surrounding inflammation or wall thickening. In the absence of liver enzyme elevations this likely is incidental at this time. No significant nodules, mass lesions, or



PATIENT

lymphadenopathy is noted.

Cooper Abernethy

SPECIES

Canine

BREED

Jack Russell Terrier

SEX

MN

AGE

13 years

WEIGHT

20 lbs

INTERPRETED BY

Kathleen Sennello DVM,
MS, Diplomate ACVIM
(Small Animal Internal
Medicine)

**IMAGING
PERFORMED BY**

Dr. Danielle Shemanski

HOSPITAL NAME

Western New York
Veterinary Services

REFERRING VET

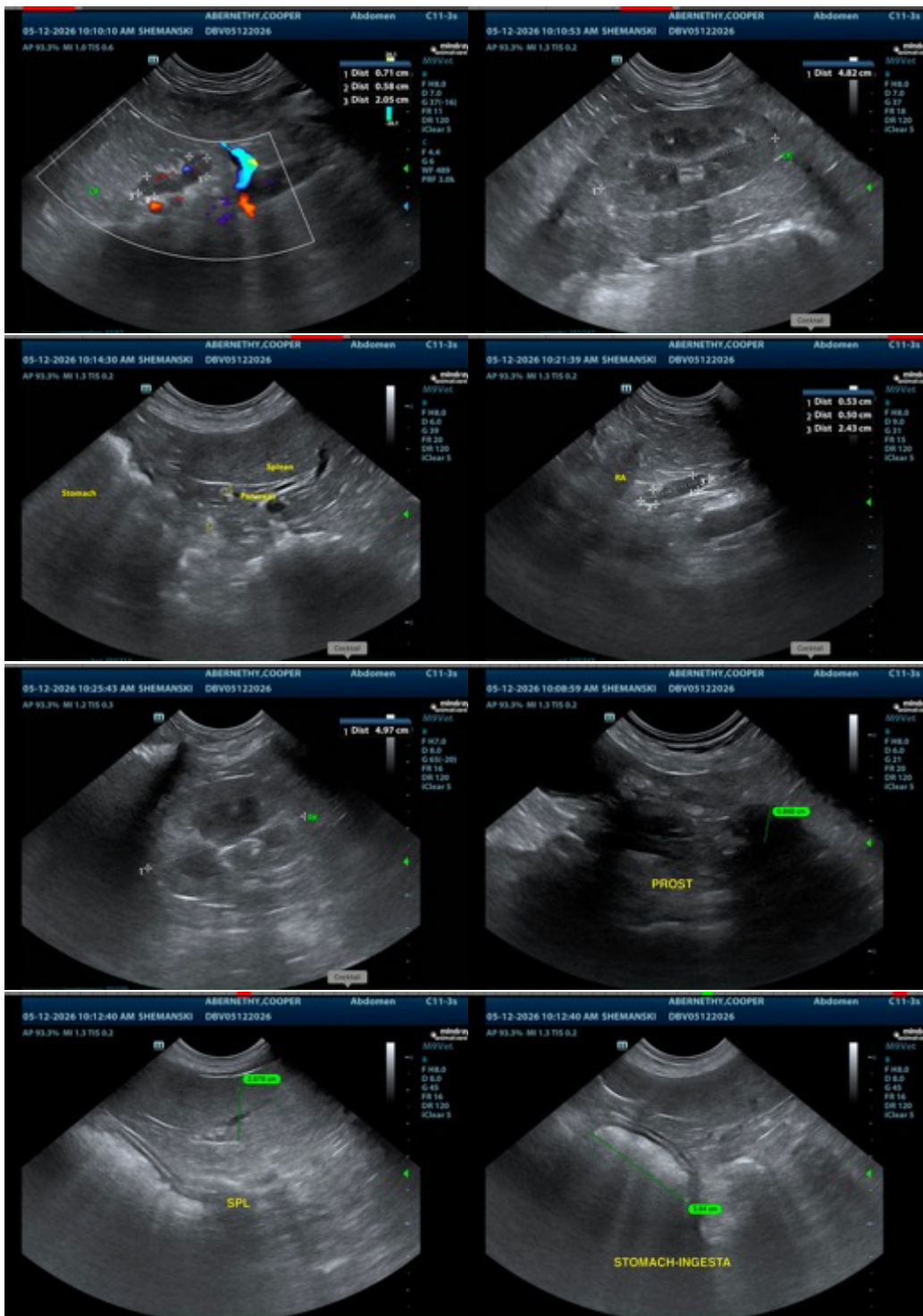
Dr. Catrina Turner

INVOICE

11937

DATE

5/12/2026





PATIENT

Cooper Abernethy

SPECIES

Canine

BREED

Jack Russell Terrier

SEX

MN

AGE

13 years

WEIGHT

20 lbs

INTERPRETED BY

Kathleen Sennello DVM,
MS, Diplomate ACVIM
(Small Animal Internal
Medicine)

IMAGING PERFORMED BY

Dr. Danielle Shemanski

HOSPITAL NAME

Western New York
Veterinary Services

REFERRING VET

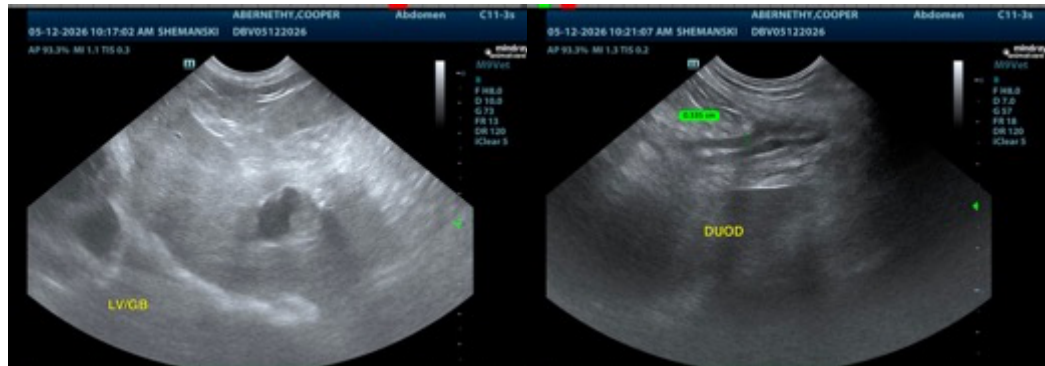Dr. Catrina Turner

INVOICE

11937

DATE

5/12/2026



The information and recommendations provided are based on the images presented by the referring veterinarian/sonographer. No evaluation can be communicated regarding pathology that was not visible in the image/video clips provided.

Thank you for this referral. If the clinical or image interpretation does not parallel your findings or if I can be of any further assistance please contact me.

Kathleen Sennello DVM,MS, Diplomate ACVIM (Small animal Internal Medicine)

info@sonopath.com