SonoPath
Clinical Sonography & Telecytology
EDUCATIONAL TELECONSULTATION SERVICES™

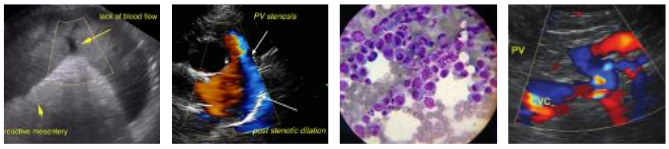

SonoPath.com™
1-800-838-4268 info@sonopath.com

PATIENT
Riley Branham

SPECIES
Feline

BREED
DSH

SEX
Spayed Female

AGE
8 Years

WEIGHT
12.9 Pounds

INTERPRETED BY
Kathleen Sennello DVM, MS, Diplomate ACVIM (Small Animal Internal Medicine)

IMAGING PERFORMED BY
Shari Reffi, CVT

HOSPITAL NAME
Branchville Country Vet

REFERRING VET
Dr. Sherri Talbot-Valerio

INVOICE
15127

DATE
5/12/22

PRESENTING CLINICAL SIGNS

History: Vomiting. Possible abdominal mass vs other on rads. No current meds.

Abnormal PE/Chem/CBC/UA Results: Decreased Hct, Hgb and retic. Chem and electrolytes=wnl

ULTRASONOGRAPHIC EXAMINATION OF THE ABDOMEN

Urinary System

The urinary bladder is moderately distended with anechoic urine. The Bladder wall, trigone, ureteral papillae and visible urethra (to a depth of 2cm) appear normal with no evidence of wall thickening, mucosal irregularities, masses or cystic calculi.

The left kidney has a normal shape and size (3.91 cm). Overall echogenicity is normal with adequate corticomedullary distinction and a typical 1:3 cortex:medulla ratio. There is no evidence of perinephric inflammation or effusion. There is no evidence of pyelectasia, infarcts or hydroureter. Renal vasculature is normal. Cortical mineralizations were present.

The right kidney has a normal shape and size (3.86 cm). Overall echogenicity is normal with adequate corticomedullary distinction and a typical 1:3 cortex:medulla ratio. There is no evidence of perinephric inflammation or effusion. There is no evidence of pyelectasia, infarcts or hydroureter. Renal vasculature is normal. Cortical mineralizations were present.

Adrenal Glands

The region of left adrenal (Cranial to left renal artery) is unremarkable, but the adrenal is not distinctly visualized. No evidence of a mass effect.

The right adrenal gland is normal in size measuring 0.46 cm at the caudal pole. It is observed in its normal position between the cranial aspect of the right kidney and the caudal vena cava. It is normal in appearance (uniformly hypoechoic) and shape with no evidence of a mass effect.

Spleen

The spleen is subjectively normal in size, echotexture is homogenous, and the splenic capsule is smooth with no irregularities. The blood flow through the hilus and splenic parenchyma appears normal. No focal parenchymal abnormalities are visualized.

Liver

The liver is subjectively (normal, large, small, normal/large, normal/small) in size, and echogenicity with smooth peripheral margins. The parenchyma is heterogenous in echotexture with subtle, indistinct focal mottling. The visible portions of the vasculature and biliary tract appear normal. No focal nodules or cystic lesions are observed

The gall bladder lumen is moderately distended. The wall of the gall bladder is not thickened and has a smooth mucosal surface. Luminal contents are primarily anechoic. The cystic and common bile ducts are normal/not visible.

Gastrointestinal

The stomach contains minimal luminal contents. It measures at a normal thickness of <0.36cm with some variability due to the presence of rugal folds. The distinction of the gastric wall layers is

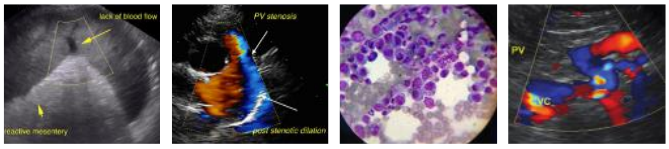

SonoPath.com™
1-800-838-4268 info@sonopath.com

PATIENT

Riley Branham

SPECIES

Feline

BREED

DSH

SEX

Spayed Female

AGE

8 Years

WEIGHT

12.9 Pounds

INTERPRETED BY

Kathleen Sennello DVM, MS, Diplomate ACVIM (Small Animal Internal Medicine)

IMAGING PERFORMED BY

Shari Reffi, CVT

HOSPITAL NAME

Branchville Country Vet

REFERRING VET

Dr. Sherri Talbot-Valerio

INVOICE

15127

DATE

5/12/22

adequate and there is no impression of reduced peristaltic activity. No masses or focal lesions were observed.

The visualized areas of duodenum, jejunum and ileum have a relatively uniform diameter with minimal/mild fluid distension. Wall thickness is normal. Bowel loops follow a curvilinear path with distinct wall layering maintaining the typical 1:3 muscularis: mucosa layer ratio. The duodenum measured as normal (0.21 cm in wall thickness), and the jejunum measured as normal (0.19 cm) Visualized peristalsis appears appropriate. The duodenum appears focally thickened and edematous in the areas adjacent to the abnormal pancreas. Additionally, there is some fluid dilation and occasional shadowing material visualized intraluminally (likely hair etc..).

The ileocecal junction was visualized and exhibited normal intact wall layering and is subjectively of normal thickness. Sections of colon are visualized with formed fecal material and gas shadowing distally. There is no observed focal or generalized colon wall thickening or loss of layering.

Pancreas

The pancreas is large and hypoechoic to surrounding mesentery. The right limb of the pancreas is diffusely cystic and fluid pocketed in the region associated closely with the duodenum. These lesions could be consistent with cysts or abscesses. There is evidence of severe regional mesenteric inflammation, edema and scant fluid, most consistent with severe pancreatitis and possible abscessation. Necrotizing pancreatitis is a possibility.

Free Abdomen

There is scant free fluid and edema in the region around the pancreas. There is no lymphadenopathy noted. The omentum is severely hyperechoic in the region around the pancreas.

ULTRASONOGRAPHIC FINDINGS

- Severe pancreatic inflammation with focal fluid pockets, most consistent with abscessation or cystic lesions. Necrotizing pancreatitis is a possibility. Surrounding peritonitis is present (likely sterile)
- Heterogeneous liver. Hepatic changes are non-specific and could be consistent with inflammation/infection (cholangiohepatitis), infiltrative neoplasia, lipidosis or other hepatopathy.
- Focal duodenitis in the region adjacent to the pancreas with fluid dilation and mild non-obstructive shadowing material (hair?).

INTERPRETATION OF THE FINDINGS & FURTHER RECOMMENDATIONS

The pancreas is severely inflamed, hypoechoic and irregular, particularly in the right limb, where there are numerous small fluid loculations, most consistent with small abscesses or cystic lesions. The largest fluid filled pocket appears approximately 1.0 cm in diameter. There is regional severe duodenitis and shadowing material visualized within the duodenum, which does not appear to be obstructive, but should continue to be monitored and reevaluated with radiographs to ensure problematic foreign material is not present.
I recommend a fine needle aspirate of at least one of the fluid pockets with sampling for fluid analysis, cytology and culture (aerobic and anaerobic). If a larger pocket is identified and drained, it would be possible to instill Baytril if an abscess is strongly suspected. I recommend aggressive therapy for acute pancreatitis/necrotizing pancretitis.

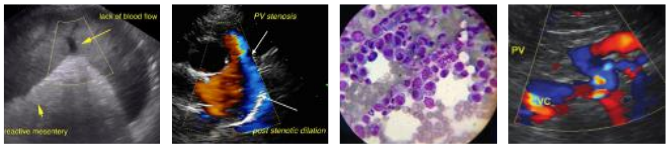

SonoPath.com™
1-800-838-4268 info@sonopath.com

PATIENT

Riley Branham

SPECIES

Feline

BREED

DSH

SEX

Spayed Female

AGE

8 Years

WEIGHT

12.9 Pounds

INTERPRETED BY

Kathleen Sennello DVM, MS, Diplomate ACVIM (Small Animal Internal Medicine)

IMAGING PERFORMED BY

Shari Reffi, CVT

HOSPITAL NAME

Branchville Country Vet

REFERRING VET

Dr. Sherri Talbot-Valerio

INVOICE

15127

DATE

5/12/22

Additionally, the liver is heterogeneous. If significant liver enzyme elevations are present and coagulation parameters are normal, you could consider a fine needle aspirate of the liver to rule out concurrent round cell neoplasia.

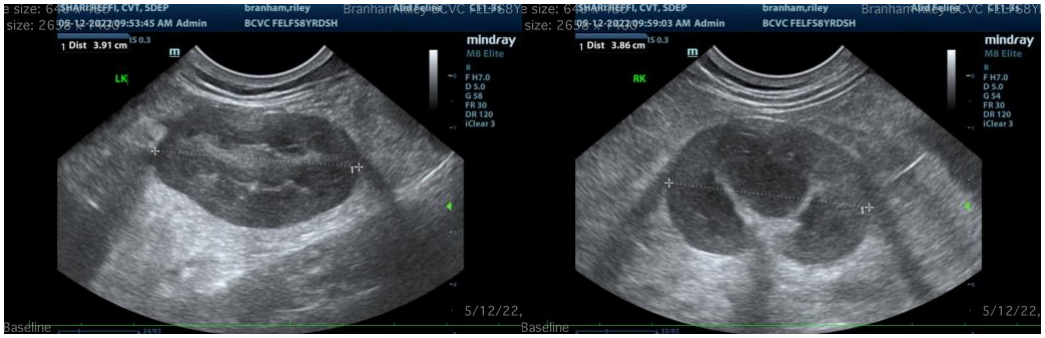

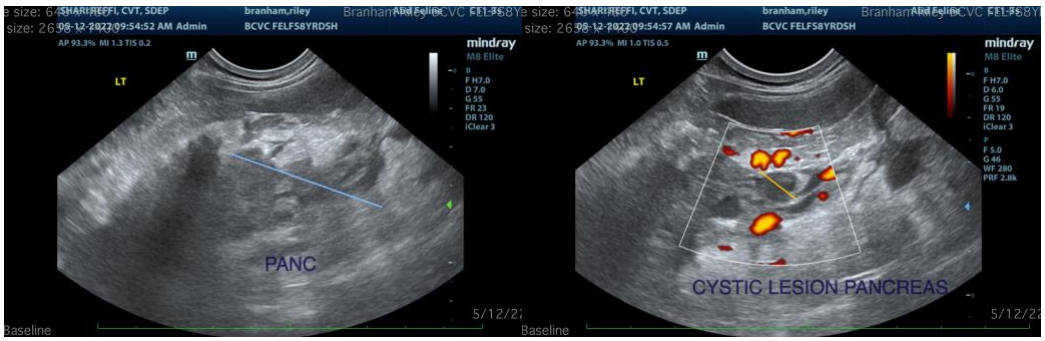

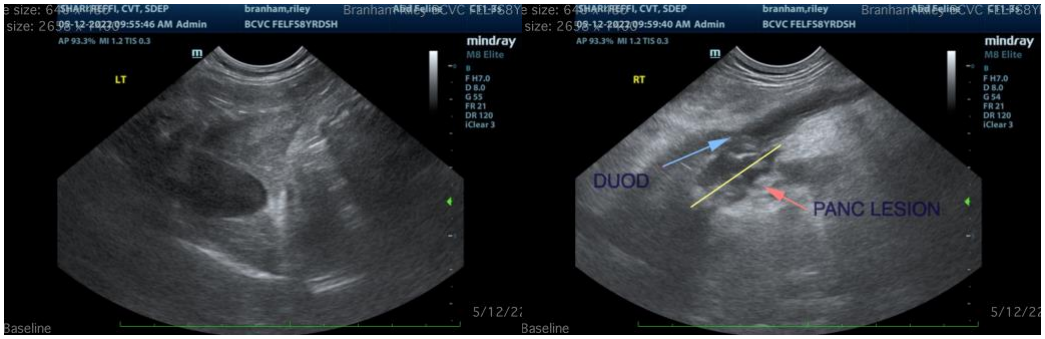

SonoPath
Clinical Sonography & Telecytology

EDUCATIONAL TELECONSULTATION SERVICES™

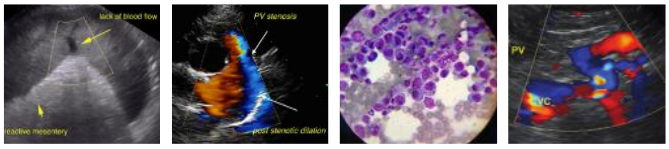

SonoPath.com™
1-800-838-4268 info@sonopath.com

PATIENT

Riley Branham

SPECIES

Feline

BREED

DSH

SEX

Spayed Female

AGE

8 Years

WEIGHT

12.9 Pounds

INTERPRETED BY

Kathleen Sennello DVM, MS, Diplomate ACVIM (Small Animal Internal Medicine)

IMAGING PERFORMED BY

Shari Reffi, CVT

HOSPITAL NAME

Branchville Country Vet

REFERRING VET

Dr. Sherri Talbot-Valerio

INVOICE

15127

DATE

5/12/22

The information and recommendations provided are based on the images presented by the referring veterinarian. No evaluation can be communicated regarding pathology that was not visible in the image/video clips provided.

Thank you for this referral. If the clinical or image interpretation does not parallel your findings or if I can be of any further assistance please contact me.

Kathleen Sennello DVM,MS, Diplomate ACVIM (Small animal Internal Medicine)
kathleen.sennello@sonopath.com