



PATIENT

Oliver Fitzpatrick

PRESENTING CLINICAL SIGNS

History: inappetence, not responding to treatment meds: ursodiol, ampicillin, metronidazole
Abnormal PE/Chem/CBC/UA Results: cPLi abnormal

SPECIES

Feline

ULTRASONOGRAPHIC EXAMINATION OF THE ABDOMEN

Urinary System

The urinary bladder is moderately distended with anechoic urine. The Bladder wall, trigone, ureteral papillae and visible urethra (to a depth of 2cm) appear normal with no evidence of wall thickening, mucosal irregularities, masses or cystic calculi.

BREED

DLH

The left kidney has a normal shape and size (4.37 cm). Overall echogenicity is normal with adequate corticomedullary distinction and a typical 1:3 cortex:medulla ratio. There is no evidence of perinephric inflammation or effusion. There is no evidence of pyelectasia, nephroliths, infarcts or hydroureter. Renal vasculature is normal.

SEX

Neutered Male

The right kidney has a normal shape and size (4.33 cm). Overall echogenicity is normal with adequate corticomedullary distinction and a typical 1:3 cortex:medulla ratio. There is no evidence of perinephric inflammation or effusion. There is no evidence of pyelectasia, nephroliths, infarcts or hydroureter. Renal vasculature is normal.

AGE

8 years

WEIGHT

16.8 Pounds

Adrenal Glands

The left adrenal gland is normal in size measuring 0.28 cm at the caudal pole. It is observed in its normal position cranial to the left renal artery. It is normal in appearance (uniformly hypoechoic) and shape with no evidence of a mass effect.

INTERPRETED BY

Kathleen Sennello DVM,
MS, Diplomate ACVIM
(Small Animal Internal
Medicine)

The right adrenal gland is normal in size measuring 0.37 cm at the caudal pole. It is observed in its normal position between the cranial aspect of the right kidney and the caudal vena cava. It is normal in appearance (uniformly hypoechoic) and shape with no evidence of a mass effect.

IMAGING PERFORMED BY

Kelly Reshny, RVT

Spleen

The spleen is subjectively normal in size, echotexture is homogenous, and the splenic capsule is smooth with no irregularities. The blood flow through the hilus and splenic parenchyma appears normal. No focal parenchymal abnormalities are visualized.

HOSPITAL NAME

Dog and Cat Clinic of
Niagra

Liver

The liver is subjectively normal in size, and echogenicity with smooth peripheral margins. The parenchyma is homogenous echotexture. The visible portions of the vasculature and biliary tract appear normal. No focal nodules or cystic lesions are observed.

REFERRING VET

Dr. Habib

The gall bladder lumen is moderately distended. The wall of the gall bladder is not thickened and has a smooth mucosal surface. Luminal contents are primarily anechoic. The cystic and common bile ducts are normal/not visible.

INVOICE

15130

Gastrointestinal

The stomach contains minimal luminal contents. It measures at a normal thickness of <0.36cm with some variability due to the presence of rugal folds. The distinction of the gastric wall layers is adequate and there is no impression of reduced peristaltic activity. No masses or focal lesions were observed.

DATE

5/12/22



PATIENT

Oliver Fitzpatrick

The visualized areas of duodenum, jejunum and ileum have a relatively uniform diameter with minimal fluid distension. Wall thickness is normal. Bowel loops follow a curvilinear path with distinct wall layering maintaining the typical 1:3 muscularis:mucosa layer ratio. The duodenum measured as normal (0.25 cm). Visualized peristalsis appears appropriate. There were no focal lesions consistent with obstruction or a mass effect observed.

SPECIES

Feline

The ileocecal junction was visualized and exhibited normal intact wall layering and is subjectively of normal thickness. Sections of colon are visualized with formed fecal material and gas shadowing distally. There is no observed focal or generalized colon wall thickening or loss of layering.

BREED

DLH

Pancreas

The (pancreas/region of the pancreas) is normal and isoechoic to surrounding mesentery. There is no evidence of nodules or cystic lesions. There is no evidence of regional mesenteric inflammation or fluid.

SEX

Neutered Male

Free Abdomen

Evaluation of the peritoneal cavity did not reveal any evidence of effusion, or subjective lymphadenomegaly. The Medial iliac nodes appear normal and there was no evidence of a caudal aortic thrombus at the bifurcation. The omentum is of normal uniform echogenicity.

AGE

8 years

ULTRASONOGRAPHIC FINDINGS

- No significant ultrasonographic abnormalities noted.

WEIGHT

16.8 Pounds

INTERPRETATION OF THE FINDINGS & FURTHER RECOMMENDATIONS

Today's ultrasonographic exam appears relatively normal for a large middle-aged cat. Unfortunately, there can be many causes for inappetence, which cannot be definitively diagnosed by ultrasound alone. Correlate with blood work findings. The history reports an abnormal PLI. Unfortunately, significant clinical pancreatic disease can be present without significant ultrasonographic abnormalities.

INTERPRETED BY

Kathleen Sennello DVM,
MS, Diplomate ACVIM
(Small Animal Internal
Medicine)

IMAGING

PERFORMED BY

Kelly Reshny, RVT

- Consider a GI panel (to Texas A & M) for a qualitative fPLI, TLI, cobalamin and folate to look for evidence of small intestinal and pancreatic disease.
- I recommend three-view thoracic radiographs.
- Consider symptomatic treatment for pancreatitis/gastroenteritis (appetite stimulant, probiotics, nausea medication, etc.). If not responding to therapy, consider repeat evaluation, radiographs, etc. Upper Gi endoscopy could be considered to evaluate the stomach and obtain GI biopsies, if underlying gastrointestinal disease is suspected.

HOSPITAL NAME

Dog and Cat Clinic of
Niagra

REFERRING VET

Dr. Habib

INVOICE

15130

DATE

5/12/22



PATIENT

Oliver Fitzpatrick

SPECIES

Feline

BREED

DLH

SEX

Neutered Male

AGE

8 years

WEIGHT

16.8 Pounds

INTERPRETED BY

Kathleen Sennello DVM,
MS, Diplomate ACVIM
(Small Animal Internal
Medicine)

**IMAGING
PERFORMED BY**

Kelly Reshny, RVT

HOSPITAL NAME

Dog and Cat Clinic of
Niagra

REFERRING VET

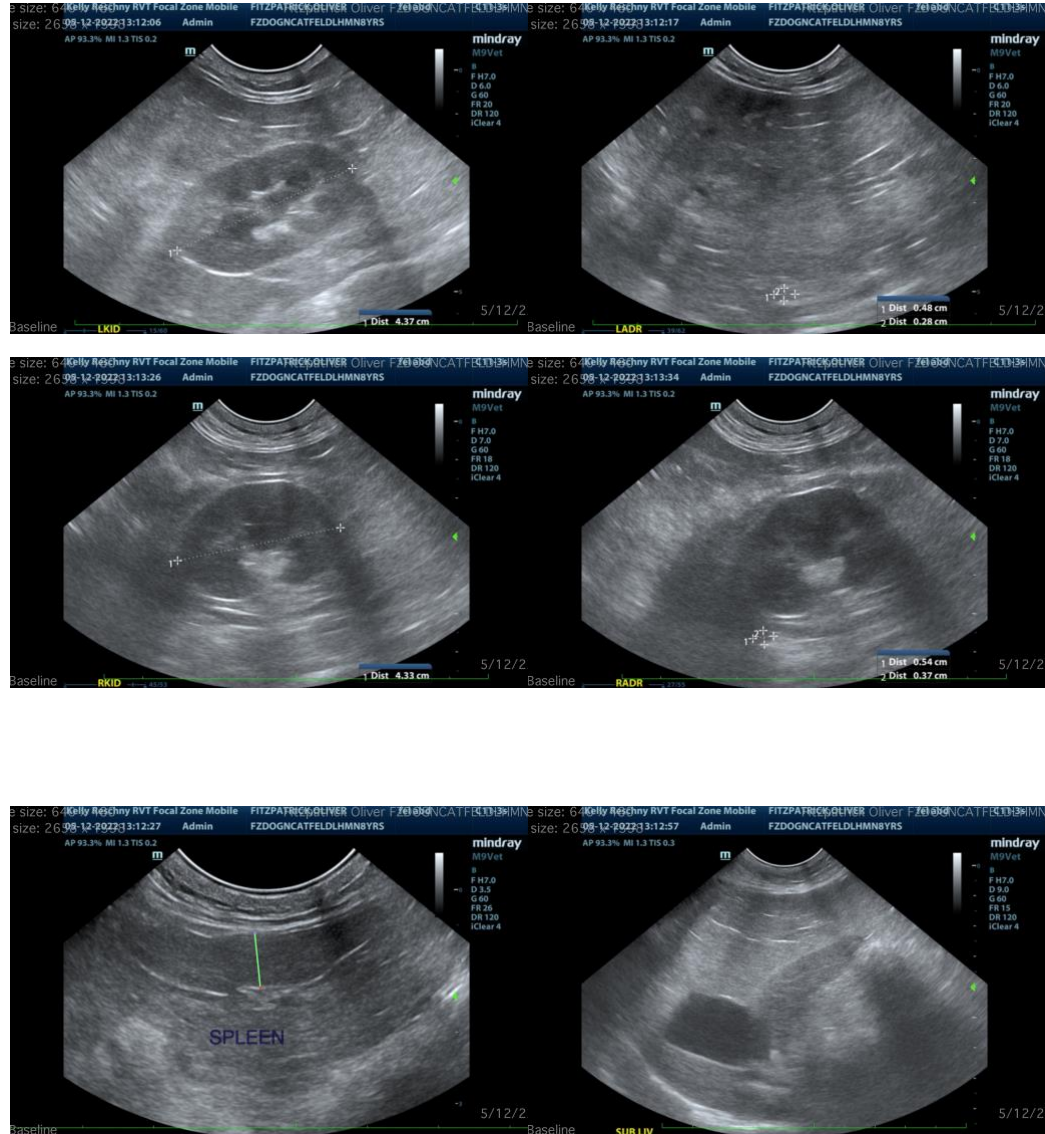
Dr. Habib

INVOICE

15130

DATE

5/12/22



The information and recommendations provided are based on the images presented by the referring veterinarian. No evaluation can be communicated regarding pathology that was not visible in the image/video clips provided.

Thank you for this referral. If the clinical or image interpretation does not parallel your findings or if I can be of any further assistance please contact me.

Kathleen Sennello DVM,MS, Diplomate ACVIM (Small animal Internal Medicine)
kathleen.sennello@sonopath.com