

**DATE PRESENTING CLINICAL SIGNS**

5/12/22

**PATIENT**

Dizzy King

History: Past 6 months has been having a labored wheeze, cough. Notable weight loss. No nasal discharge. PE: Audible nasal congestion and referred upper respiratory sounds. Has a history of "GI disease" and been treated with prednisolone for years. Treated with Convenia; no improvement. No longer eating or drinking past 36 hours.

**SPECIES**

Feline

Current Medications: Prednisolone 2.5mg PO EOD (years), Convenia 0.3ml SQ.

Lab Results: 5/10/22- Mild hyperchromic, normocytic non-regenerative anemia (HCT 36.1%), Mild hyperglycemia 184mg/dL, SDMA 23mg/dL

Creat 2.2mg/dL, BUN 40mg/dL. UA (cysto): USG 1.019, pH 6.5, inactive sediment, T4: 2.0ug/dL

**BREED**

DSH

Date of Previous IntraPet Ultrasound: No previous.

Sedation: Not required to complete full diagnostic ultrasound.

Stat Report: Not requested.

**SEX**

Neutered Male

Imaging Performed By: Andi Parkinson, RDMS.

**ULTRASONOGRAPHIC EXAMINATION OF THE ABDOMEN****AGE**

7/20/2007

**Urinary System**

The urinary bladder is moderately distended with anechoic urine. The Bladder wall, trigone, ureteral papillae and visible urethra (to a depth of 2cm) appear normal with no evidence of wall thickening, mucosal irregularities, masses or cystic calculi.

**WEIGHT**

7.37 Pounds

The left kidney has a normal shape and size (3.6 cm). Overall echogenicity is normal with adequate corticomedullary distinction and a typical 1:3 cortex:medulla ratio. There is no evidence of perinephric inflammation or effusion. There is no evidence of pyelectasia, nephroliths, infarcts or hydroureter. Renal vasculature is normal.

**INTERPRETED BY**

Kathleen Sennello DVM,  
MS, Diplomate ACVIM  
(Small Animal Internal  
Medicine)

The right kidney has a normal shape and size (3.53 cm). Overall echogenicity is normal with adequate corticomedullary distinction and a typical 1:3 cortex:medulla ratio. There is no evidence of perinephric inflammation or effusion. There is no evidence of pyelectasia, nephroliths, infarcts or hydroureter. Renal vasculature is normal.

**HOSPITAL NAME**

Timonium AH

**Adrenal Glands**

The left adrenal gland is normal in size measuring 0.4 cm at the caudal pole. It is observed in its normal position cranial to the left renal artery. It is normal in appearance (uniformly hypoechoic) and shape with no evidence of a mass effect.

**REFERRING VET**

Dr. Falkowski

The right adrenal gland is normal in size measuring 0.38 cm at the caudal pole. It is observed in its normal position between the cranial aspect of the right kidney and the caudal vena cava. It is normal in appearance (uniformly hypoechoic) and shape with no evidence of a mass effect.

**INVOICE**

15146

**Spleen**

The spleen is subjectively normal in size, echotexture is homogenous, and the splenic capsule is smooth with no irregularities. The blood flow through the hilus and splenic parenchyma appears normal. No focal parenchymal abnormalities are visualized.

**Liver**

The liver is subjectively normal in size, and echogenicity with smooth peripheral margins. The parenchyma is heterogenous in echotexture with subtle, indistinct focal mottling. The visible portions of the vasculature and biliary tract appear normal. No focal nodules or cystic lesions are observed.

The gall bladder lumen is moderately distended. The wall of the gall bladder is not thickened and has a smooth mucosal surface. There is a moderate amount of non-organized echogenic debris. The cystic and common bile ducts are normal/not visible.

### ***Gastrointestinal***

The stomach contains minimal luminal contents. It measures at a normal thickness of <0.36cm with some variability due to the presence of rugal folds. The distinction of the gastric wall layers is adequate and there is no impression of reduced peristaltic activity. No masses or focal lesions were observed.

The visualized areas of duodenum, jejunum and ileum have a relatively uniform diameter with minimal fluid distension. Wall thickness is normal. Bowel loops follow a curvilinear path with distinct wall layering maintaining the typical 1:3 muscularis: mucosa layer ratio. The duodenum measured as normal (between 0.13-0.38 cm in wall thickness) and the jejunum measured as normal (between 0.15-0.36 cm.) Visualized peristalsis appears appropriate. There were no focal lesions consistent with obstruction or a mass effect observed.

The ileocecal junction was visualized and exhibited normal intact wall layering and is subjectively of normal thickness. Sections of colon are visualized with formed fecal material and gas shadowing distally. There is no observed focal or generalized colon wall thickening or loss of layering.

### ***Pancreas***

The pancreas is prominent and hypoechoic as compared to the surrounding isoechoic mesentery. There are numerous irregular hypoechoic nodules visualized adjacent to or within the pancreatic parenchyma. The largest is visualized in the left side, measuring 1.42 cm x 0.8 cm, another is 1.0 cm x 1.51 cm. There is no evidence of regional mesenteric fluid and minimal inflammation.

### ***Free Abdomen***

There is no free fluid. There is a prominent lymph node visualized in the cranial abdomen, measuring 0.54 cm and the omentum is generally of normal echogenicity. There is a cystic structure in the right cranial abdomen, measuring 1.49 cm x 0.86 cm, which is most consistent with a benign hepatic cyst.

### ***Other***

No significant pericardial effusion noted.

## **ULTRASONOGRAPHIC FINDINGS**

### **Primary Findings**

- Prominent hypoechoic pancreas with irregular hypoechoic nodules. The findings are consistent with previous or current pancreatic inflammation and the nodules are concerning for a possible neoplastic process. I recommend a fine needle aspirate.
- Heterogeneous liver. Hepatic changes are non-specific and could be consistent with inflammation/infection (cholangiohepatitis), infiltrative neoplasia, lipidosis or other hepatopathy.
- Moderate gallbladder debris. The significance of the aggregated moderate gallbladder debris is unclear. This could represent an early mucocele, cholestasis, or may be secondary to fasting.

Incidental gall bladder debris is less common in cats.

- Prominent lymph node in the cranial abdomen. The prominent abdominal lymph nodes are most consistent with reactive lymphadenitis or lymphoid hyperplasia. Neoplastic infiltration is considered less likely.

### Secondary Findings

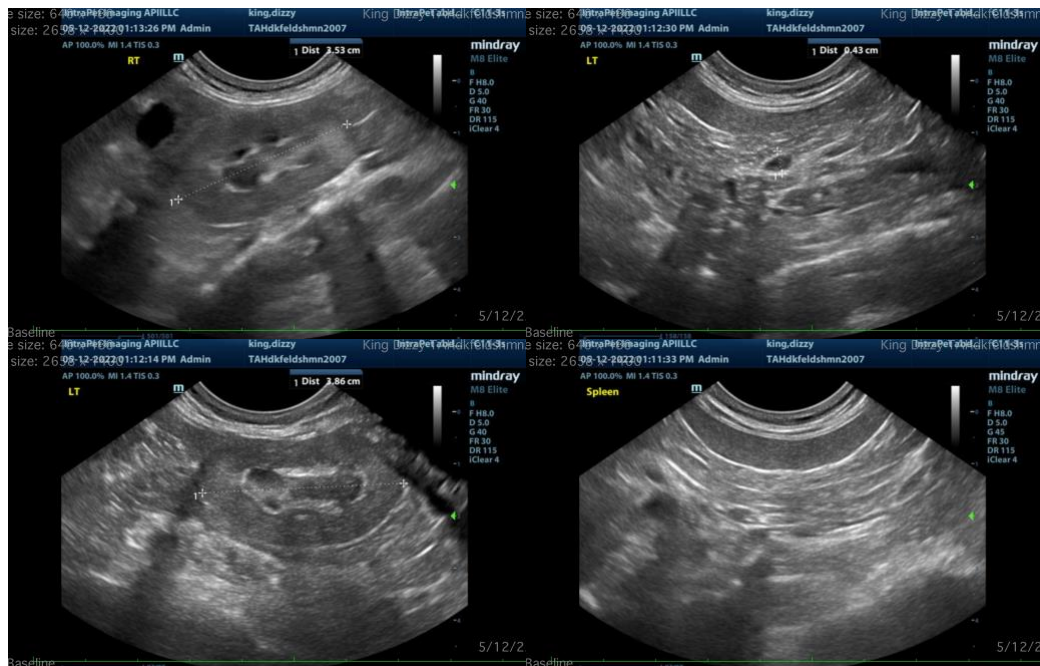
- Decreased corticomedullary distinction for both kidneys. The bilateral renal findings are consistent with age-related change.

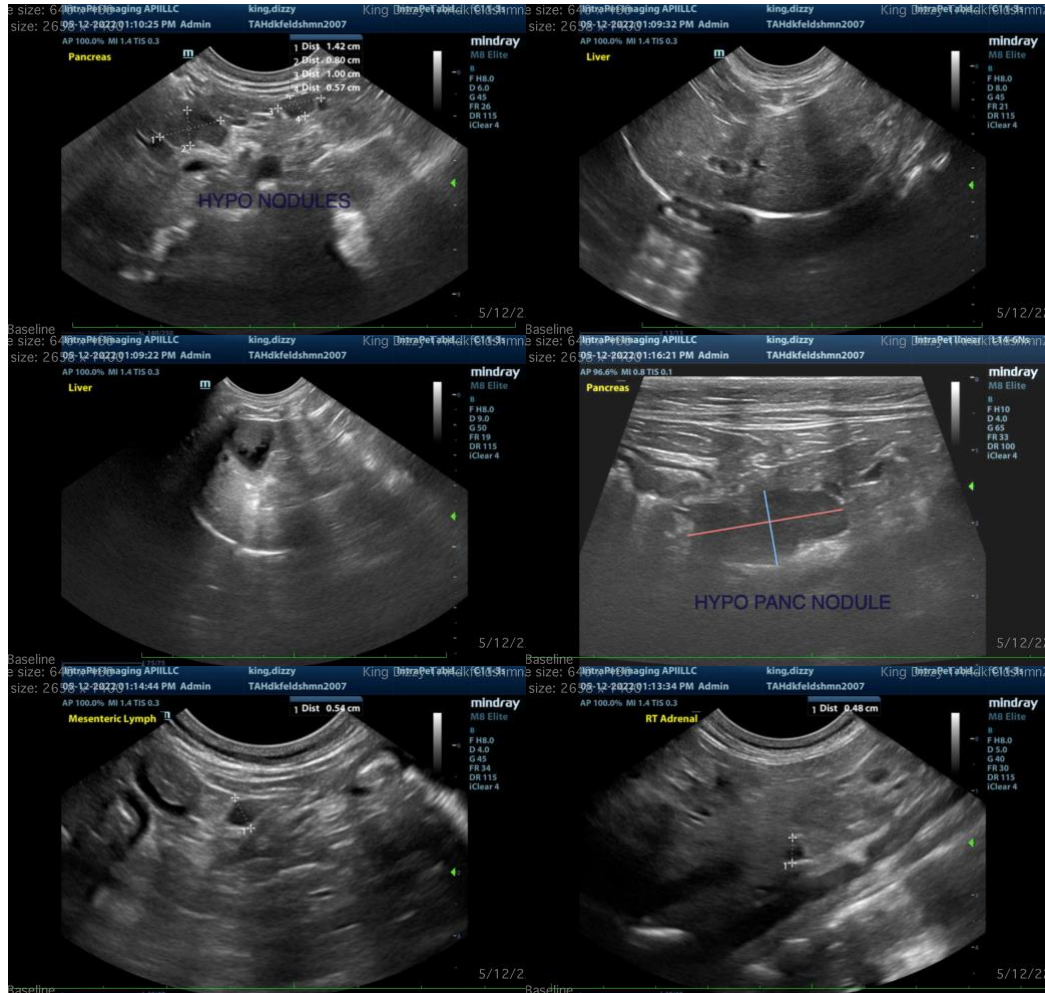
### INTERPRETATION OF THE FINDINGS & FURTHER RECOMMENDATIONS

The pancreas is prominent in this individual and there are focal discrete hypoechoic nodules within the pancreas. These could represent large benign nodules, but there is concern for an underlying neoplastic process given the pet's current illness. I recommend a fine needle aspirate of the large pancreatic nodule on the left side. Additionally, the liver is somewhat heterogeneous. If liver enzyme elevations are not present, then this could be an incidental/age-related finding. If they are elevated, consider a fine needle aspirate of the liver and a liver function test.

If the hepatic and pancreatic changes are thought to be less significant, then I would recommend further evaluation for the upper airway changes, such as titrating for cryptosporidiosis and advanced imaging of the head and nasal cavity.

Consider three view thoracic radiographs to rule out concurrent thoracic disease/involvement.





The information and recommendations provided are based on the images presented by the referring veterinarian. No evaluation can be communicated regarding pathology that was not visible in the image/video clips provided.

Thank you for this referral. If the clinical or image interpretation does not parallel your findings or if I can be of any further assistance please contact me.

Kathleen Sennello DVM,MS, Diplomate ACVIM (Small animal Internal Medicine)  
 kathleen.sennello@sonopath.com