

**DATE PRESENTING CLINICAL SIGNS**

5/11/22

Owner brought patient in for moving more slowly overall. She has also noted increased sensitivity on her sides and that she'd been gaining weight. Very slow going up and down stairs for the last month. Has always been a picky eater; sometimes only eats once a day -- no change

PATIENT

Sophia Dwyer

On exam, patient was very tense on abdominal palpation. She had moderate to marked tartar. She was resistant to hip extension bilaterally, with cranial drawer movement in her left stifle. She had a BCS of 4/5

SPECIES

Canine

Current Medications: Simparica Trio long term.

Lab Results: CBC: WNL. Chem: Elevated Chol 855 mg/dL. T4: Low at 0.5, Spec cPL: WNL.

Radiographs: Liver margin appears plump, irregular. Possible increase in soft tissue bulk in mid abdomen dorsal to spleen. Nodularity present in lungs on V/D view; difficult to discern if artifact vs. true nodularity.

BREED

Beagle

Cranial displacement of tibia noted in left stifle

Date of Previous IntraPet Ultrasound: No previous.

Sedation: Not required to complete full diagnostic ultrasound.

Stat Report: Not requested.

SEX

Spayed Female

ULTRASONOGRAPHIC EXAMINATION OF THE ABDOMEN**AGE**

9/15/15

Urinary System

The urinary bladder is moderately distended with anechoic urine. The Bladder wall, trigone, ureteral papillae and visible urethra (to a depth of 2cm) appear normal with no evidence of wall thickening, mucosal irregularities, masses or cystic calculi.

WEIGHT

30 Pounds

The left kidney has a normal shape and size (4.96 cm). Overall echogenicity is normal with adequate corticomedullary distinction and a typical 1:3 cortex:medulla ratio. There is no evidence of perinephric inflammation or effusion. There is no evidence of pyelectasia, nephroliths, infarcts or hydroureter. Renal vasculature is normal.

INTERPRETED BY

Kathleen Sennello DVM,
MS, Diplomate ACVIM
(Small Animal Internal
Medicine)

The right kidney has a normal shape and size (4.79 cm). Overall echogenicity is normal with adequate corticomedullary distinction and a typical 1:3 cortex:medulla ratio. There is no evidence of perinephric inflammation or effusion. There is no evidence of pyelectasia, nephroliths, infarcts or hydroureter. Renal vasculature is normal.

IMAGING PERFORMED BY

Andi Parkinson RDMS

Adrenal Glands

The left adrenal gland is normal in size measuring 0.57 cm at the caudal pole. It is observed in its normal position cranial to the left renal artery. It is normal in appearance (uniformly hypoechoic) and shape with no evidence of a mass effect.

HOSPITAL NAME

Paradise Animal
Hospital

The right adrenal gland is normal in size measuring 0.59 cm at the caudal pole. It is observed in its normal position between the cranial aspect of the right kidney and the caudal vena cava. It is normal in appearance (uniformly hypoechoic) and shape with no evidence of a mass effect.

REFERRING VET

Dr. Twardzik

Spleen

The spleen is subjectively normal in size, echotexture is homogenous, and the splenic capsule is smooth with no irregularities. The blood flow through the hilus and splenic parenchyma appears normal. No focal parenchymal abnormalities are visualized.

INVOICE

37612

Liver

The liver is mildly large in size with smooth peripheral margins. The parenchyma is hyperechoic and homogenous in echotexture. The visible portions of the vasculature and biliary tract appear normal. No focal nodules or cystic lesions are observed.

The gall bladder lumen is moderately distended. The wall of the gall bladder is not thickened and has a smooth mucosal surface. There is a moderate amount of mildly shadowing debris, likely with some sand/mineralization. The cystic and common bile ducts are normal/not visible.

Gastrointestinal

The stomach contains minimal luminal contents. It measures at a normal thickness of <0.7cm with some variability due to the presence of rugal folds. The distinction of the gastric wall layers is adequate and there is no impression of reduced peristaltic activity. No masses or focal lesions were observed.

The visualized areas of duodenum, jejunum and ileum have a relatively uniform diameter with minimal fluid distension. Wall thickness is normal. Bowel loops follow a curvilinear path with distinct wall layering maintaining the typical 1:3 muscularis:mucosa layer ratio. Duodenum wall measured 0.40 cm. Jejunum wall measured 0.37 cm. Visualized peristalsis appears appropriate. There were no focal lesions consistent with obstruction or a mass effect observed.

The ileocecal junction was visualized and exhibited normal intact wall layering and is subjectively of normal thickness. Sections of colon are visualized with formed fecal material and gas shadowing distally. There is no observed focal or generalized colon wall thickening or loss of layering.

Pancreas

The pancreas is normal and isoechoic to surrounding mesentery. There is no evidence of nodules or cystic lesions. There is no evidence of regional mesenteric inflammation or fluid.

Free Abdomen

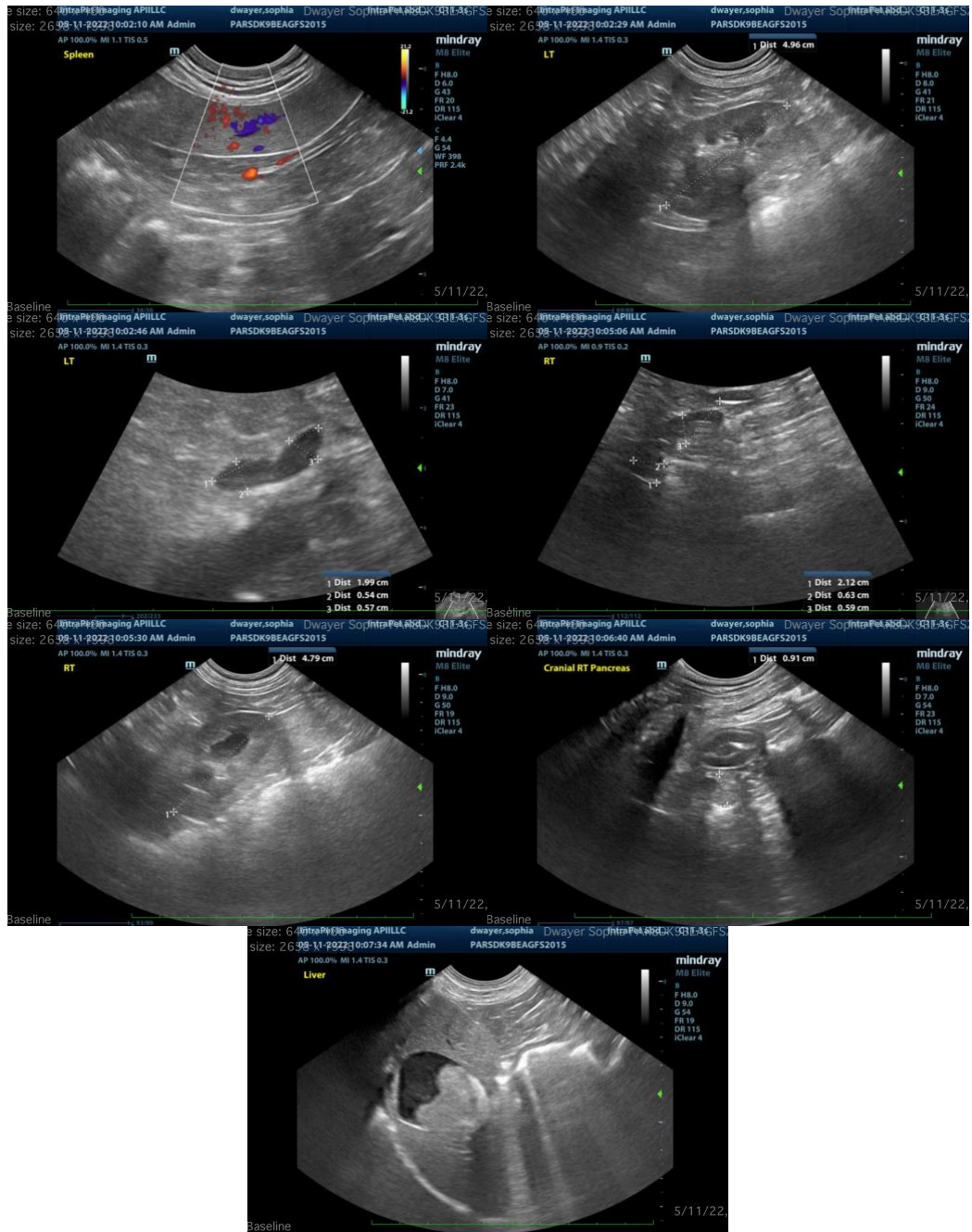
Evaluation of the peritoneal cavity did not reveal any evidence of effusion, or subjective lymphadenomegaly. The Medial iliac nodes appear normal and there was no evidence of a caudal aortic thrombus at the bifurcation. The omentum is of normal uniform echogenicity.

ULTRASONOGRAPHIC FINDINGS

- Large, hyperechoic liver – The diffuse hepatic changes are non-specific and can be seen with vacuolar hepatopathy, reactive change, nodular hyperplasia or, less likely, inflammatory/immune-mediated disease, infiltrative neoplasia, or other hepatopathy.
- Moderate shadowing sandy debris within the gallbladder – The significance of the aggregated gallbladder sludge is unclear. This could represent an early mucocele, cholestasis, or may be secondary to fasting.

INTERPRETATION OF THE FINDINGS & FURTHER RECOMMENDATIONS

The changes observed on today's scan were subjective and relatively mild. An obvious cause for the recent lethargy reported is not observed. Consider other possibilities such as malaise due to tick borne disease, polyarthritis, osteoarthritis, etc., and consider thyroid supplementation if this clinically fits with hypothyroidism.



The information and recommendations provided are based on the images presented by the referring veterinarian/sonographer. No evaluation can be communicated regarding pathology that was not visible in the image/video clips provided.

Thank you for this referral. If the clinical or image interpretation does not parallel your findings or if I can be of any further assistance please contact me.

Kathleen Sennello DVM,MS, Diplomate ACVIM (Small animal Internal Medicine)

kathleen.sennello@sonopath.com