



PATIENT

Murphy Hayden

SPECIES

Canine

BREED

Labrador/Collie

SEX

Spayed Female

AGE

10.5 Years

WEIGHT

62.5 Pounds

INTERPRETED BY

Kathleen Sennello DVM,
MS, Diplomate ACVIM
(Small Animal Internal
Medicine)

IMAGING PERFORMED BY

Kelly Vazquez

HOSPITAL NAME

Glen Rock VH

REFERRING VET

Dr. Scott Stekler

INVOICE

47308

DATE

5/10/23

PRESENTING CLINICAL SIGNS

Patient with history of diabetes mellitus presents for decreased appetite, lethargy, and episodes of anorexia. Waxing and waning anemia. HCT was 26 on 5/8/23, partially corrected itself after 2 days of no treatment. HCT 39. Current med: Novulin N BID.

Abnormal PE/Chem/CBC/UA Results: SAP and glucose have been elevated.

ULTRASONOGRAPHIC EXAMINATION OF THE ABDOMEN

Urinary System

The urinary bladder is moderately distended with anechoic urine. The Bladder wall, trigone, ureteral papillae and visible urethra (to a depth of 2cm) appear normal with no evidence of wall thickening, mucosal irregularities, masses or cystic calculi.

The left kidney has a normal shape and size (7.69 cm). Overall echogenicity is normal with adequate corticomedullary distinction and a typical 1:3 cortex:medulla ratio. There is no evidence of focal perinephric inflammation or effusion. There is no evidence of pyelectasia, nephroliths, infarcts or hydroureter. Renal vasculature is normal.

The right kidney has a normal shape and size (6.45 cm). Overall echogenicity is normal with adequate corticomedullary distinction and a typical 1:3 cortex:medulla ratio. There is no evidence of focal perinephric inflammation or effusion. There is no evidence of pyelectasia, nephroliths, infarcts or hydroureter. Renal vasculature is normal.

Adrenal Glands

The region of left adrenal (Cranial to left renal artery) is unremarkable but the adrenal is not distinctly visualized. No evidence of a mass effect is visualized.

The region of the right adrenal (between right cranial kidney and vena cava) is unremarkable, but the adrenal is not distinctly visualized. No evidence of a mass effect is visualized.

Spleen

The spleen is subjectively normal in size bur irregular in shape. The blood flow through the hilus and splenic parenchyma appears normal. There is a focal heterogeneous mass effect visualized towards the tail of the spleen measuring 3.47 cm x 4.29 cm. Free fluid and irregular mesentery surrounds this mass effect.

Liver

The liver is large in size, and normal in echogenicity with smooth peripheral margins. The parenchyma is heterogenous in echotexture with subtle, indistinct focal mottling. The visible portions of the vasculature and biliary tract appear normal. No focal nodules or cystic lesions are observed.

The gallbladder lumen is moderately distended. The wall of the gall bladder is not thickened and has a smooth mucosal surface. Luminal contents are mild and primarily anechoic. The cystic and common bile ducts are normal/not visible.

Gastrointestinal

The stomach contains moderate ingesta. It measures at a normal thickness of <0.7cm with some variability due to the presence of rugal folds. The distinction of the gastric wall layers is adequate and there is no impression of reduced peristaltic activity. No masses or focal lesions were observed.



PATIENT

Murphy Hayden

SPECIES

Canine

BREED

Labrador/Collie

SEX

Spayed Female

AGE

10.5 Years

WEIGHT

62.5 Pounds

INTERPRETED BY

Kathleen Sennello DVM,
MS, Diplomate ACVIM
(Small Animal Internal
Medicine)

**IMAGING
PERFORMED BY**

Kelly Vazquez

HOSPITAL NAME

Glen Rock VH

REFERRING VET

Dr. Scott Stekler

INVOICE

47308

DATE

5/10/23

The visualized areas of duodenum, jejunum and ileum have a relatively uniform diameter with minimal fluid distension. Wall thickness is normal. Bowel loops follow a curvilinear path with distinct wall layering maintaining the typical 1:3 muscularis:mucosa layer ratio. The duodenum measured as normal (between 0.3-0.5cm in wall thickness) and the jejunum measured as normal (between 0.2-0.47cm.) Visualized peristalsis appears appropriate. There were no focal lesions consistent with obstruction or a mass effect observed.

The ileocecal junction was visualized and exhibited normal intact wall layering and is subjectively of normal thickness. Sections of colon are visualized with formed fecal material and gas shadowing distally. There is no observed focal or generalized colon wall thickening or loss of layering.

Pancreas

The area of the pancreas is normal and isoechoic to surrounding mesentery. There is no evidence of nodules or cystic lesions. There is no evidence of regional mesenteric inflammation or fluid.

Free Abdomen

There is a large volume of echogenic free fluid. No lymphadenopathy. The omentum is hyperechoic around the splenic mass lesion.

Other

The right auricle and pericardium were visualized and were unremarkable. No obvious pathology is visualized. If cardiac function evaluation is desired a full echocardiogram is warranted.

ULTRASONOGRAPHIC FINDINGS

- Mixed echogenic solid splenic mass – A focal solid mixed echogenicity mass is visualized associate with the spleen. This mass distorts the splenic capsule. Differentials include : benign lesions (lymphoid hyperplasia, hemangioma etc..) or cancerous lesions (hemangiosarcoma, lymphoma, histiocytic sarcoma etc..)
- Large, heterogeneous liver – The diffuse hepatic changes are non-specific and could be consistent with vacuolar hepatopathy, nodular hyperplasia, inflammatory/immune-mediated disease, fibrosis, extramedullary hematopoiesis, toxic hepatopathy (e.g., copper), infiltrative neoplasia (less likely) or other hepatopathy.
- Large volume free echogenic fluid – Findings are suspicious for hemoabdomen. Recommend sampling, fluid analysis +/- cytology.

INTERPRETATION OF THE FINDINGS & FURTHER RECOMMENDATIONS

There is a mixed echogenic mass effect towards the tail of the spleen, which does not appear overtly cavitated but is irregular with surrounding fluid and inflammation. Findings are concerning for a ruptured splenic mass lesion. Recommend sampling abdominal fluid for fluid analysis +/- cytology. If a hemoabdomen is present, consider splenectomy for both diagnostic and therapeutic purposes.

Recommend three view thoracic radiographs to evaluate for possible concurrent thoracic disease/involvement.



PATIENT

Murphy Hayden

SPECIES

Canine

BREED

Labrador/Collie

SEX

Spayed Female

AGE

10.5 Years

WEIGHT

62.5 Pounds

INTERPRETED BY

Kathleen Sennello DVM,
MS, Diplomate ACVIM
(Small Animal Internal
Medicine)

**IMAGING
PERFORMED BY**

Kelly Vazquez

HOSPITAL NAME

Glen Rock VH

REFERRING VET

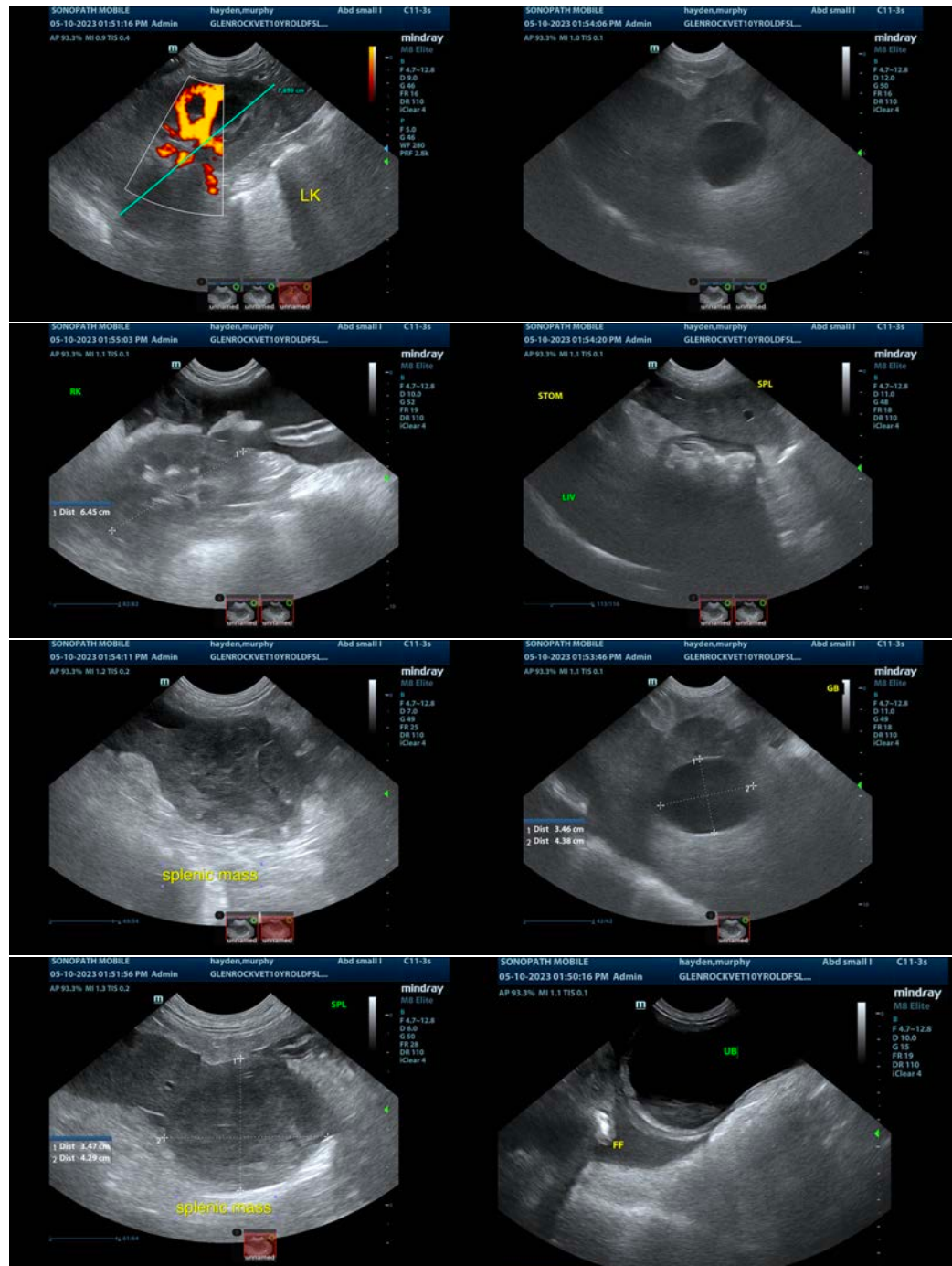
Dr. Scott Stekler

INVOICE

47308

DATE

5/10/23



The information and recommendations provided are based on the images presented by the referring veterinarian/sonographer. No evaluation can be communicated regarding pathology that was not visible in the image/video clips provided.

Thank you for this referral. If the clinical or image interpretation does not parallel your findings or if I can be of any further assistance please contact me.

Kathleen Sennello DVM,MS, Diplomate ACVIM (Small animal Internal Medicine)

kathleen.sennello@sonopath.com