

**DATE PRESENTING CLINICAL SIGNS**

5/10/23 P presented with mass; cytology findings consistent with a MCT. Pursuing tumor removal and biopsy. Performing ultrasound as part of a presx workup. Since ALP also a little up, would like a comment on adrenal size

PATIENT

Kimber Grimes Current Medications: Sentinel 51-100lbs: po q30 days year-round (started 4/2023). OTC Flea/Tick Prevention year-round.

SPECIES

Canine

Lab Results: Increased ALP. No other findings to note. Unsure if chest rads will be done prior

Date of Previous IntraPet Ultrasound: No previous.

Sedation: Not required to complete full diagnostic ultrasound.

Stat Report: Not requested.

BREED

Pit Bull X

Imaging Performed By: Stephanie Warga RDCS, RVT.

ULTRASONOGRAPHIC EXAMINATION OF THE ABDOMEN**SEX**

Intact Female

Urinary System

The urinary bladder is moderately distended with anechoic urine. The Bladder wall, trigone, ureteral papillae and visible urethra (to a depth of 2cm) appear normal with no evidence of wall thickening, mucosal irregularities, masses or cystic calculi.

AGE

10/20/16

The left kidney has a normal shape and size (6.87 cm). Overall echogenicity is normal with adequate corticomedullary distinction and a typical 1:3 cortex:medulla ratio. There is no evidence of focal perinephric inflammation or effusion. There is no evidence of pyelectasia, nephroliths, infarcts or hydroureter. Renal vasculature is normal.

WEIGHT

88 Pounds

The right kidney has a normal shape and size (7.15 cm). Overall echogenicity is normal with adequate corticomedullary distinction and a typical 1:3 cortex:medulla ratio. There is no evidence of focal perinephric inflammation or effusion. There is no evidence of pyelectasia, nephroliths, infarcts or hydroureter. Renal vasculature is normal.

INTERPRETED BY

Kathleen Sennello DVM,
MS, Diplomate ACVIM
(Small Animal Internal
Medicine)

Adrenal Glands

The left adrenal gland is normal in size measuring 0.54 cm at the caudal pole. It is observed in its normal position cranial to the left renal artery. It is normal in appearance (uniformly hypoechoic) and shape with no evidence of a mass effect.

HOSPITAL NAME

Rolling Hills AH

The right adrenal gland is normal in size measuring 0.51 cm at the caudal pole. It is observed in its normal position between the cranial aspect of the right kidney and the caudal vena cava. It is normal in appearance (uniformly hypoechoic) and shape with no evidence of a mass effect.

REFERRING VET

Dr. Gividen

Spleen

The spleen is subjectively normal in size, echotexture is homogenous, and the splenic capsule is smooth with no irregularities. The blood flow through the hilus and splenic parenchyma appears normal. No focal parenchymal abnormalities are visualized.

INVOICE

47298

Liver

The liver is subjectively normal in size, and echogenicity with smooth peripheral margins. The parenchyma is homogenous echotexture. The visible portions of the vasculature and biliary tract appear normal. No focal nodules or cystic lesions are observed.

The gallbladder lumen is moderately distended. The wall of the gall bladder is not thickened and has a smooth mucosal surface. Luminal contents are mild and primarily anechoic. The cystic and common bile ducts are normal/not visible.

Gastrointestinal

The stomach contains minimal luminal contents. It largely measures at a normal thickness of <0.7cm with some variability due to the presence of rugal folds, but there are some areas that appear slightly hypoechoic and measure up to 1.2 cm in thickness. Overall, the distinction of the gastric wall layers is adequate and there is no impression of reduced peristaltic activity. I suspect the thickening is artifactual, but recheck evaluation is warranted.

The visualized areas of duodenum, jejunum and ileum have a relatively uniform diameter with minimal fluid distension. Wall thickness is normal. Bowel loops follow a curvilinear path with distinct wall layering maintaining the typical 1:3 muscularis:mucosa layer ratio. Jejunum wall measures 0.22 cm. Visualized peristalsis appears appropriate. There were no focal lesions consistent with obstruction or a mass effect observed.

The ileocecal junction was visualized and exhibited normal intact wall layering and is subjectively of normal thickness. Sections of colon are visualized with formed fecal material and gas shadowing distally. There is no observed focal or generalized colon wall thickening or loss of layering.

Pancreas

The area of the pancreas is normal and isoechoic to surrounding mesentery. There is no evidence of nodules or cystic lesions. There is no evidence of regional mesenteric inflammation or fluid.

Free Abdomen

Evaluation of the peritoneal cavity did not reveal any evidence of effusion. There are normal mesenteric lymph nodes visualized measuring 0.55 cm and 0.42 cm. The mesentery is of normal echogenicity.

Other

Both the left and right ovaries are visualized, measuring 1.66 cm on the left and 1.92 cm on the right. Additionally, the uterine body is visualized and appears normal.

PRIMARY FINDINGS

- Thickened gastric wall – The stomach wall thickening could be consistent with inflammation, edema, infiltrative neoplasia, imaging artifact due to rugal folds, other.

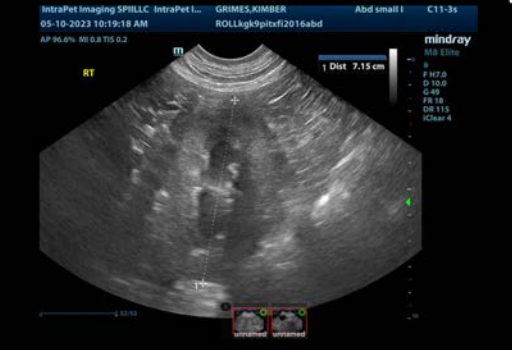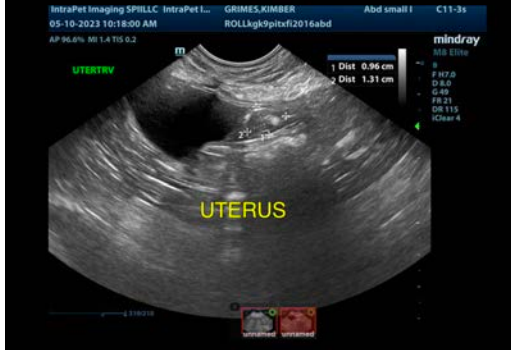
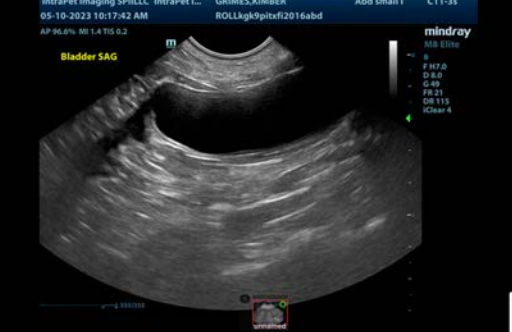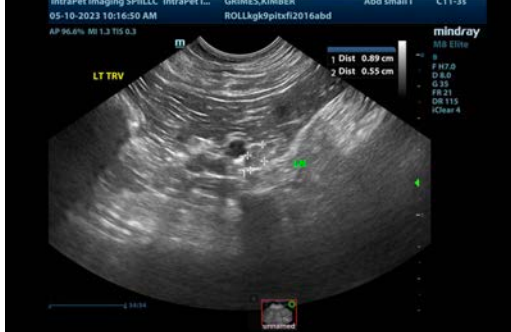
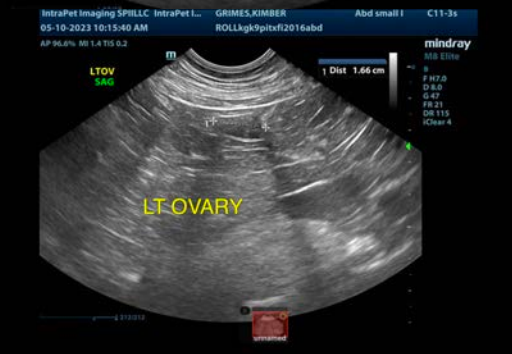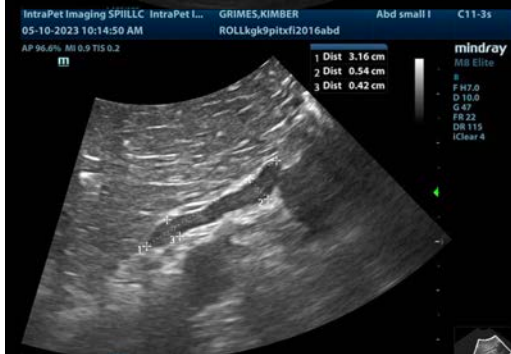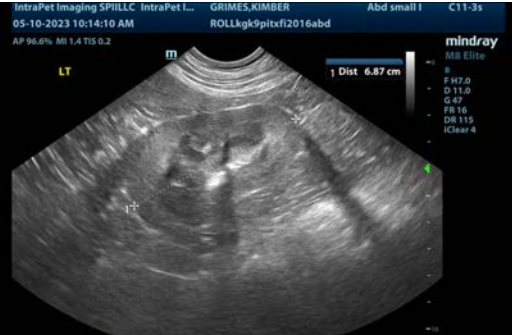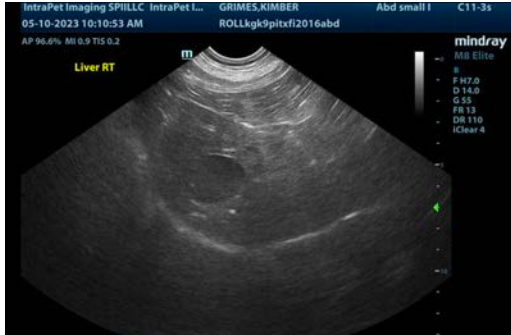SECONDARY FINDINGS

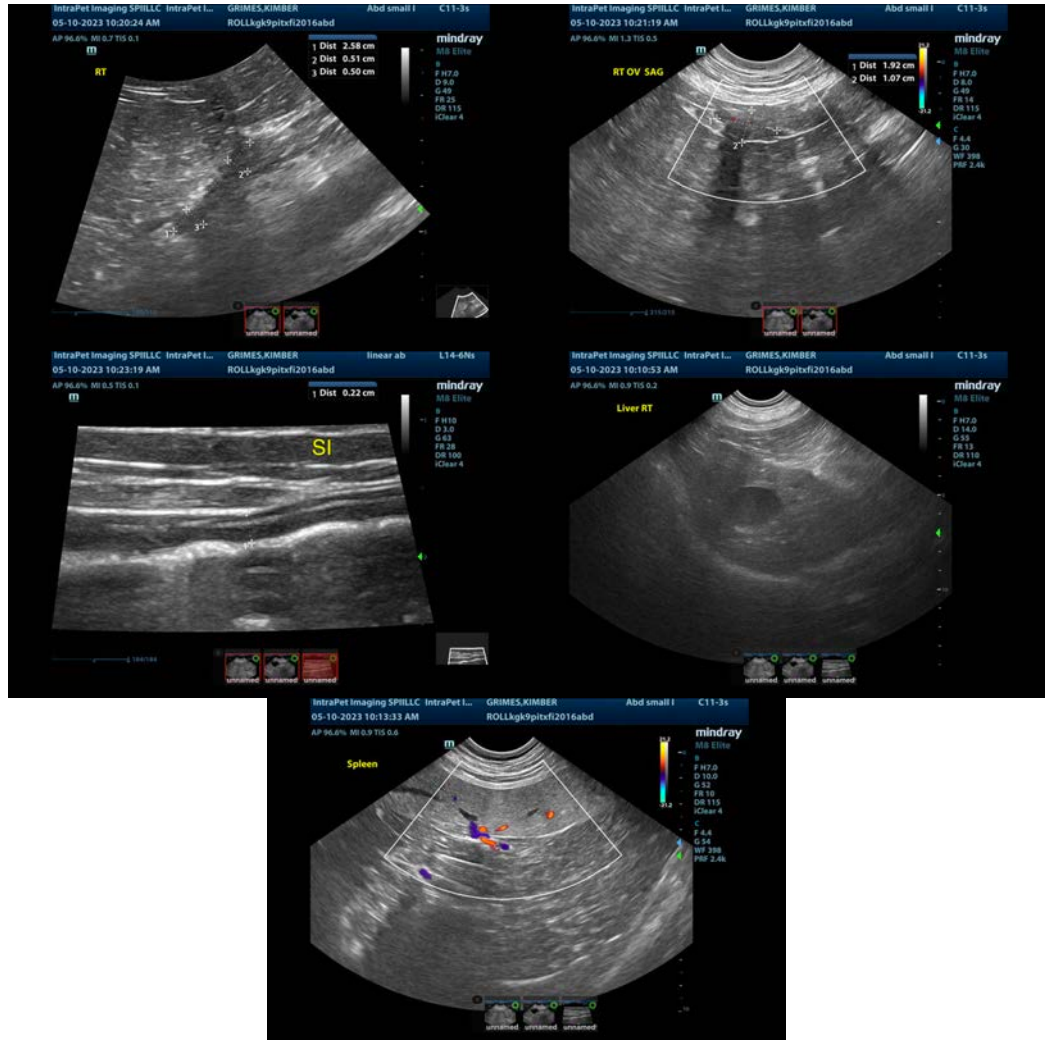
- Normal ovaries and uterine body visualized.

INTERPRETATION OF THE FINDINGS & FURTHER RECOMMENDATIONS

No focal lesions are visualized consistent with metastasis of a mast cell tumor. Unfortunately, there can be spread to the liver and spleen without ultrasonographic changes.

In some views, the gastric wall appears slightly thickened and hypoechoic. I suspect this is artifactual due to rugal folding, but a reevaluation is warranted (recheck in 2-3 months, sooner if not doing well).





The information and recommendations provided are based on the images presented by the referring veterinarian/sonographer. No evaluation can be communicated regarding pathology that was not visible in the image/video clips provided.

Thank you for this referral. If the clinical or image interpretation does not parallel your findings or if I can be of any further assistance please contact me.

Kathleen Sennello DVM,MS, Diplomate ACVIM (Small animal Internal Medicine)
kathleen.sennello@sonopath.com