

**DATE PRESENTING CLINICAL SIGNS**

5/10/22

PATIENT

Ranger Farlow

SPECIES

Canine

BREED

Mastiff X

SEX

Intact Male

AGE

11/2/12

WEIGHT

94.8 Pounds

INTERPRETED BY

Kathleen Sennello DVM,
MS, Diplomate ACVIM
(Small Animal Internal
Medicine)

IMAGING PERFORMED BY

Rachel Brillhart RDMS

HOSPITAL NAME

All Creatures
Veterinary Service

REFERRING VET

Dr. Meadows

INVOICE

37589

Pt has been dealing with on and off diarrhea and vomiting, more so on the diarrhea. O feels like every time Pt eats food with protein in it, it causes vomiting and have diarrhea. Pt acts like he is starving when he does eat. O also mentioned Pt will vomit occasionally after drinking. Pt normally eats Pedigree wet food with either Old Roy dry food or rice when Pt is dealing with diarrhea. O said Pt's stools are finally looking normal, but every time they start to cut back on rice, the diarrhea starts back up again. Urinating normal. No C/S. Energy is low. Pt is on a probiotic and prebiotic but O says they haven't seen much of a difference. Pet was seen by previous vet in January 2022 for diarrhea and labwork was done-- had low albumin at 1.7. Previous labwork to this was done in June of 2021 and albumin was normal at 2.6. On exam (5/2/2022), pet was BAR and vitals were normal. Heart and lungs sounded normal. Abdomen was soft and non-painful. Pet is intact and has enlargement and mass on the right testicle. The prostate is slightly enlarged. Pet is losing weight. I recommended to start by rechecking labwork and put on metro and Proviabile.

Current Medications: Metronidazole 500mg: Give 1T BID for 14 days, Proviabile 1 capsule SID.

Lab Results: -Low albumin at 1.1 (2.7-3.9), Elevated SDMA at 18 (0-14); other renal values normal, USG 1.015, Low calcium 8.3 (8.4-11.8)- suspect from low albumin.

Date of Previous IntraPet Ultrasound: No previous.

Sedation: Not required to complete full diagnostic ultrasound.

Stat Report: Not requested.

ULTRASONOGRAPHIC EXAMINATION OF THE ABDOMEN**Urinary System**

The urinary bladder is moderately distended with anechoic urine. The Bladder wall, trigone, ureteral papillae and visible urethra (to a depth of 2cm) appear normal with no evidence of wall thickening, mucosal irregularities, masses or cystic calculi.

The prostate is large in size (3.79 cm x 4.07 cm) but has a regular shape with smooth external margins. The parenchyma is heterogenous but no discrete focal lesions are present. The prostatic urethra appears normal with no evidence of irregularity, invasion, mass effect or calculi.

The left kidney has a normal shape and size (7.11 cm) with mild pyelectasia at 0.27 cm. Overall echogenicity is slightly hyperechoic with poor corticomedullary distinction and a typical 1:3 cortex:medulla ratio. There is no evidence of perinephric inflammation or effusion. There is no evidence of nephroliths, infarcts or hydroureter. Renal vasculature is normal.

The right kidney has a normal shape and size (7.07 cm) with mild pyelectasia at 0.29 cm. Overall echogenicity is slightly hyperechoic with poor corticomedullary distinction and a typical 1:3 cortex:medulla ratio. There is no evidence of perinephric inflammation or effusion. There is no evidence of nephroliths, infarcts or hydroureter. Renal vasculature is normal.

Adrenal Glands

The left adrenal gland is normal in size measuring 0.96 cm at the caudal pole. It is observed in its normal position cranial to the left renal artery. It is normal in appearance (uniformly hypoechoic) and shape with no evidence of a mass effect.

The right adrenal gland is normal in size measuring 0.85 cm at the caudal pole. It is observed in its normal position between the cranial aspect of the right kidney and the caudal vena cava. It is normal in appearance (uniformly hypoechoic) and shape with no evidence of a mass effect.

Spleen

The spleen is subjectively normal in size, echotexture is homogenous, and the splenic capsule is smooth with no irregularities. The blood flow through the hilus and splenic parenchyma appears normal. No focal parenchymal abnormalities are visualized.

Liver

The liver is subjectively normal in size, and echogenicity with smooth peripheral margins. The parenchyma is homogenous echotexture. The visible portions of the vasculature and biliary tract appear normal. No focal nodules or cystic lesions are observed.

The gallbladder lumen is moderately distended. The wall of the gall bladder is not thickened and has a smooth mucosal surface. Luminal contents are primarily anechoic. The cystic and common bile ducts are normal/not visible.

Gastrointestinal

The stomach is dilated with a large amount of fluid. It measures at a normal thickness of <0.7cm with some variability due to the presence of rugal folds. The distinction of the gastric wall layers is adequate and there is no impression of reduced peristaltic activity. No masses or focal lesions were observed.

The visualized areas of duodenum, jejunum and ileum have a uniform diameter with minimal fluid distension. Wall thickness is increased. Bowel loops follow a typical curvilinear path. Some areas have reduced detail of wall layering. Jejunum wall measured 0.46 cm. Visualized peristalsis appears appropriate. There are some focal areas of small intestine that appear particularly thickened, measuring at 0.61 cm in wall thickness with reduced distinction of wall layering and surrounding hyperechoic mesentery.

The ileocecal junction was visualized and exhibited normal intact wall layering and is subjectively of normal thickness. Sections of colon are visualized with formed fecal material and gas shadowing distally. There is no observed focal or generalized colon wall thickening or loss of layering.

Pancreas

The pancreas is normal and isoechoic to surrounding mesentery. There is no evidence of nodules or cystic lesions. There is no evidence of regional mesenteric inflammation or fluid.

Free Abdomen

Evaluation of the peritoneal cavity did not reveal any evidence of effusion, or subjective lymphadenomegaly. The Medial iliac nodes appear normal and there was no evidence of a caudal aortic thrombus at the bifurcation. The omentum is of normal uniform echogenicity.

Other

Both testicles are imaged. The right testicle is slightly large, measuring 4.1 cm. There are numerous cystic nodules visualized within the parenchyma. The left testicle is somewhat smaller, measuring 3.9 cm with a larger mixed echogenicity nodule measuring 2.38 cm x 1.7 cm.

ULTRASONOGRAPHIC FINDINGS

- Large, hyperechoic, heterogeneous prostate – most consistent with benign prostatic hypertrophy +/- prostatitis.
- Decreased corticomedullary distinction in both kidneys with mild pyelectasia – The bilateral renal findings are consistent with age-related change. Pyelectasia of the left/right kidney could be consistent with pyelonephritis, chronic renal disease, secondary to PU/PD or fluid therapy (if applicable), other.

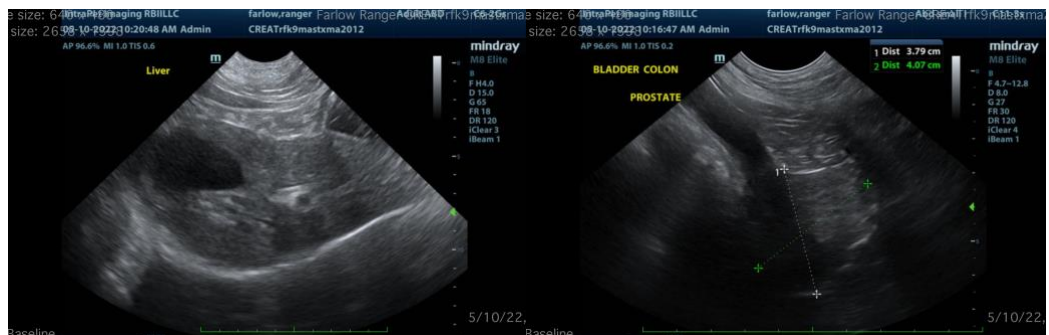
- Fluid distended gastric lumen – correlate with drinking history. Findings are most consistent with delayed gastric emptying or a partial outflow tract obstruction (none observed).
- Thickened small intestine with decreased distinction of layering and surrounding hyperechoic mesentery – findings are concerning for infiltrative bowel disease (IBD, neoplasia, lymphangiectasia, other).
- Nodules visible in both testicles – These could be benign or cancerous nodules.

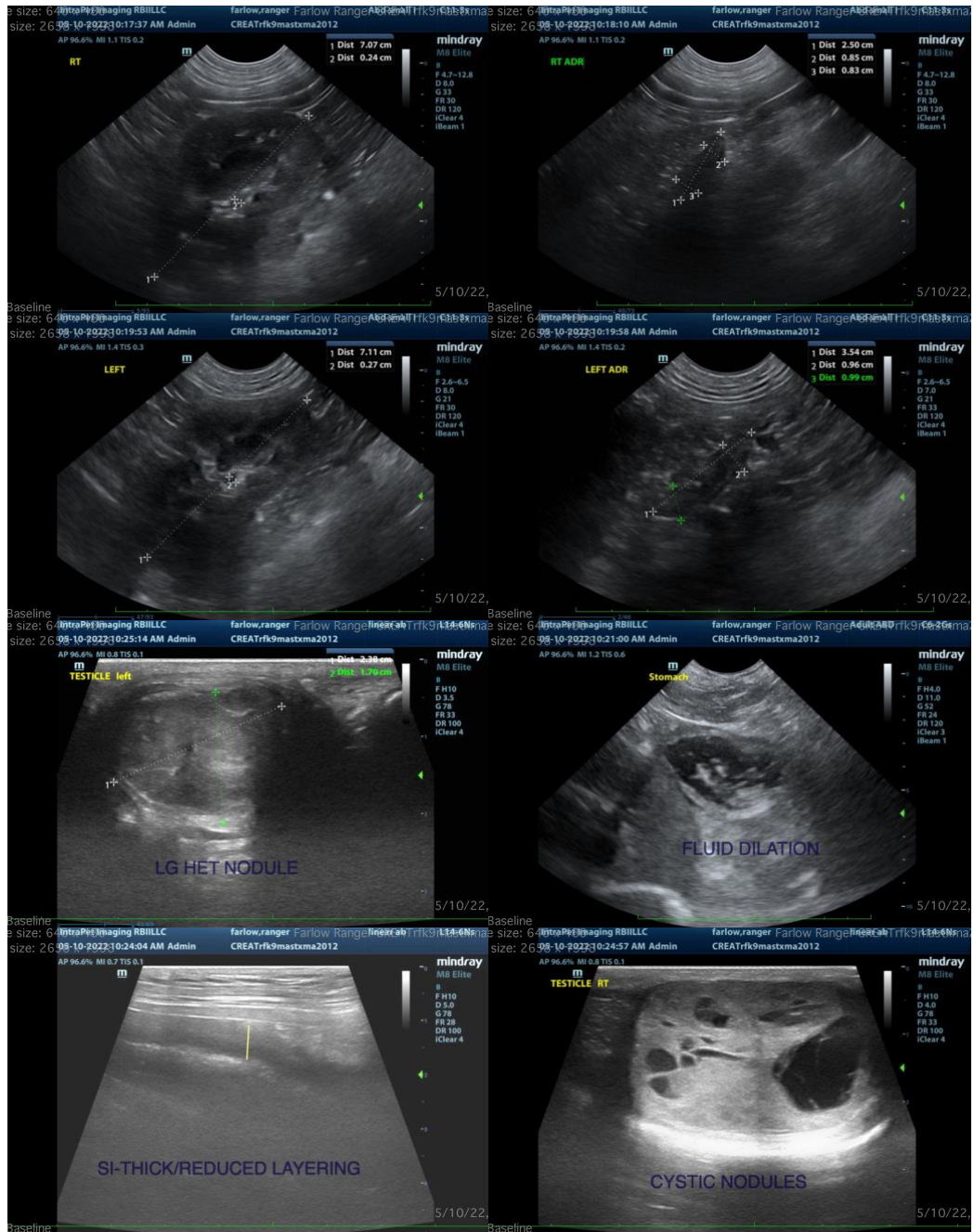
INTERPRETATION OF THE FINDINGS & FURTHER RECOMMENDATIONS

Based on the severe hypoalbuminemia reported, there is the suspicion of a protein losing enteropathy. Recommend a liver function test and urine protein/creatinine ratio along with a urinalysis and culture to rule out concurrent protein loss from the kidneys or liver. Consider a GI panel to Texas A&M for a qualitative PLI, TLI, cobalamin and folate to further evaluate the pancreas and small intestine. If protein loss is ruled out from these other sites, then a protein losing enteropathy is thought very likely. The most common differentials to consider are typically IBD, lymphangiectasia, or intestinal neoplasia (other differentials exist). A biopsy of the small intestine is necessary to differentiate between these processes, which is important to do, because prognosis and treatment recommendations are different for these diseases.

- I suspect the owner is seeing improvement based on an ultra low-fat diet rather than protein content. Consider a prescription low fat diet such as Royal Canin Gastrointestinal low fat, or Hills I/D low fat.
- Recommend continued probiotic therapy.
- Recommend a GI panel (as described above).
- Recommend GI biopsies. In a dog this big, I would recommend upper and lower GI endoscopy.
- Recommend 3-view thoracic radiographs.

Additionally, there are prostatic changes consistent with an intact male dog, and nodules visualized in both testicles. I would likely prioritize the gastrointestinal disease at this time, but neutering should be recommended in the near future.





The information and recommendations provided are based on the images presented by the referring veterinarian/sonographer. No evaluation can be communicated regarding pathology that was not visible in the image/video clips provided.

Thank you for this referral. If the clinical or image interpretation does not parallel your findings or if I can be of any further assistance please contact me.

Kathleen Sennello DVM,MS, Diplomate ACVIM (Small animal Internal Medicine)

kathleen.sennello@sonopath.com