

**DATE**

5/10/22

**PRESENTING CLINICAL SIGNS**

P has hx of fibrosarcoma right side. O interested in sx removal at referral hospital however ALKP is severely elevated. O also reports p is PU/PD.

**PATIENT**

Handsome Mardiney

Current Medications: Denamarin advanced was sent home 2 months ago but O has not been consistent.

Otherwise no other medications.

Lab Results: ALKP 2282, ALT 163. Spindle cell tumor on right flank.

Date of Previous IntraPet Ultrasound: No previous.

Sedation: Not required to complete full diagnostic ultrasound.

Stat Report: Not requested.

Imaging Performed By: Andi Parkinson, RDMS.

**SPECIES**

Canine

**BREED**

Dachshund

**SEX**

Neutered male

**AGE**

5/20/09

**WEIGHT**

20 lbs

**INTERPRETED BY**

Kathleen Sennello  
DVM, MS, Diplomate  
ACVIM (Small Animal  
Internal Medicine)

**HOSPITAL NAME**

Banfield Timonium

**REFERRING VET**

Dr. Adu

**INVOICE**

30223

**ULTRASONOGRAPHIC EXAMINATION OF THE ABDOMEN****Urinary System**

The urinary bladder is moderately distended with anechoic urine. The bladder wall appears slightly prominent and thickened at a thickness of 0.28 cm with a smooth mucosal surface. The trigone, ureteral papillae and visible urethra (to a depth of 2cm) appear normal with no evidence of wall thickening, mucosal irregularities, masses or cystic calculi. The findings are most consistent with lack of urine distension or mild cystitis.

The visualized areas of prostate and surrounding tissue appear normal. Unfortunately, the prostate is not fully visualized likely due to its intrapelvic location. Correlate with rectal exam findings.

The left kidney has a normal shape and size (5.37 cm). Overall echogenicity is normal with adequate corticomedullary distinction and a typical 1:3 cortex:medulla ratio. There is no evidence of perinephric inflammation or effusion. There is no evidence of pyelectasia, nephroliths, infarcts or hydroureter. Renal vasculature is normal.

The right kidney has a normal shape and size (5.56 cm). Overall echogenicity is normal with adequate corticomedullary distinction and a typical 1:3 cortex:medulla ratio. There is no evidence of perinephric inflammation or effusion. There is no evidence of pyelectasia, nephroliths, infarcts or hydroureter. Renal vasculature is normal.

**Adrenal Glands**

The left adrenal gland is normal/borderline large in size measuring 0.91 cm at the caudal pole. It is observed in its normal position cranial to the left renal artery. It is normal in appearance (uniformly hypoechoic) and shape with no evidence of a mass effect.

The right adrenal gland is normal/borderline large in size measuring 0.71 cm at the caudal pole It is observed in its normal position between the cranial aspect of the right kidney and the caudal vena cava. It is normal in appearance (uniformly hypoechoic) and shape with no evidence of a mass effect.

**Spleen**

The spleen is subjectively normal in size, echotexture is homogenous, and the splenic capsule is smooth with no irregularities. The blood flow through the hilus and splenic parenchyma appears normal. No focal parenchymal abnormalities are visualized.

**Liver**

The liver is subjectively large in size with normal echogenicity with smooth peripheral margins. The parenchyma is heterogenous in echotexture with subtle, indistinct focal mottling. The visible portions of the

vasculature and biliary tract appear normal. There are numerous, ill-defined, hypoechoic nodules throughout the parenchyma measuring 0.68 cm, 0.71 cm and 0.54 cm. The gallbladder lumen is moderately distended. The wall of the gallbladder is not thickened and has a smooth mucosal surface. There is a moderate amount of non-organized echogenic debris. The cystic and common bile ducts are normal/not visible.

### **Gastrointestinal**

The stomach contains minimal luminal contents. It measures at a normal thickness of <0.7cm with some variability due to the presence of rugal folds. The distinction of the gastric wall layers is adequate and there is no impression of reduced peristaltic activity. No masses or focal lesions were observed.

The visualized areas of duodenum, jejunum and ileum have a uniform diameter with minimal fluid distension. Wall appears subjectively, mildly increased. Bowel loops follow a typical curvilinear path with distinct wall layering. The duodenum measures 0.47 cm and the jejunum measures 0.39 cm and there is mild speckling and striations visualized in the duodenum. Visualized peristalsis appears appropriate. There were no focal lesions consistent with obstruction or a mass effect observed.

The ileocecal junction was visualized and exhibited normal intact wall layering and is subjectively of normal thickness. Sections of colon are visualized with formed fecal material and gas shadowing distally. There is no observed focal or generalized colon wall thickening or loss of layering.

### **Pancreas**

The pancreas is normal and isoechoic to surrounding mesentery. There is no evidence of nodules or cystic lesions. There is no evidence of regional mesenteric inflammation or fluid.

### **Free Abdomen**

Evaluation of the peritoneal cavity did not reveal any evidence of effusion, or subjective lymphadenomegaly. The Medial iliac nodes appear normal and there was no evidence of a caudal aortic thrombus at the bifurcation. The omentum is of normal uniform echogenicity.

## **ULTRASONOGRAPHIC FINDINGS**

### **PRIMARY FINDINGS:**

- Large, heterogenous, hyperechoic liver with ill-defined, hypoechoic nodules. The diffuse hepatic changes are non-specific and could be consistent with vacuolar hepatopathy, nodular hyperplasia, inflammatory/immune-mediated disease, fibrosis, extramedullary hematopoiesis, toxic hepatopathy (e.g., copper), infiltrative neoplasia (less likely) or other hepatopathy.
- Borderline bilateral adrenomegaly. The bilateral adrenomegaly could be consistent with bilateral hyperplasia (e.g., secondary to pituitary-dependent hyperadrenocorticism), bilateral infiltrative neoplasia, inflammatory adrenal disease, other. Correlation with clinical findings is recommended.
- Subjectively thickened small intestine with mild mucosal striations. The mild small intestinal wall changes may be a normal variant in this patient or could be consistent with an inflammatory process (e.g., inflammatory bowel disease).

### **SECONDARY FINDINGS:**

- Subjectively thickened urinary bladder wall. The bladder wall changes could be consistent with cystitis or artifactual due to lack of adequate luminal distension. Bladder neoplasia cannot be ruled out but is considered unlikely in this patient.

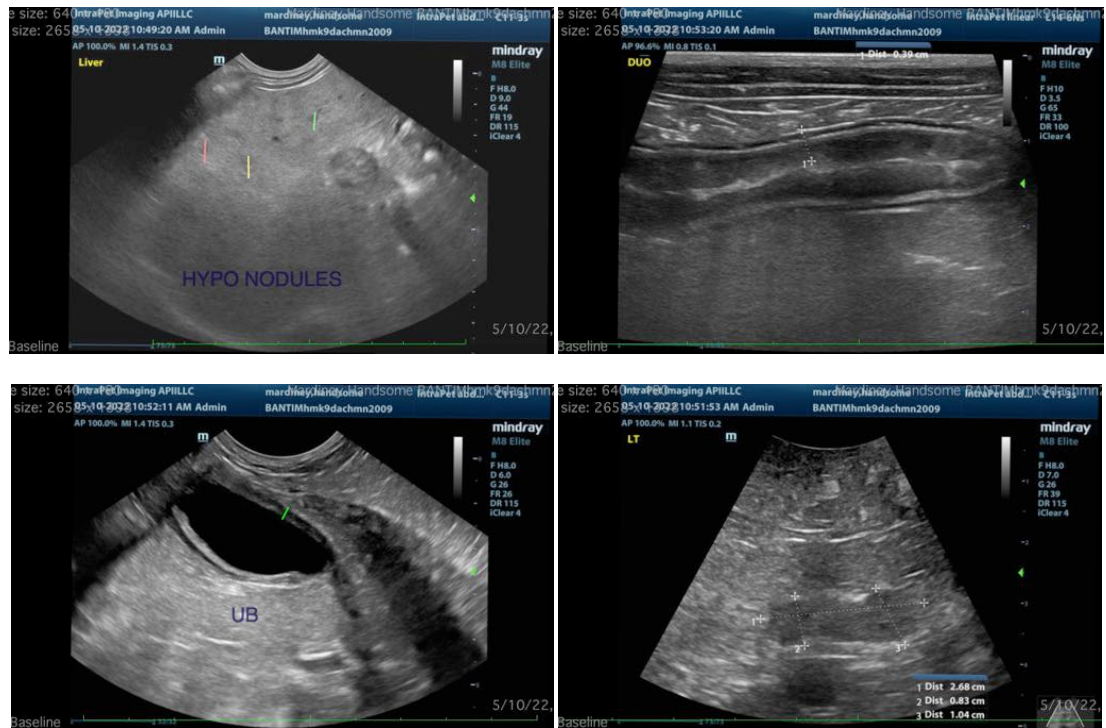- Mild gallbladder sludge. This is likely an incidental finding.

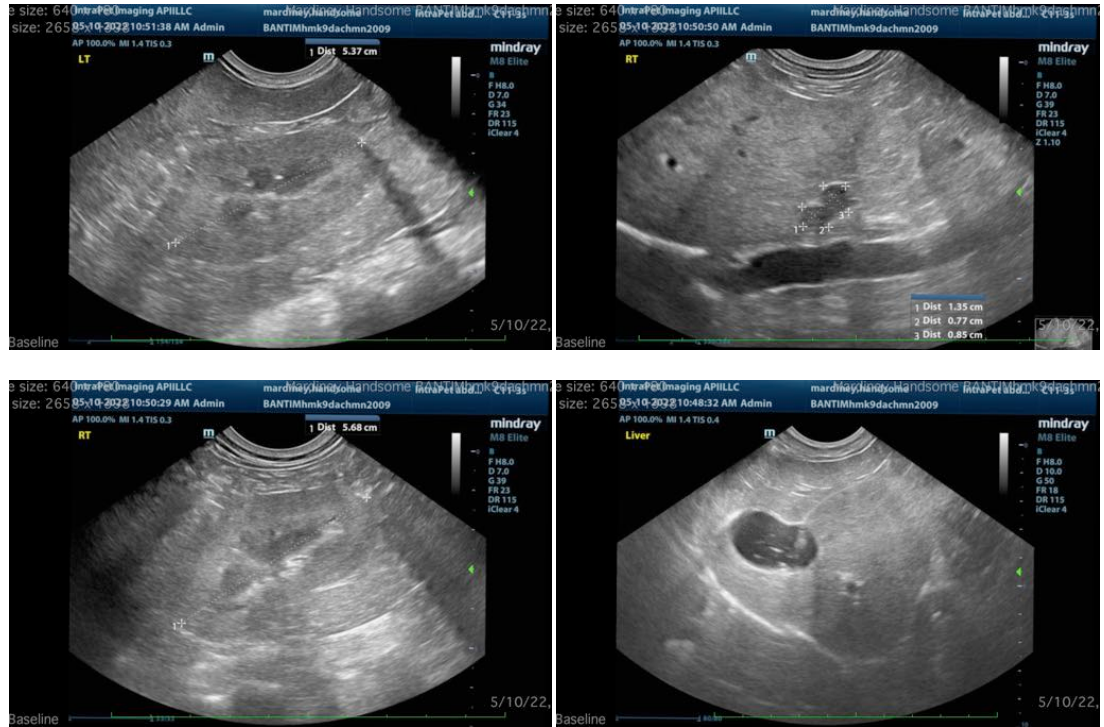
### INTERPRETATION OF THE FINDINGS & FURTHER RECOMMENDATIONS

The liver is large and heterogenous with ill-defined, hypoechoic nodules. The nodules are poorly defined and most consistent with a benign process although nodular neoplastic condition cannot be completely excluded. Additionally, the adrenal glands are somewhat “plump” which could be normal for this individual or consistent with pituitary dependent hyperadrenocorticism.

- Recommend urinalysis and culture due to the PU/PD and mildly prominent urinary bladder wall.
- Consider liver function test.
- If signs of Cushing’s are present (which I suspect they are) consider adrenal function testing.
- If round cell neoplasia is suspected for any reason consider a FNA of the liver.

The small intestine appears subjectively thickened with some mild striations. This could be an indicator of small intestinal disease, although if there are no symptoms associated with intestinal disease I would recommend to continue monitoring.





The information and recommendations provided are based on the images presented by the referring veterinarian. No evaluation can be communicated regarding pathology that was not visible in the image/video clips provided.

Thank you for this referral. If the clinical or image interpretation does not parallel your findings or if I can be of any further assistance please contact me.

Kathleen Sennello DVM,MS, Diplomate ACVIM (Small animal Internal Medicine)  
kathleen.sennello@sonopath.com