

**PATIENT**

Clyde Biber

**SPECIES**

Canine

**BREED**

Coon Hound Mix

**SEX**

43lbs

**AGE**

16-year-old

**WEIGHT**

43lbs

**INTERPRETED BY**

Kathleen Sennello DVM,  
MS, Diplomate ACVIM  
(Small Animal Internal  
Medicine)

**IMAGING PERFORMED BY**

Kelly Vazquez

**HOSPITAL NAME**

Animal General on  
Hudson

**REFERRING VET**

Dr. Karen Zelinski

**INVOICE**

10205

**DATE**

5/10/2023

**PRESENTING CLINICAL SIGNS**

Patient with history of degenerative myelopathy presents for recheck ultrasound and FNA of spleen. Abdominal ultrasound performed on 4/19/23 - has adrenal mass; not addressing that now.

Abnormal PE/Chem/CBC/UA Results: WBC 46,900, HCT 32%. USG: 1.023.

**ULTRASONOGRAPHIC EXAMINATION OF THE ABDOMEN**

**Urinary System**

The urinary bladder is moderately distended with anechoic urine. The Bladder wall, trigone, ureteral papillae, and visible urethra (to a depth of 2cm) appear normal with no evidence of wall thickening, mucosal irregularities, or masses. In the dependent portion of the urinary bladder, there is a small pile of dependent mineralized material, most consistent with sandy debris/small stones. The previously described irregularity described in the trigone region/proximal urethra is not as pronounced on today's exam. It appears most consistent with a mildly dilated proximal urethra.

The prostate is normal in size (1.41 cm) and shape for this neutered male dog. The parenchyma is homogenous, and the external margins are smooth. The prostatic urethra appears normal with no evidence of irregularity, invasion, mass effect, or calculi.

The left kidney has a normal shape and size (4.64 cm). Overall echogenicity is slightly hyperechoic with poor corticomedullary distinction and a typical 1:3 cortex: medulla ratio. There is no evidence of focal perinephric inflammation or effusion. There is no evidence of pyelectasia, nephroliths, infarcts or hydroureter. Renal vasculature is normal.

The right kidney has a normal shape and size (4.51 cm). Overall echogenicity is slightly hyperechoic with poor corticomedullary distinction and a typical 1:3 cortex: medulla ratio. There is no evidence of focal perinephric inflammation or effusion. There is no evidence of pyelectasia, nephroliths, infarcts, or hydroureter. Renal vasculature is normal.

**Adrenal Glands**

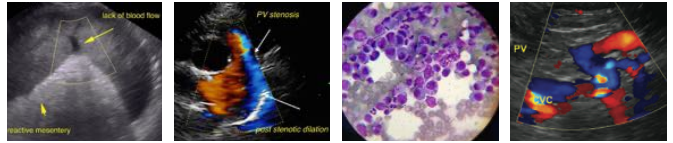
The left adrenal gland is large and slightly irregular in appearance measuring 1.75 cm at the cranial pole, 1.62 cm at the caudal pole, and 4.11 cm in length. It is visualized in its normal position cranial to the left renal artery. It is somewhat abnormal in appearance in that it is enlarged. No overt vascular invasion is visualized. The appearance of the left adrenal is not significantly changed from the previous exam 4/19/2023.

The right adrenal gland is normal in size measuring 0.64 cm at the caudal pole. It is observed in its normal position between the cranial aspect of the right kidney and the caudal vena cava. It is normal in appearance (uniformly hypoechoic) and shape with no evidence of a mass effect.

**Spleen**

The spleen is subjectively large in size. The spleen echotexture is heterogenous and diffusely mottled, the splenic capsule is smooth with no irregularities. The blood flow through the hilus and splenic parenchyma appears normal. There is an ill-defined hypoechoic nodule visualized within the parenchyma measuring 1.61 cm x 1.69 cm. The diffuse mottling/nodular pattern almost appears reticulated.

**Liver**



**PATIENT**

Clyde Biber

The liver is large in size, and normal in echogenicity with smooth peripheral margins. The parenchyma is heterogenous in echotexture with subtle, indistinct focal mottling. The visible portions of the vasculature and biliary tract appear normal. There are numerous indistinct hypoechoic nodules visualized in the parenchyma.

**SPECIES**

Canine

The gall bladder lumen is moderately distended. The wall of the gall bladder is not thickened and has a smooth mucosal surface. There is a moderate amount of non-organized echogenic debris. The cystic and common bile ducts are normal/not visible.

**BREED**

Coon Hound Mix

**Gastrointestinal**

**SEX**

43lbs

The stomach is minimally dilated with fluid and some hypoechoic non shadowing structures. Overall, the gastric wall appears normal measuring <0.7cm in thickness with some variability due to the presence of rugal folds. The distinction of the gastric wall layers is adequate and there is no impression of reduced peristaltic activity. There is one small focal rounded area along the mucosal surface of the gastric wall measuring approximately 0.7 cm x 0.67 cm. This could represent a pronounced rugal fold, a polyp, an early mass lesion, etc.

**AGE**

16-year-old

The visualized areas of duodenum, jejunum, and ileum have a relatively uniform diameter with minimal fluid distension. Wall thickness is normal. Bowel loops follow a curvilinear path with distinct wall layering maintaining the typical 1:3 muscularis: mucosa layer ratio. The duodenum measured as normal (between 0.3-0.5cm in wall thickness) and the jejunum measured as normal (between 0.2-0.47cm.) Visualized peristalsis appears appropriate. There were no focal lesions consistent with obstruction or a mass effect observed.

**WEIGHT**

43lbs

The ileocecal junction was visualized and exhibited normal intact wall layering and is subjectively of normal thickness. Sections of colon are visualized with formed fecal material and gas shadowing distally. There is no observed focal or generalized colon wall thickening or loss of layering.

**INTERPRETED BY**

Kathleen Sennello DVM,  
MS, Diplomate ACVIM  
(Small Animal Internal  
Medicine)

**Pancreas**

The area of the pancreas is normal and isoechoic to surrounding mesentery. There is no evidence of nodules or cystic lesions. There is no evidence of regional mesenteric inflammation or fluid.

**IMAGING PERFORMED BY**

Kelly Vazquez

**Free Abdomen**

Evaluation of the peritoneal cavity did not reveal any evidence of effusion. There are numerous prominent slightly rounded hypoechoic lymph nodes in the abdomen. A lymph node dependent to the stomach measures at 1.03 cm along with a cluster of lymph nodes measuring 1.12 cm. The mesenteric lymph nodes are visualized measuring 0.58 cm and 0.53 cm. The splenic lymph node measures at 0.69 cm. The Medial iliac nodes appear normal and there was no evidence of a caudal aortic thrombus at the bifurcation. The omentum is of normal uniform echogenicity. Overall, these lymph nodes are relatively stable from the previous scan.

**HOSPITAL NAME**

Animal General on  
Hudson

**REFERRING VET**

Dr. Karen Zelinski

**INVOICE**

10205

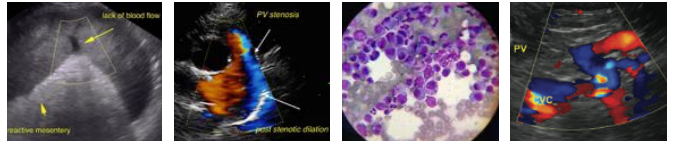
- Dependent mineralized debris in the urinary bladder. Recommend a urinalysis and culture and continued monitoring.

**DATE**

5/10/2023

**PRIMARY FINDINGS**

- Large left adrenal gland. Adrenomegaly could be consistent with neoplasia (e.g., adenoma, carcinoma, pheochromocytoma), hyperplasia, inflammation, other.
- Severely mottled spleen with a small hypoechoic splenic nodule. There is a non-cavitated, hypoechoic splenic nodule visualized. Differentials include lymphoid hyperplasia,



**PATIENT**

Clyde Biber

extramedullary hematopoiesis, infiltrative neoplasia, inflammation, other. Cytology or histopathology would be necessary to get a definitive diagnosis.

**SPECIES**

Canine

- Large heterogeneous liver with hypoechoic nodules. The diffuse hepatic changes are non-specific and could be consistent with vacuolar hepatopathy, nodular hyperplasia, inflammatory/immune-mediated disease, fibrosis, extramedullary hematopoiesis, toxic hepatopathy (e.g., copper), infiltrative neoplasia (less likely) or other hepatopathy. The nodules observed trend toward a more benign process, but underlying neoplasia cannot be ruled out.

**BREED**

Coon Hound Mix

- Moderate gallbladder debris. The significance of the aggregated gallbladder debris is unclear. This could represent an early mucocele, cholestasis, or may be secondary to fasting but seems unlikely to be causing a current issue. Recommend continued monitoring.

**SEX**

43lbs

- Focal irregularity in the gastric wall, this is small and of unknown significance. Recommend recheck in 2 to 3 months.

**AGE**

16-year-old

- Prominent rounded hypoechoic mesenteric lymph nodes. The moderate mesenteric lymphadenopathy could be concerning for a neoplastic process, although you can see significant lymphadenopathy in some cases of autoimmune/inflammatory disease, infectious disease (tick born disease-such as bartonealla, fungal infections, etc. A fine needle aspirate with cytology is recommended for further evaluation.

**WEIGHT**

43lbs

**INTERPRETED BY**

Kathleen Sennello DVM,  
MS, Diplomate ACVIM  
(Small Animal Internal  
Medicine)

**INTERPRETATION OF THE FINDINGS & FURTHER RECOMMENDATIONS**

Today's scan appears very similar from the previous scan 4/19/2023 with no significant progressions of the lesions observed. A fine needle aspirate was performed during today's exam which is the next step in this evaluation. If a cytologic diagnosis cannot be made, consider a fine needle aspirate of a mesenteric lymph node.

**IMAGING PERFORMED BY**

Kelly Vazquez

See the previous report regarding recommendations for further evaluation of the left adrenal, monitoring with ultrasound is an option at this time.

Consider a recheck ultrasound in 2 to 3 months.

**HOSPITAL NAME**

Animal General on  
Hudson

**REFERRING VET**

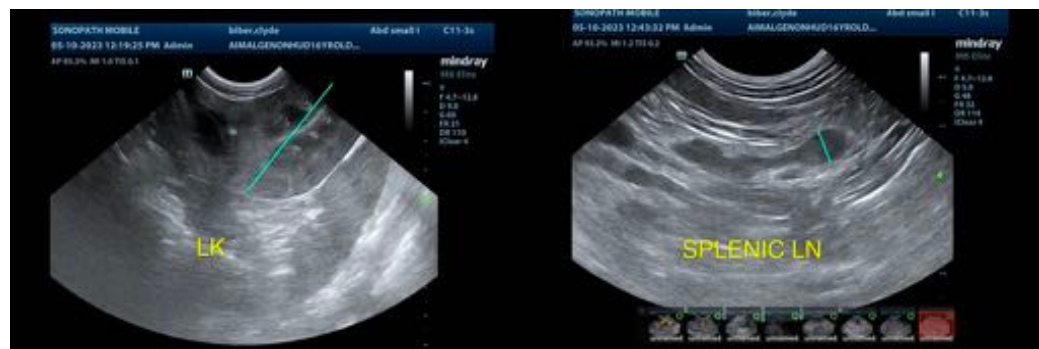Dr. Karen Zelinski

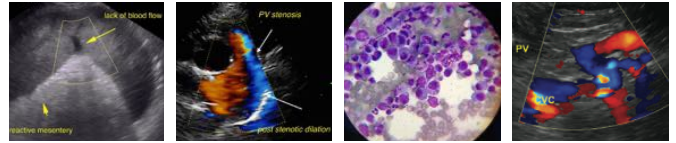
**INVOICE**

10205

**DATE**

5/10/2023





**PATIENT**

Clyde Biber

**SPECIES**

Canine

**BREED**

Coon Hound Mix

**SEX**

43lbs

**AGE**

16-year-old

**WEIGHT**

43lbs

**INTERPRETED BY**

Kathleen Sennello DVM,  
MS, Diplomate ACVIM  
(Small Animal Internal  
Medicine)

**IMAGING  
PERFORMED BY**

Kelly Vazquez

**HOSPITAL NAME**

Animal General on  
Hudson

**REFERRING VET**

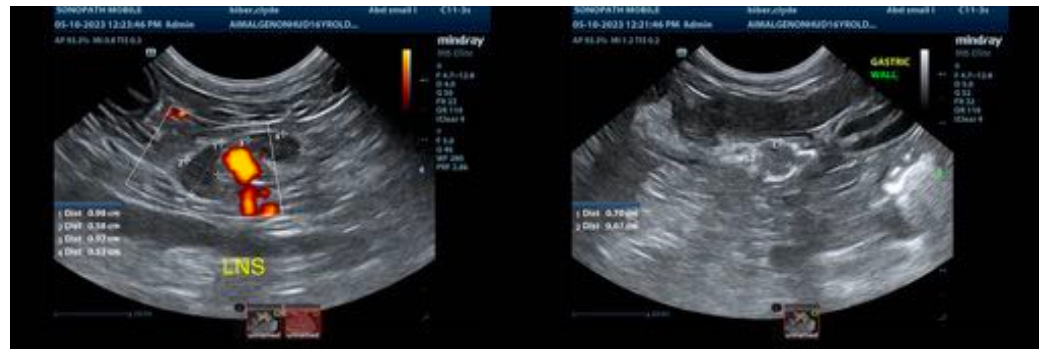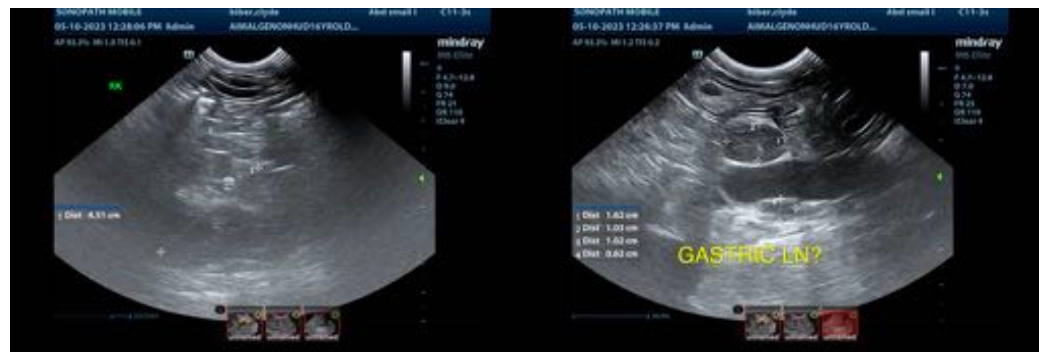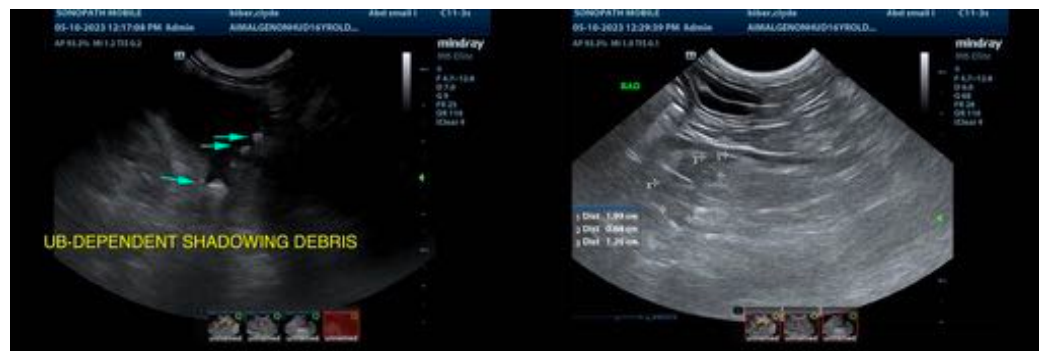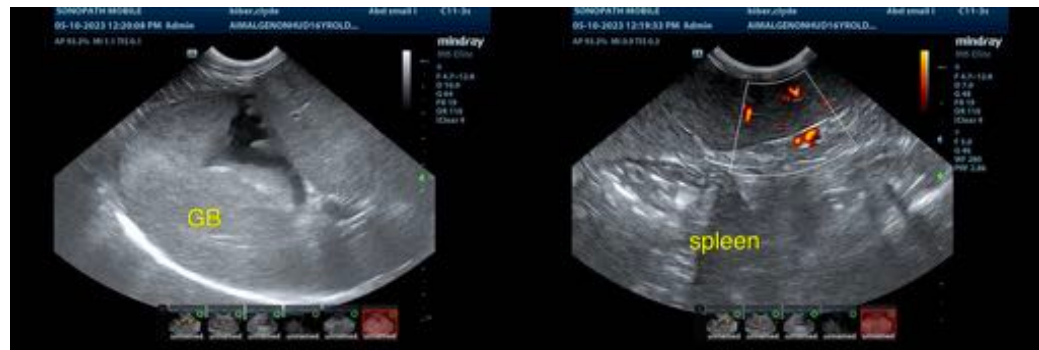Dr. Karen Zelinski

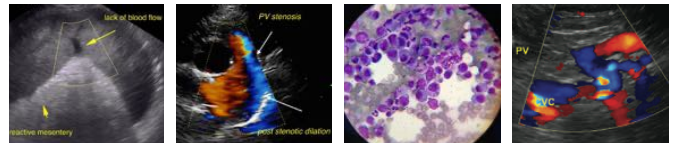
**INVOICE**

10205

**DATE**

5/10/2023





**PATIENT**

Clyde Biber

**SPECIES**

Canine

**BREED**

Coon Hound Mix

**SEX**

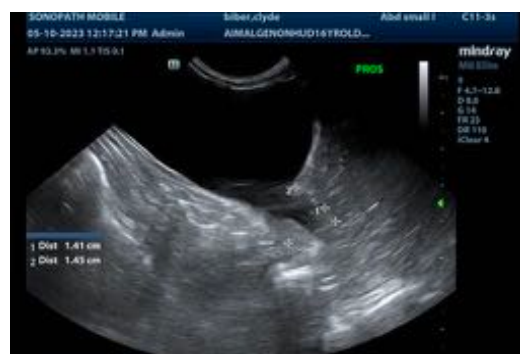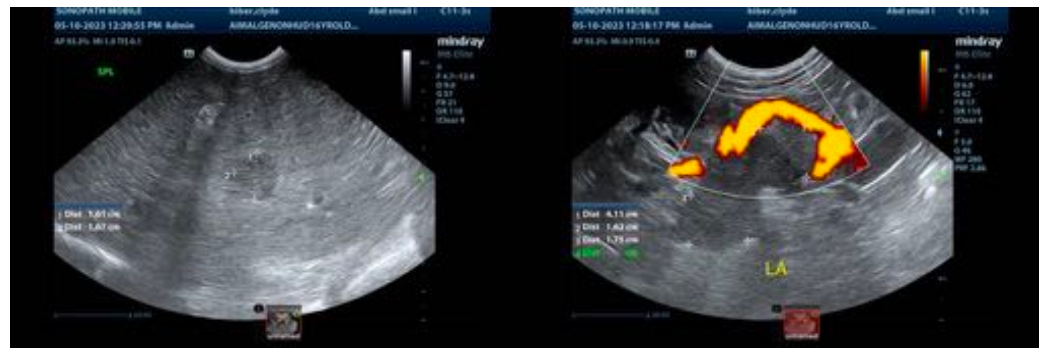
43lbs

**AGE**

16-year-old

**WEIGHT**

43lbs



**INTERPRETED BY**

Kathleen Sennello DVM,  
MS, Diplomate ACVIM  
(Small Animal Internal  
Medicine)

The information and recommendations provided are based on the images presented by the referring veterinarian/sonographer. No evaluation can be communicated regarding pathology that was not visible in the image/video clips provided.

**IMAGING PERFORMED BY**

Kelly Vazquez

Thank you for this referral. If the clinical or image interpretation does not parallel your findings or if I can be of any further assistance, please contact me.

Kathleen Sennello DVM, MS, Diplomate ACVIM (Small animal Internal Medicine)

kathleen.sennello@sonopath.com

**HOSPITAL NAME**

Animal General on  
Hudson

**REFERRING VET**

Dr. Karen Zelinski

**INVOICE**

10205

**DATE**

5/10/2023