



PATIENT

Rosie Michelman

SPECIES

Feline

BREED

DSH

SEX

FS

AGE

13 years 10 months

WEIGHT

7.0 lbs

INTERPRETED BY

Kathleen Sennello DVM,
MS, Diplomate ACVIM
(Small Animal Internal
Medicine)

IMAGING PERFORMED BY

Dr. Melinda Perrson

HOSPITAL NAME

At Home Veterinary

REFERRING VET

Dr. Melinda Perrson

INVOICE

11673

DATE

4/9/2026

PRESENTING CLINICAL SIGNS

Hyporexia, weight loss, lethargy, Controlled hyperthyroid disease x 2 years, BP 155, Diagnosed today with end stage heart failure - r/o RCM vs less likely DCM.

ULTRASONOGRAPHIC EXAMINATION OF THE ABDOMEN

Urinary System

The urinary bladder is moderately distended with anechoic urine. The Bladder wall, trigone, ureteral papillae and visible urethra (to a depth of 2cm) appear normal with no evidence of wall thickening, mucosal irregularities, masses or cystic calculi.

The left kidney has a normal shape and size (3.76 cm). Overall echogenicity is normal with adequate corticomedullary distinction and a typical 1:3 cortex:medulla ratio. There is no evidence of focal perinephric inflammation or effusion. There is no evidence of pyelectasia, nephroliths, infarcts or hydroureter. Renal vasculature is normal.

The right kidney has a normal shape and size (3.73 cm). Overall echogenicity is normal with adequate corticomedullary distinction and a typical 1:3 cortex:medulla ratio. There is no evidence of focal perinephric inflammation or effusion. There is no evidence of pyelectasia, nephroliths, infarcts or hydroureter. Renal vasculature is normal.

Adrenal Glands

The left adrenal gland is normal in size measuring 0.35 cm at the caudal pole. It is observed in its normal position cranial to the left renal artery. It is normal in appearance (uniformly hypoechoic) and shape with no evidence of a mass effect.

The right adrenal gland is normal in size measuring 0.49 cm at the caudal pole. It is observed in its normal position between the cranial aspect of the right kidney and the caudal vena cava. It is normal in appearance (uniformly hypoechoic) and shape with no evidence of a mass effect.

Spleen

The spleen is subjectively normal in size (0.58 cm), echotexture is homogenous, and the splenic capsule is smooth with no irregularities. The blood flow through the hilus and splenic parenchyma appears normal. No focal parenchymal abnormalities are visualized.

Liver

The liver is large in size, and normal in echogenicity with smooth peripheral margins. The parenchyma is mildly heterogenous in echotexture with subtle, indistinct focal mottling. The visible portions of the vasculature and biliary tract appear normal. No focal nodules or cystic lesions are observed.

The gall bladder lumen is moderately distended. The wall of the gall bladder is not thickened and has a smooth mucosal surface. Luminal contents are mild and likely incidental at this time. The cystic and common bile ducts are normal/not visible.

Gastrointestinal

The stomach contains minimal luminal contents. It measures at a normal thickness of <0.36cm with some variability due to the presence of rugal folds. The distinction of the gastric wall layers is



PATIENT

Rosie Michelman

SPECIES

Feline

BREED

DSH

SEX

FS

AGE

13 years 10 months

WEIGHT

7.0 lbs

INTERPRETED BY

Kathleen Sennello DVM,
MS, Diplomate ACVIM
(Small Animal Internal
Medicine)

IMAGING PERFORMED BY

Dr. Melinda Perrson

HOSPITAL NAME

At Home Veterinary

REFERRING VET

Dr. Melinda Perrson

INVOICE

11673

DATE

4/9/2026

adequate and there is no impression of reduced peristaltic activity. No masses or focal lesions were observed.

The visualized areas of duodenum, jejunum and ileum have a relatively uniform diameter with minimal fluid distension. Wall thickness is normal. Bowel loops follow a curvilinear path with distinct wall layering maintaining the typical 1:3 muscularis:mucosa layer ratio. The duodenum measured as normal (between 0.13-0.38cm in wall thickness) and the jejunum measured as normal (0.20 cm.) Visualized peristalsis appears appropriate. There were no focal lesions consistent with obstruction or a mass effect observed.

The ileocecal junction was visualized and exhibited normal intact wall layering and is subjectively of normal thickness. Sections of colon are visualized with formed fecal material and gas shadowing distally. There is no observed focal or generalized colon wall thickening or loss of layering.

Pancreas

The pancreas is prominent and mottled in the left limb. There is no evidence of nodules or cystic lesions. There is no evidence of regional mesenteric inflammation or fluid.

Free Abdomen

Evaluation of the peritoneal cavity did not reveal any evidence of effusion, or subjective lymphadenomegaly. The Medial iliac nodes appear normal and there was no evidence of a caudal aortic thrombus at the bifurcation. The omentum is of normal uniform echogenicity.

Other

There's a large amount of pleural effusion visualized cranial to the diaphragm.

ULTRASONOGRAPHIC FINDINGS

- Pancreatic changes most consistent with chronic pancreatic remodeling +/- chronic pancreatitis.
- Mildly heterogenous liver. Hepatic changes are non-specific and could be consistent with inflammation/infection (cholangiohepatitis), infiltrative neoplasia, lipidosis or other hepatopathy.
- Large volume of pleural effusion.

INTERPRETATION OF THE FINDINGS & FURTHER RECOMMENDATIONS

The pancreas is prominent and hypoechoic in the left limb, most consistent with chronic pancreatic remodeling but mild chronic pancreatitis is possible. Correlate with quantitative PLI level.

The liver appears subjectively large and mildly heterogenous. Correlate with liver values. There's a large amount of pleural effusion present. Some of these changes could be due to congestion, due to underlying cardiac disease, etc.

Recommend three view thoracic radiographs and a cardiac ultrasound (I believe this was done today) for further evaluation. A therapeutic thoracocentesis may be necessary to make the patient more comfortable and feel better.



PATIENT

Rosie Michelman

SPECIES

Feline

BREED

DSH

SEX

FS

AGE

13 years 10 months

WEIGHT

7.0 lbs

INTERPRETED BY

Kathleen Sennello DVM,
MS, Diplomate ACVIM
(Small Animal Internal
Medicine)

IMAGING PERFORMED BY

Dr. Melinda Perrson

HOSPITAL NAME

At Home Veterinary

REFERRING VET

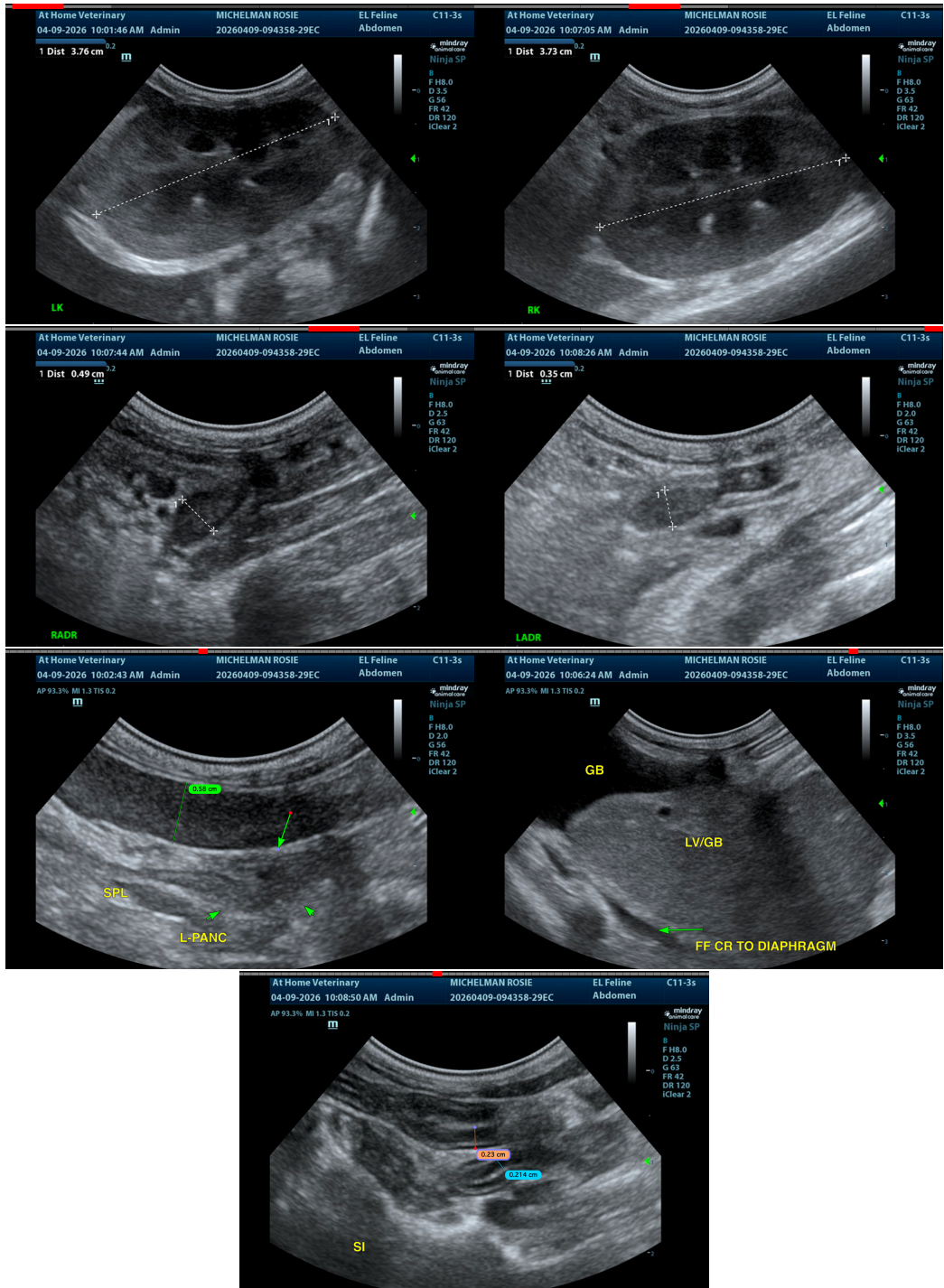
Dr. Melinda Perrson

INVOICE

11673

DATE

4/9/2026



The information and recommendations provided are based on the images presented by the referring veterinarian/sonographer. No evaluation can be communicated regarding pathology that was not visible in the image/video clips provided.



PATIENT

Rosie Michelman

SPECIES

Feline

BREED

DSH

SEX

FS

AGE

13 years 10 months

WEIGHT

7.0 lbs

INTERPRETED BY

Kathleen Sennello DVM,
MS, Diplomate ACVIM
(Small Animal Internal
Medicine)

IMAGING PERFORMED BY

Dr. Melinda Perrson

HOSPITAL NAME

At Home Veterinary

REFERRING VET

Dr. Melinda Perrson

INVOICE

11673

DATE

4/9/2026

Thank you for this referral. If the clinical or image interpretation does not parallel your findings or if I can be of any further assistance please contact me.

Kathleen Sennello DVM,MS, Diplomate ACVIM (Small animal Internal Medicine)

info@sonopath.com