



PATIENT

Roger Moore

SPECIES

Canine

BREED

Golden Retriever

SEX

Neutered Male

AGE

9 Years

WEIGHT

70 lbs

INTERPRETED BY

Kathleen Sennello DVM,
MS, Diplomate ACVIM
(Small Animal Internal
Medicine)

IMAGING PERFORMED BY

Jessica Milligan, DVM

HOSPITAL NAME

Dockside Veterinary
Imaging

REFERRING VET

Ronald Bell, DVM

INVOICE

74330

DATE

4/9/26

PRESENTING CLINICAL SIGNS

Suspect pancreatic disease, non-symptomatic. Hx of elevated cPL.
Abnormal PE/Chem/CBC/UA Results: hx attached.

ULTRASONOGRAPHIC EXAMINATION OF THE ABDOMEN

Urinary System

The urinary bladder is moderately distended with anechoic urine. The Bladder wall, trigone, ureteral papillae and visible urethra (to a depth of 2cm) appear normal with no evidence of wall thickening, mucosal irregularities, masses or cystic calculi.

The prostate is normal in size (1.39 cm) and shape for this neutered male dog. The parenchyma is homogenous and the external margins are smooth. The prostatic urethra appears normal with no evidence of irregularity, invasion, mass effect or calculi.

The left kidney has a normal shape and size (6.15 cm). Overall echogenicity is slightly hyperechoic with mildly reduced corticomedullary distinction and a typical 1:3 cortex:medulla ratio. There is no evidence of focal perinephric inflammation or effusion. There is no evidence of pyelectasia, nephroliths, infarcts or hydronephrosis. Renal vasculature is normal.

The right kidney has a normal shape and size (6.79 cm). Overall echogenicity is slightly hyperechoic with mildly reduced corticomedullary distinction and a typical 1:3 cortex:medulla ratio. There is no evidence of focal perinephric inflammation or effusion. There is no evidence of pyelectasia, nephroliths, infarcts or hydronephrosis. Renal vasculature is normal.

Adrenal Glands

The left adrenal gland is normal in size measuring 0.48 cm at the cranial pole and 0.59 cm at the caudal pole. It is observed in its normal position cranial to the left renal artery. It is normal in appearance (uniformly hypoechoic) and shape with no evidence of a mass effect.

The right adrenal gland is normal in size measuring 0.76 cm at the cranial pole and 0.60 cm at the caudal pole. It is observed in its normal position between the cranial aspect of the right kidney and the caudal vena cava. It is normal in appearance (uniformly hypoechoic) and shape with no evidence of a mass effect.

Spleen

The spleen is subjectively normal in size (2.68 cm), echotexture is homogenous, and the splenic capsule is smooth with no irregularities. The blood flow through the hilus and splenic parenchyma appears normal. No focal parenchymal abnormalities are visualized.

Liver

The liver is subjectively normal in size, and echogenicity with smooth peripheral margins. The parenchyma is mildly heterogenous in echotexture with subtle, indistinct focal mottling. The visible portions of the vasculature and biliary tract appear normal. No focal nodules or cystic lesions are observed.



PATIENT

Roger Moore

The gall bladder lumen is moderately distended. The wall of the gall bladder is not thickened and has a smooth mucosal surface. Luminal contents are mild and likely incidental at this time. The cystic and common bile ducts are normal/not visible.

SPECIES

Canine

Gastrointestinal

The stomach contains minimal luminal contents. It measures at a normal thickness of <0.7cm with some variability due to the presence of rugal folds. The distinction of the gastric wall layers is adequate and there is no impression of reduced peristaltic activity. No masses or focal lesions were observed.

BREED

Golden Retriever

The visualized areas of duodenum, jejunum and ileum have a relatively uniform diameter with minimal fluid distension. Wall thickness is normal. Bowel loops follow a curvilinear path with distinct wall layering maintaining the typical 1:3 muscularis:mucosa layer ratio. Duodenum wall measures 0.35 cm. Jejunum wall measures 0.32 cm. Visualized peristalsis appears appropriate. There were no focal lesions consistent with obstruction or a mass effect observed.

SEX

Neutered Male

AGE

9 Years

Sections of colon are visualized with formed fecal material and gas shadowing distally. There is no observed focal or generalized colon wall thickening or loss of layering.

WEIGHT

70 lbs

Pancreas

The pancreas is mildly mottled in the left limb. There is no evidence of nodules or cystic lesions. There is no evidence of regional mesenteric inflammation or fluid.

INTERPRETED BY

Kathleen Sennello DVM,
MS, Diplomate ACVIM
(Small Animal Internal
Medicine)

Free Abdomen

Evaluation of the peritoneal cavity did not reveal any evidence of effusion, or subjective lymphadenomegaly. The Medial iliac nodes appear normal and there was no evidence of a caudal aortic thrombus at the bifurcation. The omentum is of normal uniform echogenicity.

IMAGING PERFORMED BY

Jessica Milligan, DVM

ULTRASONOGRAPHIC FINDINGS

- Mild age related changes visualized associated with both kidneys.
- Pancreatic changes most consistent with mild chronic pancreatic remodeling.
- Mildly heterogeneous liver – Correlate with liver values. In the absence of significant liver enzyme elevations, the significance of this is uncertain.

HOSPITAL NAME

Dockside Veterinary
Imaging

INTERPRETATION OF THE FINDINGS & FURTHER RECOMMENDATIONS

The left limb of the pancreas is mildly mottled with no evidence of surrounding inflammation. Changes are likely normal for this individual or could be consistent with mild pancreatic remodeling. A small focus of active inflammation is possible but is not observed on today's exam.

REFERRING VET

Ronald Bell, DVM

INVOICE

74330

Subjectively, the liver appears mildly heterogeneous. In the absence of liver enzyme elevations, the significance of this is uncertain. These findings are non-specific and could be consistent with any hepatopathy or even age related remodeling, etc. Correlate these findings with your clinical assessment.

DATE

4/9/26



PATIENT

Roger Moore

SPECIES

Canine

BREED

Golden Retriever

SEX

Neutered Male

AGE

9 Years

WEIGHT

70 lbs

INTERPRETED BY

Kathleen Sennello DVM,
MS, Diplomate ACVIM
(Small Animal Internal
Medicine)

**IMAGING
PERFORMED BY**

Jessica Milligan, DVM

HOSPITAL NAME

Dockside Veterinary
Imaging

REFERRING VET

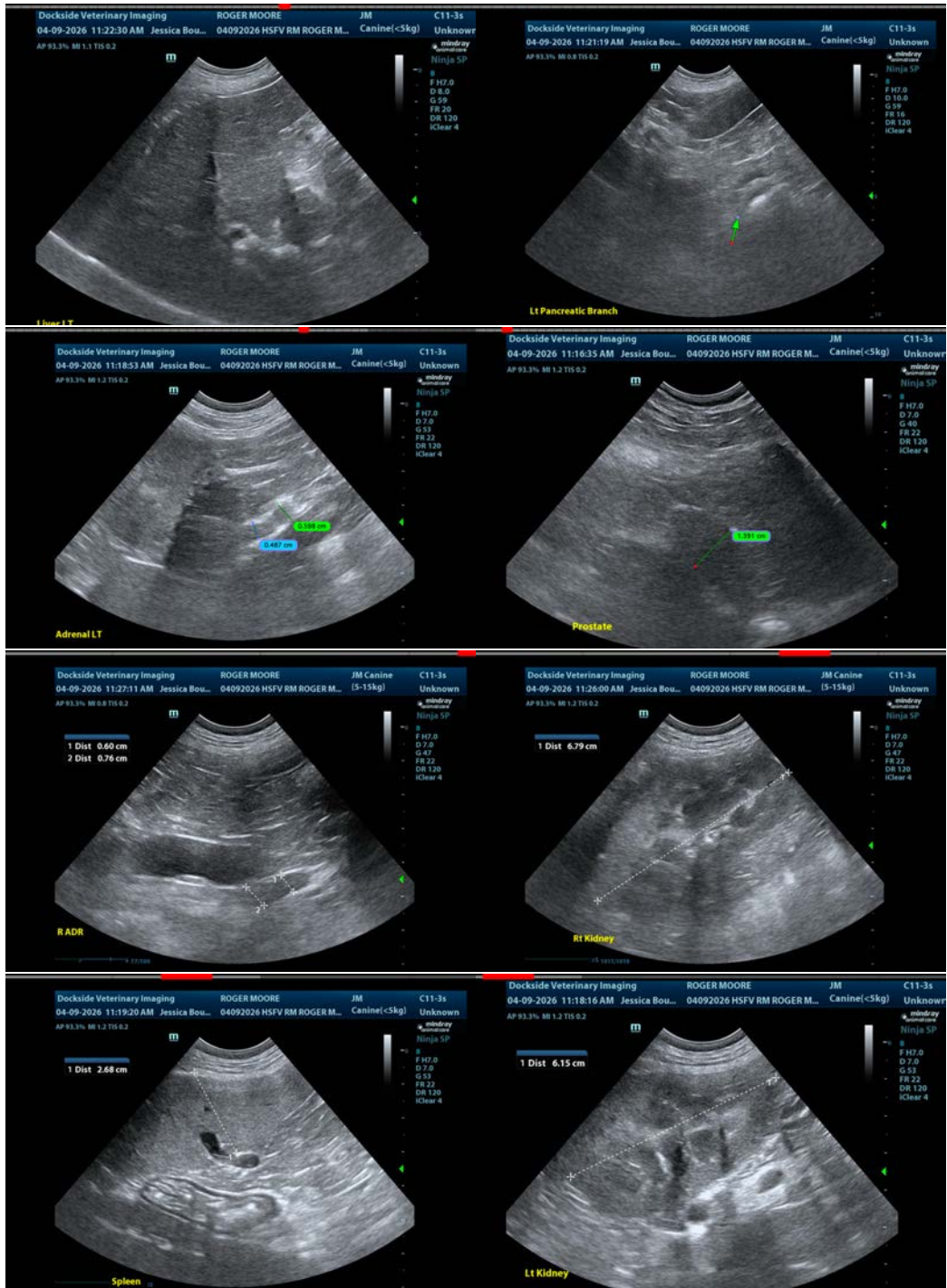
Ronald Bell, DVM

INVOICE

74330

DATE

4/9/26





PATIENT

Roger Moore

SPECIES

Canine

BREED

Golden Retriever

SEX

Neutered Male

AGE

9 Years

WEIGHT

70 lbs

INTERPRETED BY

Kathleen Sennello DVM,
MS, Diplomate ACVIM
(Small Animal Internal
Medicine)

IMAGING PERFORMED BY

Jessica Milligan, DVM

HOSPITAL NAME

Dockside Veterinary
Imaging

REFERRING VET

Ronald Bell, DVM

INVOICE

74330

DATE

4/9/26

The information and recommendations provided are based on the images presented by the referring veterinarian/sonographer. No evaluation can be communicated regarding pathology that was not visible in the image/video clips provided.

Thank you for this referral. If the clinical or image interpretation does not parallel your findings or if I can be of any further assistance please contact me.

Kathleen Sennello DVM,MS, Diplomate ACVIM (Small animal Internal Medicine)

info@sonopath.com