



PATIENT

Princess Martinez

SPECIES

Canine

BREED

Chihuahua

SEX

Spayed Female

AGE

8 Years 11 Months

WEIGHT

21 lbs

INTERPRETED BY

Kathleen Sennello DVM,
MS, Diplomate ACVIM
(Small Animal Internal
Medicine)

IMAGING PERFORMED BY

Kerri Becker

HOSPITAL NAME

Rockaway Animal
Hospital

REFERRING VET

Dr. Kahn

INVOICE

74325

DATE

4/9/26

PRESENTING CLINICAL SIGNS

Anorexia x 7 days, material in stomach on rads, concerns for gastric FB
Abnormal PE/Chem/CBC/UA Results: ALP-341

ULTRASONOGRAPHIC EXAMINATION OF THE ABDOMEN

Urinary System

The urinary bladder is moderately distended with anechoic urine. The Bladder wall, trigone, ureteral papillae and visible urethra (to a depth of 2cm) appear normal with no evidence of wall thickening, mucosal irregularities, masses or cystic calculi.

The left kidney has a normal shape and size (4.69 cm) with hyperechoic pinpoint cortical mineralizations. Overall echogenicity is normal with adequate corticomedullary distinction and a typical 1:3 cortex:medulla ratio. There is no evidence of focal perinephric inflammation or effusion. There is no evidence of pyelectasia, infarcts or hydroureter. Renal vasculature is normal.

The right kidney has a normal shape and size (5.33 cm). Overall echogenicity is normal with adequate corticomedullary distinction and a typical 1:3 cortex:medulla ratio. There is no evidence of focal perinephric inflammation or effusion. There is no evidence of pyelectasia, nephroliths, infarcts or hydroureter. Renal vasculature is normal.

Adrenal Glands

The left adrenal gland is normal in size measuring 0.30 cm at the cranial pole and 0.46 cm at the caudal pole. It is observed in its normal position cranial to the left renal artery. It is normal in appearance (uniformly hypoechoic) and shape with no evidence of a mass effect.

The right adrenal gland is normal in size measuring 0.90 cm at the cranial pole and 0.52 cm at the caudal pole. It is observed in its normal position between the cranial aspect of the right kidney and the caudal vena cava. It is normal in appearance (uniformly hypoechoic) and shape with no evidence of a mass effect.

Spleen

The spleen is subjectively normal in size (1.04 cm), echotexture is homogenous, and the splenic capsule is smooth with no irregularities. The blood flow through the hilus and splenic parenchyma appears normal. No focal parenchymal abnormalities are visualized.

Liver

The liver is subjectively normal in size, and echogenicity with smooth peripheral margins. The parenchyma is mildly heterogenous in echotexture with subtle, indistinct focal mottling. The visible portions of the vasculature and biliary tract appear normal. No focal nodules or cystic lesions are observed.

The gall bladder lumen is moderately distended. The wall of the gall bladder is not thickened and has a smooth mucosal surface. There is a moderate amount of non-organized echogenic debris. The cystic and common bile ducts are normal/not visible.



PATIENT

Princess Martinez

SPECIES

Canine

BREED

Chihuahua

SEX

Spayed Female

AGE

8 Years 11 Months

WEIGHT

21 lbs

INTERPRETED BY

Kathleen Sennello DVM,
MS, Diplomate ACVIM
(Small Animal Internal
Medicine)

IMAGING PERFORMED BY

Kerri Becker

HOSPITAL NAME

Rockaway Animal
Hospital

REFERRING VET

Dr. Kahn

INVOICE

74325

DATE

4/9/26

Gastrointestinal

The stomach contains moderate fluid/soft shadowing ingesta. It measures at a normal thickness of <0.7cm with some variability due to the presence of rugal folds. The distinction of the gastric wall layers is adequate and there is no impression of reduced peristaltic activity. No masses or focal lesions were observed.

The visualized areas of duodenum, jejunum and ileum have a relatively uniform diameter with minimal fluid distension. Wall thickness is normal. Bowel loops follow a curvilinear path with distinct wall layering maintaining the typical 1:3 muscularis:mucosa layer ratio. Duodenum wall measures 0.44 cm. Jejunum wall measures 0.26 cm. Visualized peristalsis appears appropriate. There were no focal lesions consistent with obstruction or a mass effect observed.

Sections of colon are visualized with formed fecal material and gas shadowing distally. There is no observed focal or generalized colon wall thickening or loss of layering.

Pancreas

The pancreas is visible/mildly mottled in the right limb. There is no evidence of nodules or cystic lesions. There is no evidence of regional mesenteric inflammation or fluid.

Free Abdomen

Evaluation of the peritoneal cavity did not reveal any evidence of effusion, or subjective lymphadenomegaly. The Medial iliac nodes appear normal and there was no evidence of a caudal aortic thrombus at the bifurcation. The omentum is of normal uniform echogenicity.

ULTRASONOGRAPHIC FINDINGS

- Pancreatic changes most consistent with chronic pancreatic remodeling +/- mild chronic pancreatitis.
- Mildly heterogeneous liver – The diffuse hepatic changes are non-specific and could be consistent with vacuolar hepatopathy, nodular hyperplasia, inflammatory/immune-mediated disease, fibrosis, extramedullary hematopoiesis, toxic hepatopathy (e.g., copper), infiltrative neoplasia (less likely) or other hepatopathy.
- Moderate gallbladder debris – The significance of the aggregated gallbladder debris is unclear. This could represent an early mucocele, cholestasis, or may be secondary to fasting but seems unlikely to be causing a current issue. Recommend continued monitoring.
- Mild/moderate fluid/ingesta distention of the stomach – No evidence of an outflow tract obstruction is clearly visualized. There is some hyperechoic soft shadowing material visualized in the region of the pylorus on some views.

INTERPRETATION OF THE FINDINGS & FURTHER RECOMMENDATIONS

There is a mild to moderate amount of fluid and shadowing ingesta visualized within the stomach. The shadowing ingesta is subtle and soft shadowing, potentially consistent with food or soft fabric-like material or similar. A definitive obstruction is not clearly visualized, although an intermittent obstruction cannot be ruled out.



PATIENT

Princess Martinez

SPECIES

Canine

BREED

Chihuahua

SEX

Spayed Female

AGE

8 Years 11 Months

WEIGHT

21 lbs

INTERPRETED BY

Kathleen Sennello DVM,
MS, Diplomate ACVIM
(Small Animal Internal
Medicine)

**IMAGING
PERFORMED BY**

Kerri Becker

HOSPITAL NAME

Rockaway Animal
Hospital

REFERRING VET

Dr. Kahn

INVOICE

74325

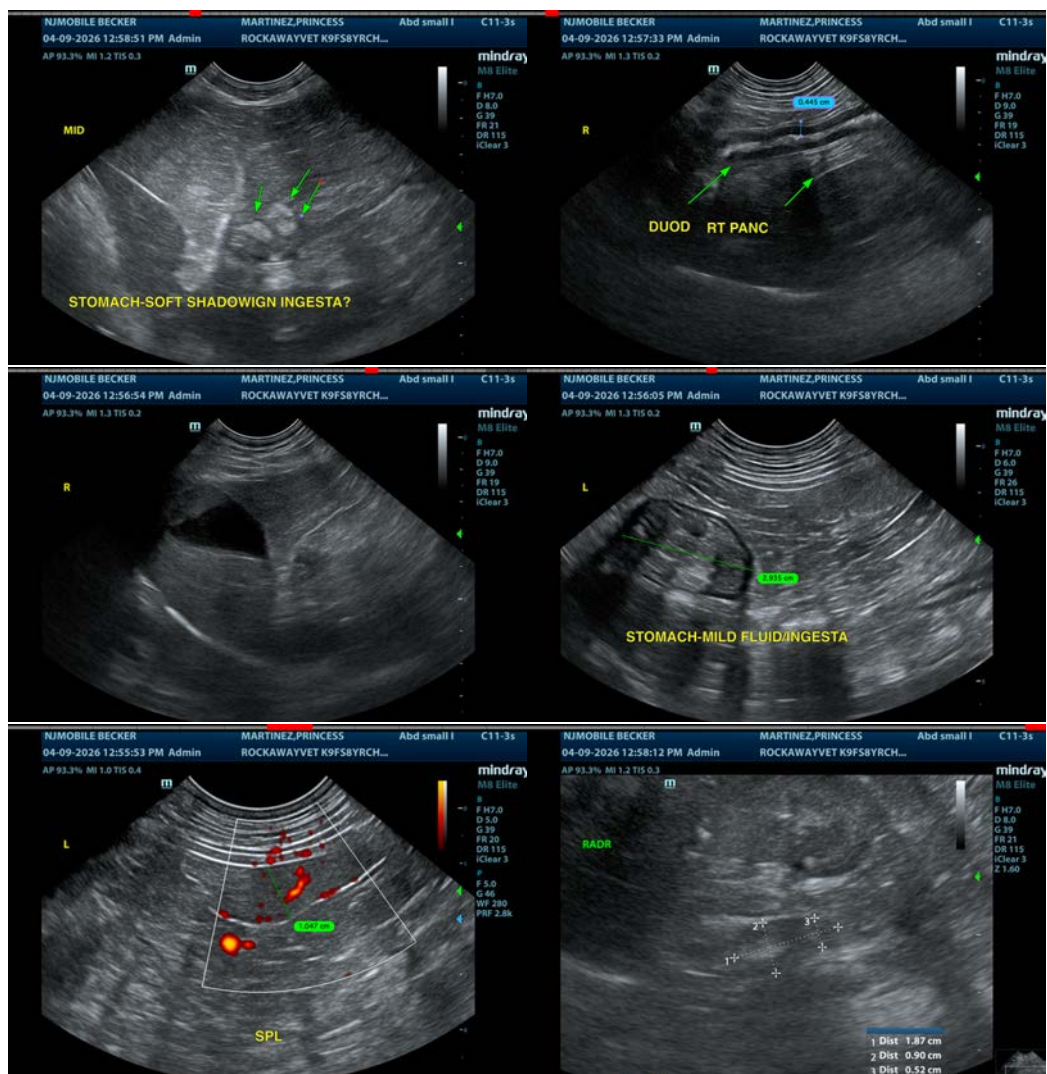
DATE

4/9/26

The right limb of the pancreas is visible/mildly mottled. Correlate with PLI level. If significant elevation is present, consider treatment for mild pancreatitis.

The liver appears mildly heterogeneous, possibly consistent with an early vacuolar hepatopathy. Recommend continued monitoring.

Correlate findings with radiographs to better determine if the stomach is less distended. Consider non-specific treatment for gastroenteritis. If symptoms are persistent you could consider upper GI endoscopy to further evaluate and obtain biopsies, and/or repeat imaging, looking for the progression of today's lesions or the development of new lesions.





PATIENT

Princess Martinez

SPECIES

Canine

BREED

Chihuahua

SEX

Spayed Female

AGE

8 Years 11 Months

WEIGHT

21 lbs

INTERPRETED BY

Kathleen Sennello DVM,
MS, Diplomate ACVIM
(Small Animal Internal
Medicine)

IMAGING PERFORMED BY

Kerri Becker

HOSPITAL NAME

Rockaway Animal
Hospital

REFERRING VET

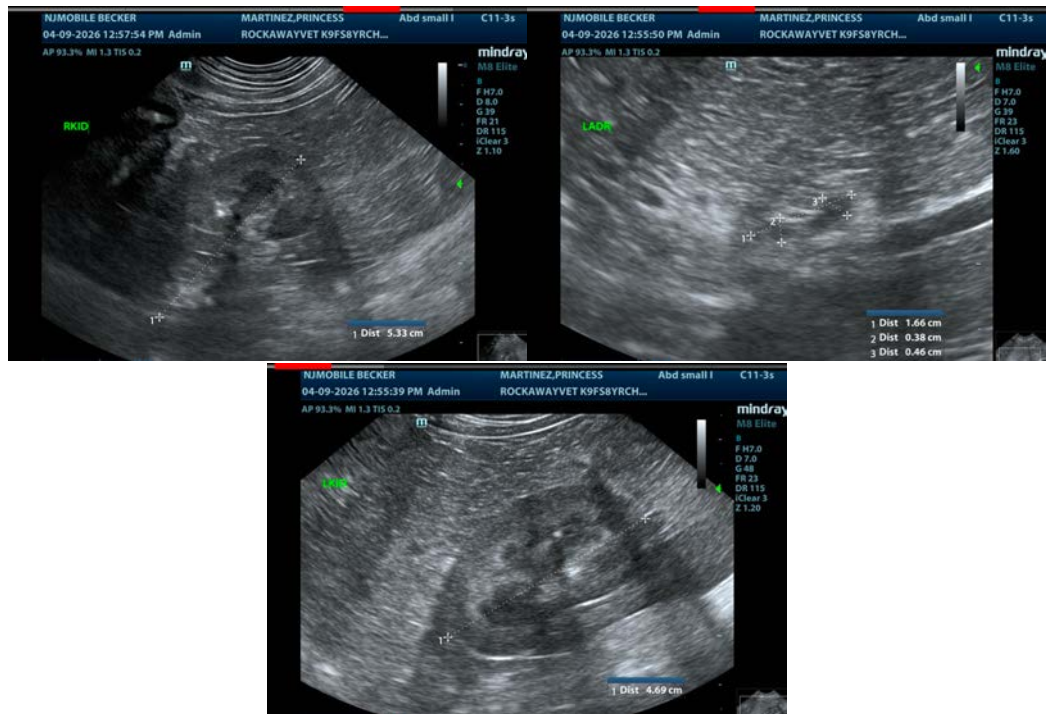
Dr. Kahn

INVOICE

74325

DATE

4/9/26



The information and recommendations provided are based on the images presented by the referring veterinarian/sonographer. No evaluation can be communicated regarding pathology that was not visible in the image/video clips provided.

Thank you for this referral. If the clinical or image interpretation does not parallel your findings or if I can be of any further assistance please contact me.

Kathleen Sennello DVM,MS, Diplomate ACVIM (Small animal Internal Medicine)

info@sonopath.com