



PATIENT

Petit Rechi

SPECIES

Feline

BREED

DSH

SEX

FS

AGE

3 years 7 months

WEIGHT

2.63 kgs

INTERPRETED BY

Kathleen Sennello DVM,
MS, Diplomate ACVIM
(Small Animal Internal
Medicine)

IMAGING PERFORMED BY

Dr. Gira

HOSPITAL NAME

Fish Creek 24
Emergency

REFERRING VET

Dr. Ashlyn Brulotte

INVOICE

11661

DATE

4/9/2026

PRESENTING CLINICAL SIGNS

Transfer from RDVM for severe azotemia. Lethargy , vomiting . Possible exposure to Voltaren ointment. She had been vomiting for ~4 days prior to being seen by primary veterinarian.

Abnormal PE/Chem/CBC/UA Results: Bloodwork showed: urea 95.2; creat 635; phos 6.05. RBC 12.59. Hct 54.4. TP 93. Glob 56. ALT 238. Tbili 24. Na 145. Cl 104. SDMA 75 U/A here: USG 1.018; ph6; protein 0.3 g/dl. Noted 1+ RBC on manual cytology and 2+ cocci, occ WBC.

ULTRASONOGRAPHIC EXAMINATION OF THE ABDOMEN

Urinary System

The urinary bladder is moderately distended with anechoic urine. The Bladder wall, trigone, ureteral papillae and visible urethra (to a depth of 2cm) appear normal with no evidence of wall thickening, mucosal irregularities, masses or cystic calculi.

The left kidney is borderline large in size (4.13 cm). The cortex is increased in echogenicity with poor corticomedullary distinction and a typical 1:3 cortex:medulla ratio. There is no evidence of surrounding fluid, but there is mildly reactive mesentery in the region of the kidney. There is no evidence of pyelectasia, nephroliths, infarcts or hydroureter. Renal vasculature is normal.

The right kidney is borderline large in size (4.64 cm). The cortex is of increased echogenicity with poor corticomedullary distinction and a typical 1:3 cortex:medulla ratio. There is no evidence of surrounding fluid, but there is mildly reactive mesentery in the region. There is no evidence of pyelectasia, nephroliths, infarcts or hydroureter. Renal vasculature is normal.

Adrenal Glands

The left adrenal gland is normal in size measuring 0.21 cm at the caudal pole. It is observed in its normal position cranial to the left renal artery. It is normal in appearance (uniformly hypoechoic) and shape with no evidence of a mass effect.

The right adrenal gland is normal in size measuring 0.32 cm at the caudal pole. It is observed in its normal position between the cranial aspect of the right kidney and the caudal vena cava. It is normal in appearance (uniformly hypoechoic) and shape with no evidence of a mass effect.

Spleen

The spleen is subjectively normal in size (0.68 cm), echotexture is homogenous, and the splenic capsule is smooth with no irregularities. The blood flow through the hilus and splenic parenchyma appears normal. No focal parenchymal abnormalities are visualized.

Liver

The liver is subjectively normal in size, and echogenicity with smooth peripheral margins. The parenchyma is homogenous echotexture. The visible portions of the vasculature and biliary tract appear normal. No focal nodules or cystic lesions are observed.

The gall bladder lumen is moderately distended. The wall of the gall bladder is not thickened and has a smooth mucosal surface. Luminal contents are mild and likely incidental at this time. The proximal bile duct is mildly dilated measuring 0.22 cm.



PATIENT

Petit Rechi

SPECIES

Feline

BREED

DSH

SEX

FS

AGE

3 years 7 months

WEIGHT

2.63 kgs

INTERPRETED BY

Kathleen Sennello DVM,
MS, Diplomate ACVIM
(Small Animal Internal
Medicine)

IMAGING PERFORMED BY

Dr. Gira

HOSPITAL NAME

Fish Creek 24
Emergency

REFERRING VET

Dr. Ashlyn Brulotte

INVOICE

11661

DATE

4/9/2026

Gastrointestinal

The stomach contains minimal luminal contents. It measures at a normal thickness of <0.36cm with some variability due to the presence of rugal folds. The distinction of the gastric wall layers is adequate and there is no impression of reduced peristaltic activity. No masses or focal lesions were observed.

The visualized areas of duodenum, jejunum and ileum have a relatively uniform diameter with minimal fluid distension. Wall thickness is normal. Bowel loops follow a curvilinear path with distinct wall layering maintaining the typical 1:3 muscularis:mucosa layer ratio. The duodenum measured as normal (0.21 cm in wall thickness) and the jejunum measured as normal (0.19 cm.) Visualized peristalsis appears appropriate. There were no focal lesions consistent with obstruction or a mass effect observed.

The ileocecal junction was visualized and exhibited normal intact wall layering and is subjectively of normal thickness. Sections of colon are visualized with formed fecal material and gas shadowing distally. There is no observed focal or generalized colon wall thickening or loss of layering.

Pancreas

The pancreas is prominent and hypoechoic in the left limb. There is no evidence of nodules or cystic lesions. There is no evidence of regional mesenteric inflammation or fluid.

Free Abdomen

Evaluation of the peritoneal cavity did not reveal any evidence of effusion. There is no significant lymphadenopathy. There are prominent colic lymph nodes at the ileocecal junction measuring 0.32 cm and 0.25 cm. A jejunal lymph node is visualized measuring 0.28 cm. The omentum is mildly hyperechoic around the kidneys.

ULTRASONOGRAPHIC FINDINGS

- Borderline large, hyperechoic kidneys with mildly reduced corticomedullary distinction and mild perinephric inflammation. Findings are suggestive of acute renal injury/swelling. Other differentials could include early FIP, round cell neoplasia, etc.
- Pancreatic changes consistent with chronic pancreatic remodeling/mild pancreatitis.
- Mildly dilated proximal bile duct. Dilation of the common bile duct could be consistent with a functional obstruction (i.e. primary hepatic disease resulting in hepatocellular swelling) or with an extrahepatic bile duct obstruction (ie. choledocholith, bile duct tumor, pancreatic disease, other).
- Occasional reactive mesenteric lymph nodes.

INTERPRETATION OF THE FINDINGS & FURTHER RECOMMENDATIONS

Both kidneys are borderline large and hyperechoic with mildly reduced corticomedullary distinction and perinephric inflammation. Given the young age of this individual, there would be concern for acute renal injury (inflammation, infection, toxin, hypotension, dehydration, etc) or possibly early round cell neoplasia, FIP, etc. Other differentials are possible. Recommend diuresis and treatment for acute renal injury with close continued monitoring as well as blood pressure evaluation and a urine culture.



PATIENT

Petit Rechi

SPECIES

Feline

BREED

DSH

SEX

FS

AGE

3 years 7 months

WEIGHT

2.63 kgs

INTERPRETED BY

Kathleen Sennello DVM,
MS, Diplomate ACVIM
(Small Animal Internal
Medicine)

IMAGING PERFORMED BY

Dr. Gira

HOSPITAL NAME

Fish Creek 24
Emergency

REFERRING VET

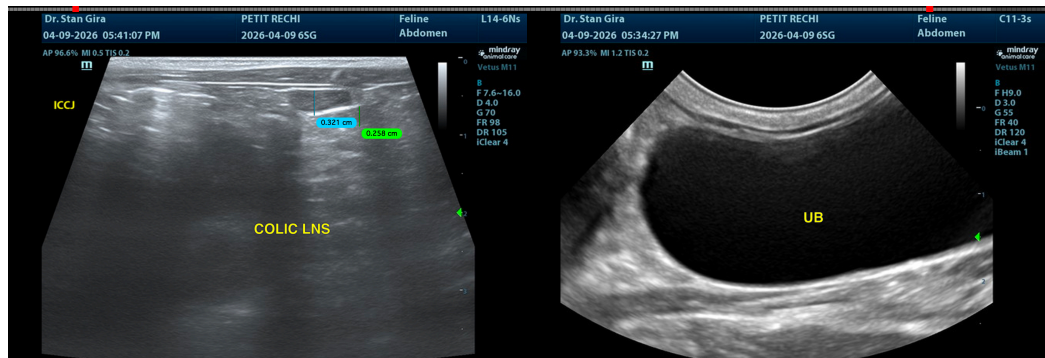
Dr. Ashlyn Brulotte

INVOICE

11661

DATE

4/9/2026



The information and recommendations provided are based on the images presented by the referring veterinarian/sonographer. No evaluation can be communicated regarding pathology that was not visible in the image/video clips provided.

Thank you for this referral. If the clinical or image interpretation does not parallel your findings or if I can be of any further assistance please contact me.

Kathleen Sennello DVM,MS, Diplomate ACVIM (Small animal Internal Medicine)

info@sonopath.com