

PATIENT

Lola Espinosa

SPECIES

Canine

BREED

Shih Tzu

SEX

Spayed Female

AGE

15 Years

WEIGHT

13.4 lbs

INTERPRETED BY

Kathleen Sennello DVM, MS, Diplomate ACVIM (Small Animal Internal Medicine)

IMAGING PERFORMED BY

Gabriel Ferrer, DVM

HOSPITAL NAME

Pulse: Pet Ultrasound

REFERRING VET

Dr. Carlos Soto

INVOICE

74327

DATE

4/9/26

PRESENTING CLINICAL SIGNS

Px presented as a referral for an abdominal ultrasound due to Hx of hematuria and elevated hepatic enzymes. Px originally visited rDVM due to hematuria and bloodwork showed elevations in liver enzyme values. Px was started on Denamarin but on follow up appointments liver values showed an increase. Px has a Hx of mammary masses and bladder stones.

Abnormal PE/Chem/CBC/UA Results: Bloodwork and radiographs attached below for your reference

ULTRASONOGRAPHIC EXAMINATION OF THE ABDOMEN

Urinary System

The urinary bladder is moderately distended with anechoic urine. The Bladder wall appears diffusely thickened and irregular, measuring at 0.40 cm. In the dependent portion of the urinary bladder there is some small mineralized/sandy debris, some of which have the appearance most consistent with very small stones. Examples measures 0.11 cm and 0.14 cm.

The left kidney has a normal shape and size (4.78 cm) with significant pyelectasia at 0.41 cm and numerous small cortical cysts. Overall echogenicity is slightly hyperechoic with poor corticomedullary distinction and a typical 1:3 cortex:medulla ratio. There is no evidence of focal perinephric inflammation or effusion. There is no evidence of nephroliths, infarcts or hydroureter. Renal vasculature is normal.

The right kidney has a normal shape and size (3.88 cm) with significant pyelectasia at 0.66 cm and numerous small cortical cysts. Overall echogenicity is slightly hyperechoic with poor corticomedullary distinction and a typical 1:3 cortex:medulla ratio. There is no evidence of focal perinephric inflammation or effusion. There is no evidence of nephroliths, infarcts or hydroureter. Renal vasculature is normal.

Adrenal Glands

The left adrenal gland is large and hypoechoic, measuring 1.02 cm at the cranial pole and 1.02 cm at the caudal pole. It is observed in its normal position cranial to the left renal artery. It is normal in appearance (uniformly hypoechoic) and shape with no evidence of a mass effect.

The right adrenal gland is large and hypoechoic, measuring 0.52 cm at the cranial pole and 1.08 cm at the caudal pole. It is observed in its normal position between the cranial aspect of the right kidney and the caudal vena cava. It is normal in appearance (uniformly hypoechoic) and shape with no evidence of a mass effect.

Spleen

The spleen is normal in size and shape, measuring 1.06 cm. The blood flow through the hilus and splenic parenchyma appears normal. There are pinpoint hyperechoic foci most consistent with dystrophic mineralization in the spleen.

Liver

The liver is large in size, and normal in echogenicity with smooth peripheral margins. The parenchyma is heterogenous in echotexture with subtle, indistinct focal mottling. The visible portions of the vasculature and biliary tract appear normal. There is a cystic lesion visualized on the left side measuring 0.56 cm in diameter.

PATIENT
Lola Espinosa

SPECIES
Canine

BREED
Shih Tzu

SEX
Spayed Female

AGE
15 Years

WEIGHT
13.4 lbs

INTERPRETED BY
Kathleen Sennello DVM, MS, Diplomate ACVIM (Small Animal Internal Medicine)

IMAGING PERFORMED BY
Gabriel Ferrer, DVM

HOSPITAL NAME
Pulse: Pet Ultrasound

REFERRING VET
Dr. Carlos Soto

INVOICE
74327

DATE
4/9/26

The gall bladder lumen is moderately distended. The wall of the gall bladder is not thickened and has a smooth mucosal surface. There is a moderate amount of non-organized echogenic debris. Some of the debris appears associated with the dependent portion of the hyperechoic gallbladder wall, possibly consistent with mild mineralized debris. The cystic and common bile ducts are normal/not visible.

Gastrointestinal

The stomach contains mild fluid. Most of the areas of the gastric wall appear normal. It measures at a normal thickness of 0.49 cm with some variability due to the presence of rugal folds. The distinction of the gastric wall layers is adequate and there is no impression of reduced peristaltic activity. There is a focal hypoechoic mass effect visualized within the lumen of the stomach, measuring 3.12 cm x 1.25 cm.

The visualized areas of duodenum, jejunum and ileum have a relatively uniform diameter with minimal fluid distension. Wall thickness is normal. Bowel loops follow a curvilinear path with distinct wall layering maintaining the typical 1:3 muscularis:mucosa layer ratio. Duodenum wall measures 0.42 cm. Jejunum wall measures 0.34 cm. Visualized peristalsis appears appropriate. There were no focal lesions consistent with obstruction or a mass effect observed.

The ileocecal junction was visualized and exhibited normal intact wall layering and is subjectively of normal thickness. Sections of colon are visualized with formed fecal material and gas shadowing distally. There is no observed focal or generalized colon wall thickening or loss of layering.

Pancreas

The pancreas is prominent and heterogeneous in the right limb. There is no evidence of nodules or cystic lesions. There is no evidence of regional mesenteric inflammation or fluid.

Free Abdomen

Evaluation of the peritoneal cavity did not reveal any evidence of effusion. There is significant lymph node enlargement in the cranial abdomen, most consistent with gastric and portal lymph nodes. An example measures 3.12 cm x 1.25 cm. Occasional prominent lymph nodes are visualized in other areas of the abdomen. A mesenteric lymph node is visualized measuring 0.25 cm. The omentum is mildly diffusely hyperechoic.

PRIMARY FINDINGS

- Thickened, irregular urinary bladder wall with small dependent mineralizations/small stones – Findings are most consistent with chronic cystitis. A neoplastic process is thought less likely.
- Bilateral adrenomegaly – The bilateral adrenomegaly could be consistent with bilateral hyperplasia (e.g., secondary to pituitary-dependent hyperadrenocorticism), bilateral infiltrative neoplasia, inflammatory adrenal disease, other. Correlation with clinical findings is recommended.
- Bilateral renal changes consistent with chronic renal disease and pyelectasia – Pyelectasia of the kidney(s)could be consistent with pyelonephritis, chronic renal disease, secondary to PU/PD or fluid therapy (if applicable), other.
- Large, heterogeneous liver with a small cystic lesion – The diffuse hepatic changes are non-specific and could be consistent with vacuolar hepatopathy, nodular hyperplasia, inflammatory/immune-mediated disease, fibrosis, extramedullary hematopoiesis, toxic

PATIENT

Lola Espinosa

SPECIES

Canine

BREED

Shih Tzu

SEX

Spayed Female

AGE

15 Years

WEIGHT

13.4 lbs

INTERPRETED BY

Kathleen Sennello DVM, MS, Diplomate ACVIM (Small Animal Internal Medicine)

IMAGING PERFORMED BY

Gabriel Ferrer, DVM

HOSPITAL NAME

Pulse: Pet Ultrasound

REFERRING VET

Dr. Carlos Soto

INVOICE

74327

DATE

4/9/26

hepatopathy (e.g., copper), infiltrative neoplasia (less likely) or other hepatopathy.

- Moderate gallbladder debris – The significance of the aggregated gallbladder debris is unclear. This could represent an early mucocele, cholestasis, or may be secondary to fasting but seems unlikely to be causing a current issue. Recommend continued monitoring.
- Rounded, hypoechoic gastric mass lesion – Findings could be consistent with a benign or neoplastic lesion (adenoma, carcinoma, round cell neoplasia, etc.). No evidence of an obstruction is visualized.
- Moderate to severe cranial abdominal lymphadenopathy – Findings are concerning for possible metastatic lymph nodes in the cranial abdomen.

SECONDARY FINDINGS

- Pancreatic changes most consistent with chronic pancreatic remodeling.

INTERPRETATION OF THE FINDINGS & FURTHER RECOMMENDATIONS

There is significant bladder wall thickening and irregularity as well as some small mineralizations. Additionally, both kidneys have significantly decreased corticomedullary distinction and significant pyelectasia. Findings are concerning for chronic cystitis and pyelonephritis. Recommend urinalysis and culture and potential treatment.

Both adrenals are large and the liver is heterogeneous with an elevation in ALP. Findings could be consistent with pituitary dependent hyperadrenocorticism. If clinically appropriate, consider adrenal function testing.

There is a rounded hypoechoic mass effect visualized within the stomach. This does not appear to be causing an obstruction at this time. This could represent a benign or neoplastic lesion. Further evaluation would likely involve upper GI endoscopy or surgical evaluation.

There are large lymph nodes visualized in the cranial abdomen. These are concerning for possible metastatic or highly reactive lymph nodes. If a safe window for sampling is available, consider a fine needle aspirate.

Recommend three view thoracic radiographs to evaluate for possible concurrent thoracic disease/involvement (disregard if this has already been done).

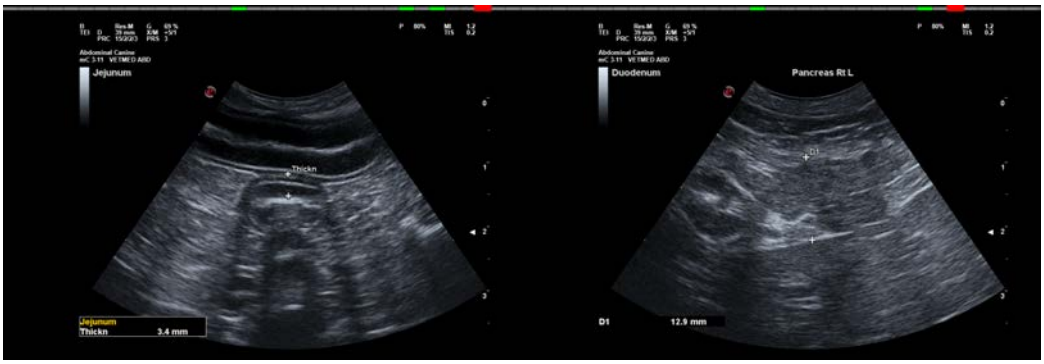

SonoPath

FOSTERING THE ART OF VETERINARY MEDICINE™

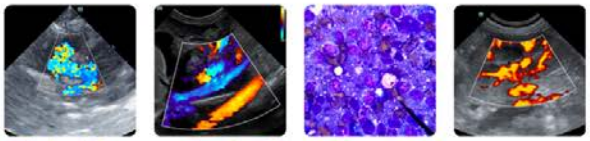

Clinical Sonography & Telecytology

Educational Teleconsultation Services™

SonoPath.com info@sonopath.com 1.800.838.4268

PATIENT

Lola Espinosa

SPECIES

Canine

BREED

Shih Tzu

SEX

Spayed Female

AGE

15 Years

WEIGHT

13.4 lbs

INTERPRETED BY

Kathleen Sennello DVM, MS, Diplomate ACVIM (Small Animal Internal Medicine)

IMAGING PERFORMED BY

Gabriel Ferrer, DVM

HOSPITAL NAME

Pulse: Pet Ultrasound

REFERRING VET

Dr. Carlos Soto

INVOICE

74327

DATE

4/9/26

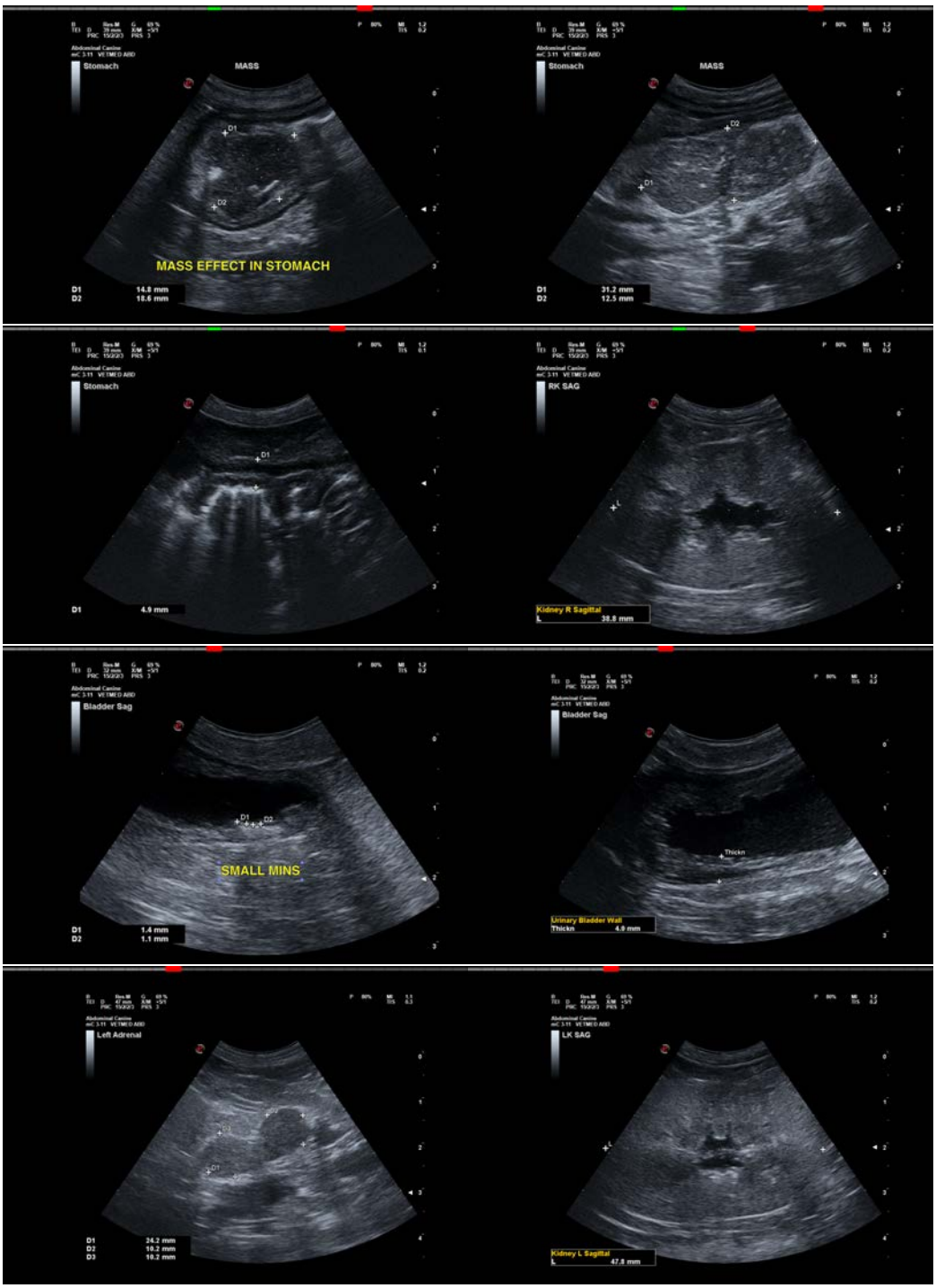

SonoPath
FOSTERING THE ART OF VETERINARY MEDICINE™

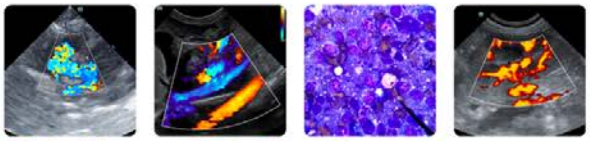

Clinical Sonography & Telecytology
Educational Teleconsultation Services™

SonoPath.com info@sonopath.com 1.800.838.4268

PATIENT

Lola Espinosa

SPECIES

Canine

BREED

Shih Tzu

SEX

Spayed Female

AGE

15 Years

WEIGHT

13.4 lbs

INTERPRETED BY

Kathleen Sennello DVM, MS, Diplomate ACVIM (Small Animal Internal Medicine)

IMAGING PERFORMED BY

Gabriel Ferrer, DVM

HOSPITAL NAME

Pulse: Pet Ultrasound

REFERRING VET

Dr. Carlos Soto

INVOICE

74327

DATE

4/9/26

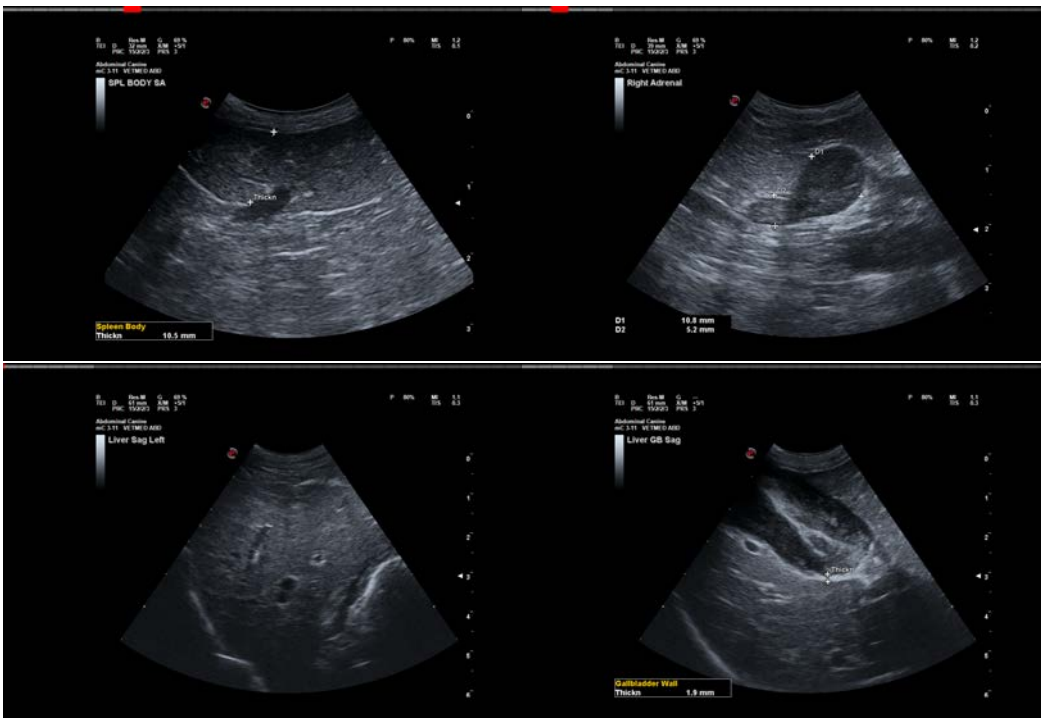

The information and recommendations provided are based on the images presented by the referring veterinarian/sonographer. No evaluation can be communicated regarding pathology that was not visible in the image/video clips provided.

Thank you for this referral. If the clinical or image interpretation does not parallel your findings or if I can be of any further assistance please contact me.

Kathleen Sennello DVM,MS, Diplomate ACVIM (Small animal Internal Medicine)

info@sonopath.com