



## PATIENT

Oreo Giangrandy

## SPECIES

Canine

## BREED

Havanese

## SEX

Neutered Male

## AGE

8

## WEIGHT

14.6

## INTERPRETED BY

Kathleen Sennello DVM,  
MS, Diplomate ACVIM  
(Small Animal Internal  
Medicine)

## IMAGING PERFORMED BY

Dr. Reyes

## HOSPITAL NAME

Graceful Paws Pet  
Clinic

## REFERRING VET

Dr. Reyes

## INVOICE

74311

## DATE

4/8/26

## PRESENTING CLINICAL SIGNS

Pet presented for ultrasound due to elevated liver enzymes. No clinical signs. Pet is currently on Denamarin.

Abnormal PE/Chem/CBC/UA Results: ALKP = 336 U/L H ( 23 - 212) ALT = 209 U/L H ( 10 - 125) AST: 65

## ULTRASONOGRAPHIC EXAMINATION OF THE ABDOMEN

### Urinary System

The urinary bladder is moderately distended with anechoic urine. The Bladder wall, trigone, ureteral papillae and visible urethra (to a depth of 2cm) appear normal with no evidence of wall thickening, mucosal irregularities, masses or cystic calculi.

The visualized areas of prostate and surrounding tissue appear normal. Unfortunately, the prostate is not fully visualized likely due to its intrapelvic location. Correlate with rectal exam findings.

The left kidney has a normal shape and size (3.76 cm) with pyelectasia at 0.20 cm. Overall echogenicity is slightly hyperechoic with poor corticomedullary distinction and a typical 1:3 cortex:medulla ratio. There is no evidence of focal perinephric inflammation or effusion. There is no evidence of pyelectasia, nephroliths, infarcts or hydroureter. Renal vasculature is normal.

The right kidney has a normal shape and size (3.72 cm). Overall echogenicity is slightly hyperechoic with mildly reduced corticomedullary distinction and a typical 1:3 cortex:medulla ratio. There is no evidence of focal perinephric inflammation or effusion. There is no evidence of pyelectasia, nephroliths, infarcts or hydroureter. Renal vasculature is normal.

### Adrenal Glands

The left adrenal gland is normal in size measuring 0.40 cm at the caudal pole. It is observed in its normal position cranial to the left renal artery. It is normal in appearance (uniformly hypoechoic) and shape with no evidence of a mass effect.

The right adrenal gland is not clearly visualized.

### Spleen

The spleen is subjectively normal in size (1.0 cm), echotexture is homogenous, and the splenic capsule is smooth with no irregularities. The blood flow through the hilus and splenic parenchyma appears normal. No focal parenchymal abnormalities are visualized.

### Liver

The liver is large in size with smooth peripheral margins. The parenchyma is hyperechoic and homogenous in echotexture. The visible portions of the vasculature and biliary tract appear normal. No focal nodules or cystic lesions are observed.

The gall bladder lumen is moderately distended. The wall of the gall bladder is not thickened and has a smooth mucosal surface. There is a moderate amount of non-organized echogenic debris. The cystic and common bile ducts are normal/not visible.



## PATIENT

Oreo Giangrandy

## SPECIES

Canine

## BREED

Havanese

## SEX

Neutered Male

## AGE

8

## WEIGHT

14.6

## INTERPRETED BY

Kathleen Sennello DVM,  
MS, Diplomate ACVIM  
(Small Animal Internal  
Medicine)

## IMAGING PERFORMED BY

Dr. Reyes

## HOSPITAL NAME

Graceful Paws Pet  
Clinic

## REFERRING VET

Dr. Reyes

## INVOICE

74311

## DATE

4/8/26

## Gastrointestinal

The stomach contains moderate fluid and shadowing ingesta. It measures at a normal thickness of <0.7cm with some variability due to the presence of rugal folds. The distinction of the gastric wall layers is adequate and there is no impression of reduced peristaltic activity. Shadowing ingesta interferes with full evaluation of the stomach.

The visualized areas of duodenum, jejunum and ileum have a relatively uniform diameter with minimal fluid distension. Wall thickness is normal. Bowel loops follow a curvilinear path with distinct wall layering maintaining the typical 1:3 muscularis:mucosa layer ratio. The duodenum measured as normal (between 0.3-0.5cm in wall thickness) and the jejunum measured as normal (between 0.2-0.47cm.) Visualized peristalsis appears appropriate. There were no focal lesions consistent with obstruction or a mass effect observed.

Sections of colon are visualized with formed fecal material and gas shadowing distally. There is no observed focal or generalized colon wall thickening or loss of layering.

## Pancreas

The area of the pancreas is normal and isoechoic to surrounding mesentery. There is no evidence of nodules or cystic lesions. There is no evidence of regional mesenteric inflammation or fluid.

## Free Abdomen

Evaluation of the peritoneal cavity did not reveal any evidence of effusion, or subjective lymphadenomegaly. The Medial iliac nodes appear normal and there was no evidence of a caudal aortic thrombus at the bifurcation. The omentum is of normal uniform echogenicity.

## ULTRASONOGRAPHIC FINDINGS

- Mild age related renal changes and left-sided pyelectasia noted – Pyelectasia of the left kidney could be consistent with pyelonephritis, chronic renal disease, secondary to PU/PD or fluid therapy (if applicable), other.
- Large, hyperechoic liver – The diffuse hepatic changes are non-specific and can be seen with vacuolar hepatopathy, reactive change, nodular hyperplasia or, less likely, inflammatory/immune-mediated disease, infiltrative neoplasia, or other hepatopathy.
- Moderate gallbladder debris – The significance of the aggregated gallbladder debris is unclear. This could represent an early mucocele, cholestasis, or may be secondary to fasting but seems unlikely to be causing a current issue. Recommend continued monitoring.
- Large fluid/shadowing ingesta visualized within the gastric lumen – Findings are most consistent with a non-fasted patient.

## INTERPRETATION OF THE FINDINGS & FURTHER RECOMMENDATIONS

No focal lesions were visualized associated with the liver to explain the elevation in liver enzymes reported. The parenchyma in general is somewhat hyperechoic, and the liver is large. Findings are most concerning for a primary hepatopathy such as a vacuolar hepatopathy, although other differentials such as infiltrative disease, inflammatory or infectious disease are also possible. Consider pre- and post-prandial bile acids to assess liver function and a fine needle aspirate of the liver (provided coagulation



**PATIENT**

Oreo Giangrandy

**SPECIES**

Canine

**BREED**

Havanese

**SEX**

Neutered Male

**AGE**

8

**WEIGHT**

14.6

**INTERPRETED BY**

Kathleen Sennello DVM,  
MS, Diplomate ACVIM  
(Small Animal Internal  
Medicine)

**IMAGING PERFORMED BY**

Dr. Reyes

**HOSPITAL NAME**

Graceful Paws Pet  
Clinic

**REFERRING VET**

Dr. Reyes

**INVOICE**

74311

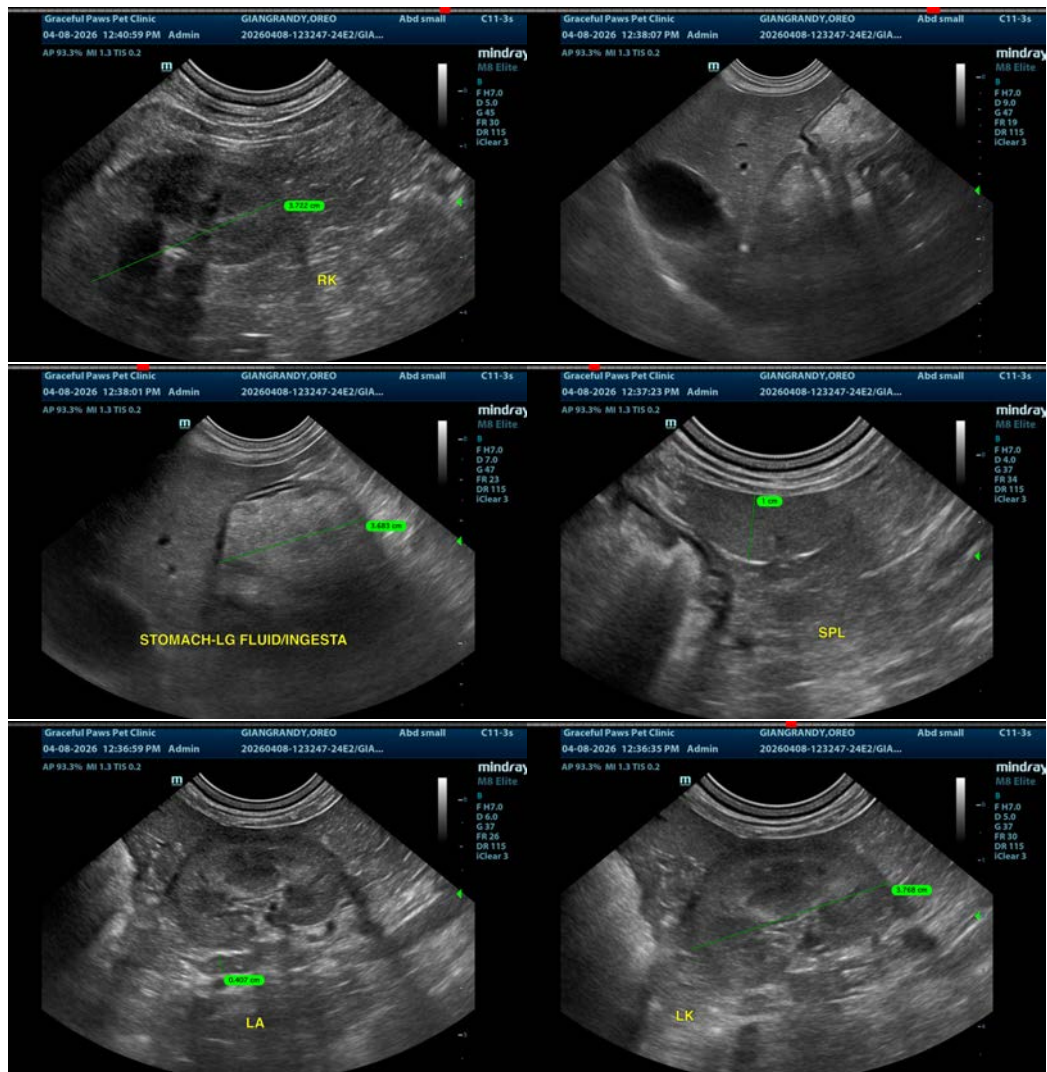
**DATE**

4/8/26

parameters are normal).

There is a moderate amount of gallbladder debris visualized with no evidence of wall thickening or significant inflammation. Options could include continued monitoring with ultrasound +/- starting Ursodiol therapy.

If liver values continue to rise and/or liver function is abnormal, ultimately biopsies of the liver may be necessary with samples for histopathology, culture and copper levels.



The information and recommendations provided are based on the images presented by the referring veterinarian/sonographer. No evaluation can be communicated regarding pathology that was not visible in the image/video clips provided.

Thank you for this referral. If the clinical or image interpretation does not parallel your findings or if I can be of any further assistance please contact me.

Kathleen Sennello DVM,MS, Diplomate ACVIM (Small animal Internal Medicine) info@sonopath.com