

**PATIENT**

Belly Rotondo

SPECIES

Canine

BREED

Shih Tzu x Pug

SEX

Spayed Female

AGE

10 Years

WEIGHT

6.11 kg

INTERPRETED BYKathleen Sennello DVM,
MS, Diplomate ACVIM
(Small Animal Internal
Medicine)**IMAGING
PERFORMED BY**

Dr. Abby Gerenser

HOSPITAL NAMEAbby Road Veterinary
Hospital**REFERRING VET**

Dr. Abby Gerenser

INVOICE

74318

DATE

4/8/26

PRESENTING CLINICAL SIGNS

Patient presented for vomiting in morning with lip smacking and slight decrease in interest in food. Is on hypoallergenic diet for previous GI issues.

Abnormal PE/Chem/CBC/UA Results: Increased Lipase, amylase, cholesterol

ULTRASONOGRAPHIC EXAMINATION OF THE ABDOMEN**Urinary System**

The urinary bladder is moderately distended with anechoic urine. The Bladder wall, trigone, ureteral papillae and visible urethra (to a depth of 2cm) appear normal with no evidence of wall thickening, mucosal irregularities, masses or cystic calculi.

The left kidney has a normal shape and size (3.47 cm). Overall echogenicity is normal with adequate corticomedullary distinction and a typical 1:3 cortex:medulla ratio. There is no evidence of focal perinephric inflammation or effusion. There is no evidence of pyelectasia, nephroliths, infarcts or hydroureter. Renal vasculature is normal.

The right kidney has a normal shape and size (4.15 cm). Overall echogenicity is normal with adequate corticomedullary distinction and a typical 1:3 cortex:medulla ratio. There is no evidence of focal perinephric inflammation or effusion. There is no evidence of pyelectasia, nephroliths, infarcts or hydroureter. Renal vasculature is normal.

Adrenal Glands

The left adrenal gland is normal in size measuring 0.35 cm at the cranial pole and 0.30 cm at the caudal pole. It is observed in its normal position cranial to the left renal artery. It is normal in appearance (uniformly hypoechoic) and shape with no evidence of a mass effect.

The right adrenal gland is normal in size measuring 0.65 cm at the cranial pole and 0.40 cm at the caudal pole. It is observed in its normal position between the cranial aspect of the right kidney and the caudal vena cava. It is normal in appearance (uniformly hypoechoic) and shape with no evidence of a mass effect.

Spleen

The spleen is subjectively normal in size (1.13 cm), echotexture is homogenous, and the splenic capsule is smooth with no irregularities. The blood flow through the hilus and splenic parenchyma appears normal. No focal parenchymal abnormalities are visualized.

Liver

The liver is subjectively normal in size, and echogenicity with smooth peripheral margins. The parenchyma is homogenous echotexture. The visible portions of the vasculature and biliary tract appear normal. No focal nodules or cystic lesions are observed.

The gall bladder lumen is moderately distended. The wall of the gall bladder is not thickened and has a smooth mucosal surface. There is a moderate amount of non-organized echogenic debris. The cystic and common bile ducts are normal/not visible.



PATIENT

Belly Rotondo

SPECIES

Canine

BREED

Shih Tzu x Pug

SEX

Spayed Female

AGE

10 Years

WEIGHT

6.11 kg

INTERPRETED BY

Kathleen Sennello DVM,
MS, Diplomate ACVIM
(Small Animal Internal
Medicine)

IMAGING PERFORMED BY

Dr. Abby Gerenser

HOSPITAL NAME

Abby Road Veterinary
Hospital

REFERRING VET

Dr. Abby Gerenser

INVOICE

74318

DATE

4/8/26

Gastrointestinal

The stomach contains minimal luminal contents. It measures at a normal thickness of 0.40 cm with some variability due to the presence of rugal folds. The distinction of the gastric wall layers is adequate and there is no impression of reduced peristaltic activity. No masses or focal lesions were observed.

The visualized areas of duodenum, jejunum and ileum have a relatively uniform diameter with minimal fluid distension. Wall thickness is normal. Bowel loops follow a curvilinear path with distinct wall layering maintaining the typical 1:3 muscularis:mucosa layer ratio. Duodenum wall measures 0.51 cm. Jejunum wall measures 0.38 cm. Visualized peristalsis appears appropriate. There were no focal lesions consistent with obstruction or a mass effect observed.

Sections of colon are visualized with formed fecal material and gas shadowing distally. There is no observed focal or generalized colon wall thickening or loss of layering.

Pancreas

The pancreas is visible/mildly mottled in both limbs. There is no evidence of nodules or cystic lesions. There is no evidence of regional mesenteric inflammation or fluid.

Free Abdomen

Evaluation of the peritoneal cavity did not reveal any evidence of effusion, or subjective lymphadenomegaly. The Medial iliac nodes appear normal and there was no evidence of a caudal aortic thrombus at the bifurcation. The omentum is of normal uniform echogenicity.

ULTRASONOGRAPHIC FINDINGS

- Pancreatic changes most consistent with chronic pancreatic remodeling. Mild chronic pancreatitis can't be ruled out.
- Moderate gallbladder debris – The significance of the aggregated gallbladder debris is unclear. This could represent an early mucocele, cholestasis, or may be secondary to fasting but seems unlikely to be causing a current issue. Recommend continued monitoring.

INTERPRETATION OF THE FINDINGS & FURTHER RECOMMENDATIONS

The changes observed on today's scan are relatively mild. No focal lesions were visualized associated with the GI tract to explain the nausea and vomiting reported. Correlate these findings with fasted cholesterol levels. If these are significantly elevated, hyperlipidemia can cause abdominal discomfort. Additionally, correlate with a quantitative PLI level, looking for evidence of active pancreatitis.

If further evaluation for underlying gastrointestinal disease is considered, recommend the following:

- Consider a combination ultra low-fat/hydrolyzed protein prescription diet (Royal Canin has this combination).
- Consider a GI panel to Texas A&M for evaluation of B12 levels, folate, PLI/TLI etc.. to further evaluate for pancreatic/small intestinal disease.
- Recommend chronic probiotic therapy.



PATIENT

Belly Rotondo

SPECIES

Canine

BREED

Shih Tzu x Pug

SEX

Spayed Female

AGE

10 Years

WEIGHT

6.11 kg

INTERPRETED BY

Kathleen Sennello DVM,
MS, Diplomate ACVIM
(Small Animal Internal
Medicine)

**IMAGING
PERFORMED BY**

Dr. Abby Gerenser

HOSPITAL NAME

Abby Road Veterinary
Hospital

REFERRING VET

Dr. Abby Gerenser

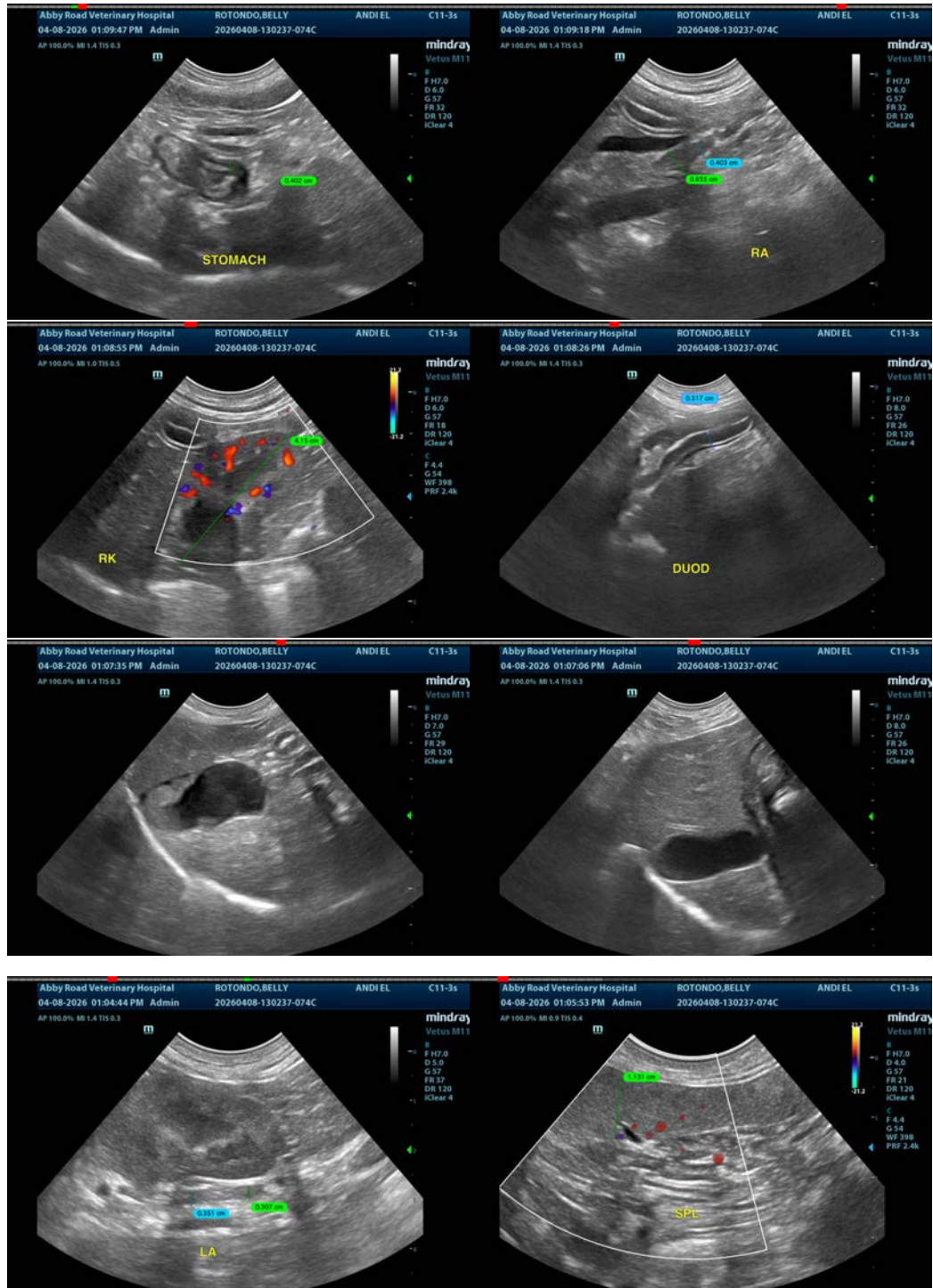
INVOICE

74318

DATE

4/8/26

If symptoms are persistent or progressive, ultimately biopsies of the GI tract may be warranted. Additionally, you could consider repeat imaging prior to this, looking for the development of new lesions or the progression of the changes observed on today's scan.





PATIENT

Belly Rotondo

SPECIES

Canine

BREED

Shih Tzu x Pug

SEX

Spayed Female

AGE

10 Years

WEIGHT

6.11 kg

INTERPRETED BY

Kathleen Sennello DVM,
MS, Diplomate ACVIM
(Small Animal Internal
Medicine)

IMAGING PERFORMED BY

Dr. Abby Gerenser

HOSPITAL NAME

Abby Road Veterinary
Hospital

REFERRING VET

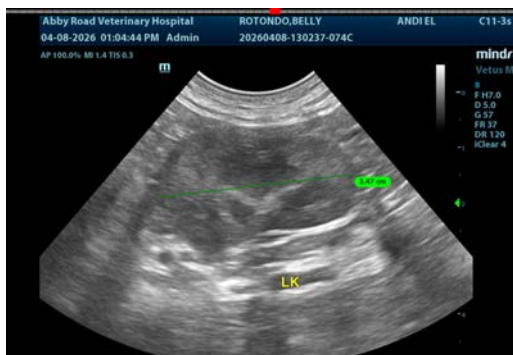
Dr. Abby Gerenser

INVOICE

74318

DATE

4/8/26



The information and recommendations provided are based on the images presented by the referring veterinarian/sonographer. No evaluation can be communicated regarding pathology that was not visible in the image/video clips provided.

Thank you for this referral. If the clinical or image interpretation does not parallel your findings or if I can be of any further assistance please contact me.

Kathleen Sennello DVM,MS, Diplomate ACVIM (Small animal Internal Medicine)

info@sonopath.com