



PATIENT

Rona Fazio

SPECIES

Canine

BREED

Standard Poodle

SEX

Spayed Female

AGE

8 Years

WEIGHT

26 kg

INTERPRETED BY

Kathleen Sennello DVM,
 MS, Diplomate ACVIM
 (Small Animal Internal
 Medicine)

IMAGING PERFORMED BY

Crystal Hill

HOSPITAL NAME

Tansley Woods
 Veterinary Hospital

REFERRING VET

Dr. Petrowski

INVOICE

74248

DATE

4/7/26

PRESENTING CLINICAL SIGNS

Scheduled for tumor excision and pre anesthetic profile all WNL other than ALT 438. Want US to rule out something more significant going on with the liver prior to surgery. NO meds

Abnormal PE/Chem/CBC/UA Results: Elevated ALT

ULTRASONOGRAPHIC EXAMINATION OF THE ABDOMEN

Urinary System

The urinary bladder is moderately distended with anechoic urine. The Bladder wall, trigone, ureteral papillae and visible urethra (to a depth of 2cm) appear normal with no evidence of wall thickening, mucosal irregularities, masses or cystic calculi.

The left kidney has a normal shape and size (5.92 cm). Overall echogenicity is normal with adequate corticomedullary distinction and a typical 1:3 cortex:medulla ratio. There is no evidence of focal perinephric inflammation or effusion. There is no evidence of pyelectasia, nephroliths, infarcts or hydroureter. Renal vasculature is normal.

The right kidney has a normal shape and size (7.23 cm). Overall echogenicity is normal with adequate corticomedullary distinction and a typical 1:3 cortex:medulla ratio. There is no evidence of focal perinephric inflammation or effusion. There is no evidence of pyelectasia, nephroliths, infarcts or hydroureter. Renal vasculature is normal.

Adrenal Glands

The left adrenal gland is normal in size measuring 0.70 cm at the cranial pole and 0.62 cm at the caudal pole. It is observed in its normal position cranial to the left renal artery. It is normal in appearance (uniformly hypoechoic) and shape with no evidence of a mass effect.

The region of the right adrenal (between right cranial kidney and vena cava) is unremarkable, but the adrenal is not distinctly visualized. No evidence of a mass effect is visualized.

Spleen

The spleen is subjectively normal in size (1.66 cm), echotexture is homogenous, and the splenic capsule is smooth with no irregularities. The blood flow through the hilus and splenic parenchyma appears normal. No focal parenchymal abnormalities are visualized.

Liver

The liver is subjectively normal in size, and echogenicity with smooth peripheral margins. The parenchyma is homogenous echotexture. The visible portions of the vasculature and biliary tract appear normal. No focal nodules or cystic lesions are observed.

The gall bladder lumen is moderately distended. The wall of the gall bladder is not thickened and has a smooth mucosal surface. Luminal contents are mild and likely incidental at this time. The cystic and common bile ducts are normal/not visible.



PATIENT

Rona Fazio

SPECIES

Canine

BREED

Standard Poodle

SEX

Spayed Female

AGE

8 Years

WEIGHT

26 kg

INTERPRETED BY

Kathleen Sennello DVM,
 MS, Diplomate ACVIM
 (Small Animal Internal
 Medicine)

IMAGING PERFORMED BY

Crystal Hill

HOSPITAL NAME

Tansley Woods
 Veterinary Hospital

REFERRING VET

Dr. Petrowski

INVOICE

74248

DATE

4/7/26

Gastrointestinal

The stomach contains moderate fluid/shadowing ingesta. It measures at a normal thickness of <0.7cm with some variability due to the presence of rugal folds. The distinction of the gastric wall layers is adequate and there is no impression of reduced peristaltic activity. Shadowing ingesta and fluid interfere with full evaluation of the stomach. Shadowing ingesta and fluid interfere with full evaluation of the stomach.

The visualized areas of duodenum, jejunum and ileum have a relatively uniform diameter with minimal fluid distension. Wall thickness is normal. Bowel loops follow a curvilinear path with distinct wall layering maintaining the typical 1:3 muscularis:mucosa layer ratio. Jejunum wall measures 0.34 cm. Visualized peristalsis appears appropriate. There were no focal lesions consistent with obstruction or a mass effect observed.

Sections of colon are visualized with formed fecal material and gas shadowing distally. There is no observed focal or generalized colon wall thickening or loss of layering.

Pancreas

The area of the pancreas is normal and isoechoic to surrounding mesentery. There is no evidence of nodules or cystic lesions. There is no evidence of regional mesenteric inflammation or fluid.

Free Abdomen

Evaluation of the peritoneal cavity did not reveal any evidence of effusion, or subjective lymphadenomegaly. The Medial iliac nodes appear normal and there was no evidence of a caudal aortic thrombus at the bifurcation. The omentum is of normal uniform echogenicity.

ULTRASONOGRAPHIC FINDINGS

- No significant ultrasonographic lesions visualized.

INTERPRETATION OF THE FINDINGS & FURTHER RECOMMENDATIONS

No structural abnormalities are visualized associated with the liver on today's exam. Findings are suggestive of a primary hepatopathy. Further evaluation could include pre- and post-prandial bile acids to assess liver function and possibly a fine needle aspirate. If clinically appropriate, you could consider screening for Leptospirosis.

If liver values are persistently elevated, ultimately biopsies of the liver with samples for histopathology, culture and copper levels are warranted. If there is any concern for acute liver injury, you could consider a course of Ursodiol, Denamarin +/- antibiotics prior to considering biopsy.



PATIENT

Rona Fazio

SPECIES

Canine

BREED

Standard Poodle

SEX

Spayed Female

AGE

8 Years

WEIGHT

26 kg

INTERPRETED BY

Kathleen Sennello DVM,
 MS, Diplomate ACVIM
 (Small Animal Internal
 Medicine)

**IMAGING
 PERFORMED BY**

Crystal Hill

HOSPITAL NAME

Tansley Woods
 Veterinary Hospital

REFERRING VET

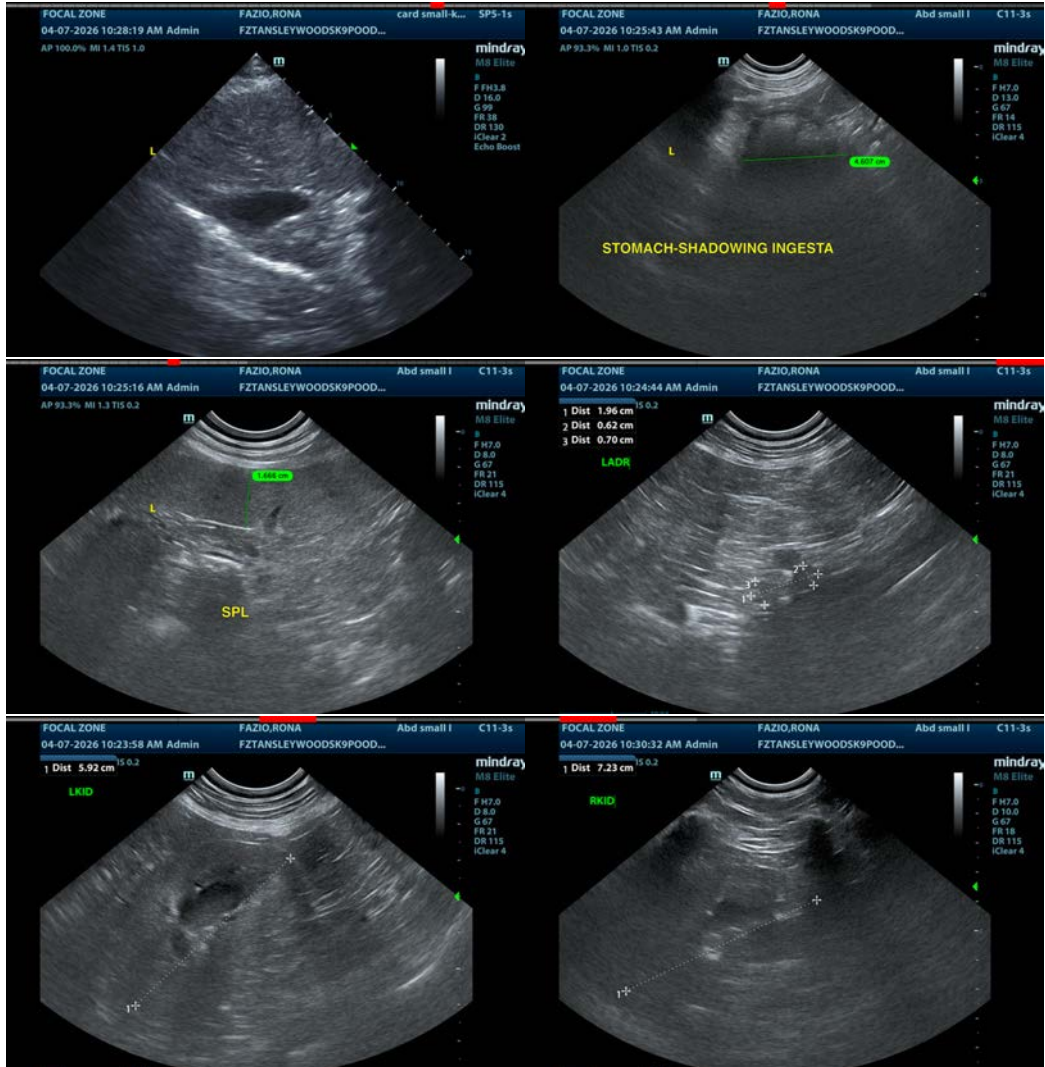
Dr. Petrowski

INVOICE

74248

DATE

4/7/26



The information and recommendations provided are based on the images presented by the referring veterinarian/sonographer. No evaluation can be communicated regarding pathology that was not visible in the image/video clips provided.

Thank you for this referral. If the clinical or image interpretation does not parallel your findings or if I can be of any further assistance please contact me.

Kathleen Sennello DVM,MS, Diplomate ACVIM (Small animal Internal Medicine)

info@sonopath.com