


**DATE PRESENTING CLINICAL SIGNS**

4/7/26

**PATIENT**

Noodle Warble

**SPECIES**

Feline

**BREED**

DSH

**SEX**

Spayed Female

**AGE**

1/1/13

**WEIGHT**

4 lbs

**INTERPRETED BY**

 Kathleen Sennello DVM,  
 MS, Diplomate ACVIM  
 (Small Animal Internal  
 Medicine)

**HOSPITAL NAME**

 Cat Sense Feline  
 Hospital

**REFERRING VET**

Dr. Sinclair

**INVOICE**

74279

**Patient History:** Noodle presented for chronic congestion and weight loss. She had been a feral cat that has since been tamed. She often "sounds like an oxygen tank while breathing." Her stomach always make noises. She has recently lost weight. On PE she was very thin with almost no muscling and she has chronic UR congestion that I believe makes her swallow a lot of air. No heart murmur was auscultated. Her entire GI tract was full of air on the radiograph, especially the stomach. Bloodwork shows a significant non-regenerative anemia, mild azotemia, hyperglobulinemia and an extremely elevated BNP. She was initially started on azithromycin but was switched to doxycycline when the anemia was found just in case of an early Mycoplasma Haemofelis.

**Current Medications:** Doxycycline 10mg bid, Simethicone infant drops -0.3ml tid-qid

**Labwork Results:** Attached, reported as: HCT=17%, BUN=49, globulins=7.0, BNP=1500

**Date of Previous IntraPet Ultrasound:** No previous.

**Sedation:** Not required to complete full diagnostic ultrasound.

**Stat Report:** Not requested.

**Imaging Performed by:** Stephanie Warga RDCS, RVT.

**ULTRASONOGRAPHIC EXAMINATION OF THE ABDOMEN**
**Urinary System**

The urinary bladder is moderately distended with anechoic urine. The Bladder wall, trigone, ureteral papillae and visible urethra (to a depth of 2cm) appear normal with no evidence of wall thickening, mucosal irregularities, masses or cystic calculi.

The left kidney has a normal shape and size (3.23 cm). Overall echogenicity is slightly hyperechoic with poor corticomedullary distinction and a typical 1:3 cortex:medulla ratio. There is no evidence of focal perinephric inflammation or effusion. There is no evidence of pyelectasia, nephroliths, infarcts or hydroureter. Renal vasculature is normal.

The right kidney has a normal shape and size (2.9 cm) with pinpoint non-obstructive mineralizations. Overall echogenicity is slightly hyperechoic with poor corticomedullary distinction and a typical 1:3 cortex:medulla ratio. There is no evidence of focal perinephric inflammation or effusion. There is no evidence of pyelectasia, infarcts or hydroureter. Renal vasculature is normal.

**Adrenal Glands**

The left adrenal gland is normal in size measuring 0.31 cm at the caudal pole. It is observed in its normal position cranial to the left renal artery. It is normal in appearance (uniformly hypoechoic) and shape with no evidence of a mass effect.

The right adrenal gland is normal in size measuring 0.37 cm at the caudal pole. It is observed in its normal position between the cranial aspect of the right kidney and the caudal vena cava. It is normal in appearance (uniformly hypoechoic) and shape with no evidence of a mass effect.

**Spleen**

The spleen is subjectively normal in size (1.03 cm), echotexture is homogenous, and the splenic capsule is smooth with no irregularities. The blood flow through the hilus and splenic parenchyma appears normal. No focal parenchymal abnormalities are visualized.

### ***Liver***

The liver is subjectively normal in size, and echogenicity with smooth peripheral margins. The parenchyma is homogenous echotexture. The visible portions of the vasculature and biliary tract appear normal. No focal nodules or cystic lesions are observed.

The gall bladder lumen is moderately distended. The wall of the gall bladder is not thickened and has a smooth mucosal surface. Luminal contents are mild and likely incidental at this time. The bile duct appears dilated and somewhat tortuous, measuring up to 0.25 cm.

### ***Gastrointestinal***

The stomach contains minimal luminal contents. It measures at a normal thickness of <0.36cm with some variability due to the presence of rugal folds. The distinction of the gastric wall layers is adequate and there is no impression of reduced peristaltic activity. No masses or focal lesions were observed.

The visualized areas of duodenum, jejunum and ileum have a uniform diameter with minimal fluid distension. Wall thickness is normal to slightly increased. Bowel loops follow a typical curvilinear path with distinct wall layering, but some areas display a prominent muscularis layer which does not display the typical 1:3 muscularis:mucosa layer ratio. Duodenum wall measures 0.23 cm. Jejunum wall measures 0.25 cm. Visualized peristalsis appears appropriate. There were no focal lesions consistent with obstruction or a mass effect observed.

The ileocecal junction was visualized and exhibited normal intact wall layering and is subjectively of normal thickness. Sections of colon are visualized with non-formed/liquid fecal material and gas shadowing distally. There is no observed focal or generalized colon wall thickening or loss of layering.

### ***Pancreas***

The right limb of the pancreas is prominent and hypoechoic as compared to the surrounding isoechoic mesentery. There is no evidence of nodules or cystic lesions. There is no evidence of regional mesenteric inflammation or fluid. Prominent pancreatic duct noted at 0.23 cm.

### ***Free Abdomen***

There is a small amount of free fluid visualized in the cranial abdomen. There are occasional prominent mesenteric lymph nodes. Examples measure 0.29 cm and 0.31 cm. The omentum is slightly hyperechoic in the cranial abdomen in the region of the right limb of the pancreas and the bile duct.

## **ULTRASONOGRAPHIC FINDINGS**

- Age related changes visualized associated with both kidneys.
- Pancreatic changes most consistent with chronic pancreatic remodeling +/- chronic active pancreatitis in the right limb.
- Mildly dilated/tortuous bile duct – Dilation of the common bile duct could be consistent with a functional obstruction (i.e. primary hepatic disease resulting in hepatocellular swelling) or with an extrahepatic bile duct obstruction (ie. choledocholith, bile duct tumor, pancreatic disease, other).
- Diffusely mildly ropey/thickened small intestine with some areas exhibiting a prominent muscularis layer – The small intestinal wall changes are most consistent with an inflammatory process (i.e., inflammatory bowel disease) with a low possibility of emerging lymphoma.

- Small volume free abdominal fluid and prominent mesenteric lymph nodes.

## INTERPRETATION OF THE FINDINGS & FURTHER RECOMMENDATIONS

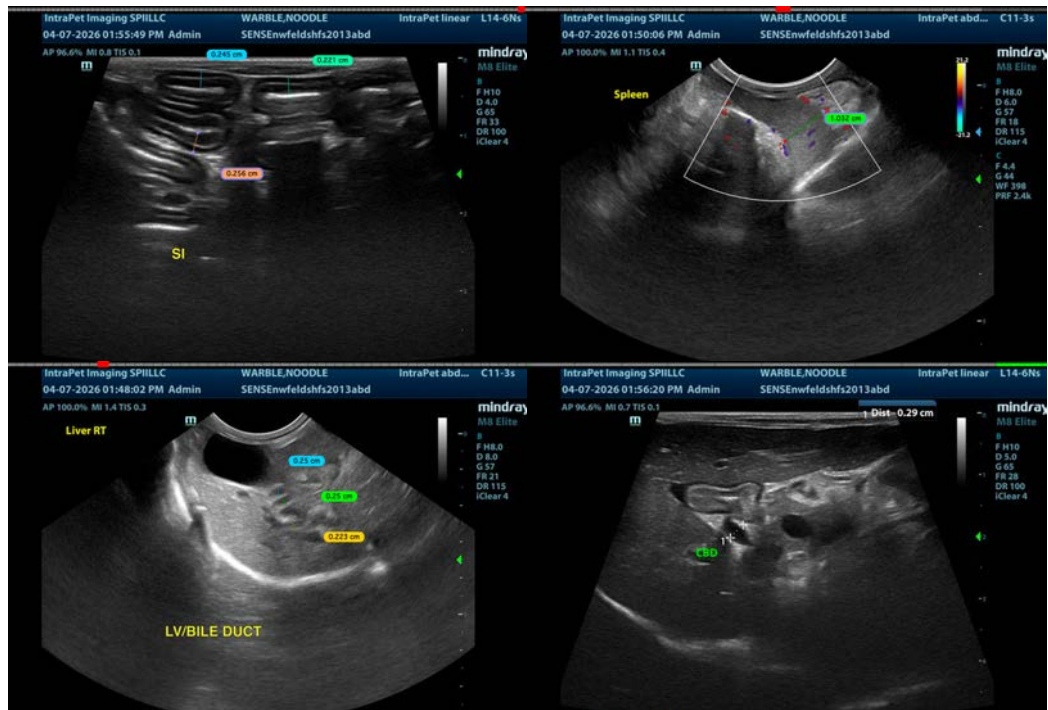
The renal changes observed are most consistent with early chronic renal disease. Recommend a blood pressure, urinalysis and culture as a baseline (if not already done).

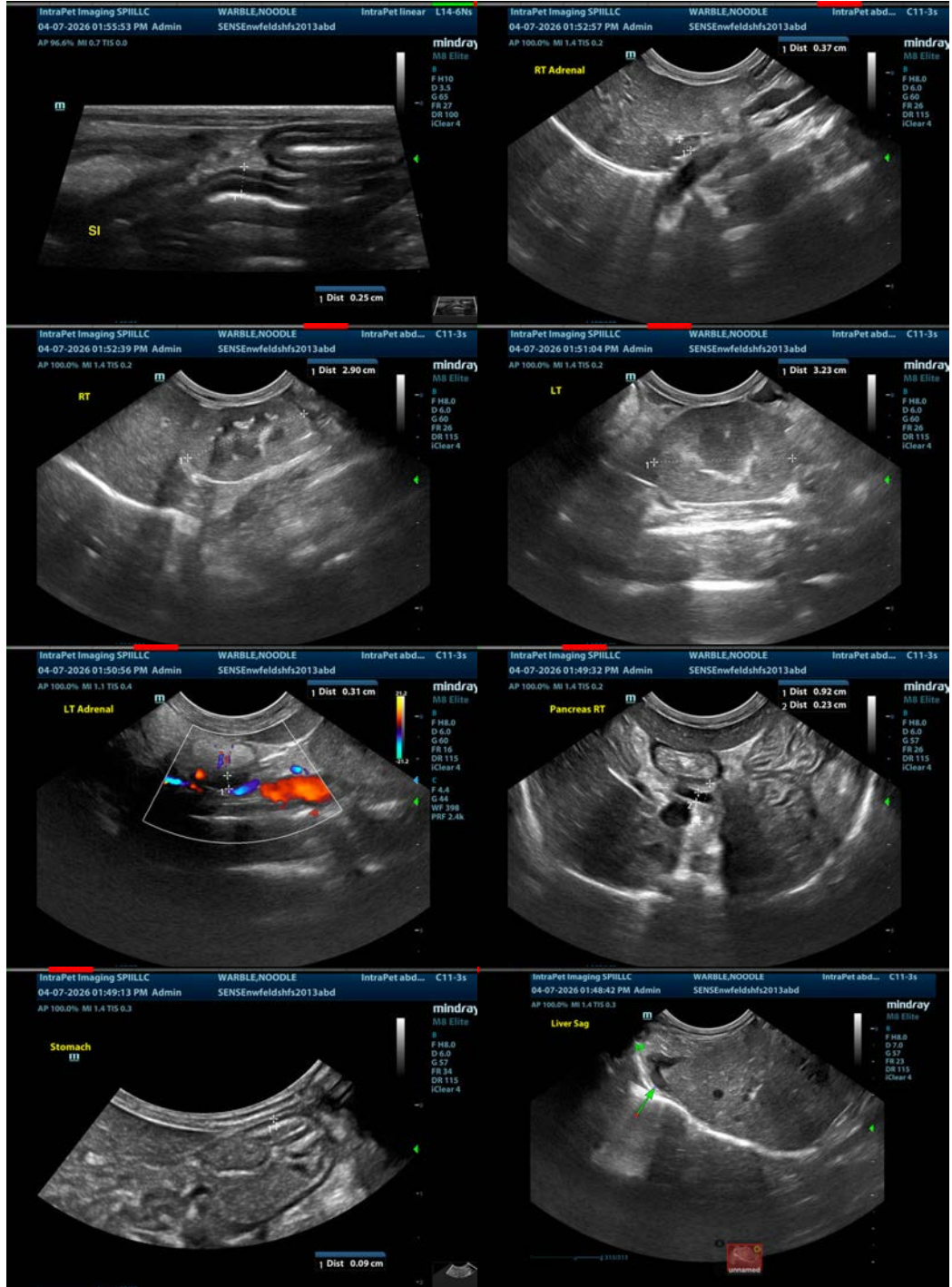
The right limb of the pancreas is prominent. Correlate with a PLI level. If this is significantly elevated, consider empirical treatment for chronic pancreatitis.

The bile duct appears dilated and somewhat tortuous. The significance of this in the absence of liver enzyme elevations is uncertain. You could consider continued monitoring and chronic Ursodiol therapy.

The small intestine appears mildly “ropey” with a prominent muscularis layer. This could be indicative of an underlying mild enteropathy. If initial further evaluation is desired, consider a GI panel to Texas A&M for a qualitative fPLI, TLI, cobalamin and folate. If values are indicative of small intestinal disease, further workup may be warranted.

There are many age related changes visualized on today’s abdominal study. Additionally, based on history, upper respiratory disease sounds like a significant finding. Consider a contrast CT scan to look for possible mass effect, etc., which could be contributing to some of the symptoms described.





**The information and recommendations provided are based on the images presented by the referring veterinarian/sonographer. No evaluation can be communicated regarding pathology that was not visible in the image/video clips provided.**

Thank you for this referral. If the clinical or image interpretation does not parallel your findings or if I can be of any further assistance please contact me.

Kathleen Sennello DVM,MS, Diplomate ACVIM (Small animal Internal Medicine)  
info@sonopath.com