



PATIENT

Ned Vaughn

SPECIES

Canine

BREED

Australian Shepherd x

SEX

Neutered Male

AGE

6 Years 6 Months

WEIGHT

62.6 lbs

INTERPRETED BY

Kathleen Sennello DVM,
 MS, Diplomate ACVIM
 (Small Animal Internal
 Medicine)

IMAGING PERFORMED BY

Kathleen Byrnes

HOSPITAL NAME

Stoney Creek
 Veterinary Hospital

REFERRING VET

Dr. Eldred

INVOICE

74263

DATE

4/7/26

PRESENTING CLINICAL SIGNS

P presented for US. Previous US in 7/25-2 small cystic calculi, mild right peridiverticular mineralization, Mild cholecystic debris.

ULTRASONOGRAPHIC EXAMINATION OF THE ABDOMEN

Urinary System

The urinary bladder is moderately distended with mildly echogenic urine. The Bladder wall appears of normal thickness with a smooth mucosal surface. In the dependent portion of the bladder there are hyperechoic shadowing foci most consistent with two stones, one measuring approximately 1.06 cm, the other measuring 1.03 cm. The region of the trigone, ureteral papillae and proximal urethra appear free of any mass lesions or calculi.

The prostate is normal in size (0.87 cm) and shape for this neutered male dog. The parenchyma is homogenous and the external margins are smooth. The prostatic urethra appears normal with no evidence of irregularity, invasion, mass effect or calculi.

The left kidney has a normal shape and size (5.39 cm) with small cortical mineralizations. Overall echogenicity is normal with adequate corticomedullary distinction and a typical 1:3 cortex:medulla ratio. There is no evidence of focal perinephric inflammation or effusion. There is no evidence of pyelectasia, infarcts or hydroureter. Renal vasculature is normal.

The right kidney has a normal shape and size (6.15 cm) with small cortical mineralizations. Overall echogenicity is normal with adequate corticomedullary distinction and a typical 1:3 cortex:medulla ratio. There is no evidence of focal perinephric inflammation or effusion. There is no evidence of pyelectasia, infarcts or hydroureter. Renal vasculature is normal.

Adrenal Glands

The left adrenal gland is normal in size measuring 0.69 cm at the cranial pole and 0.56 cm at the caudal pole. It is observed in its normal position cranial to the left renal artery. It is normal in appearance (uniformly hypoechoic) and shape with no evidence of a mass effect.

The right adrenal gland is normal in size measuring 0.82 cm at the cranial pole eand 0.74 cm at the caudal pole. It is observed in its normal position between the cranial aspect of the right kidney and the caudal vena cava. It is normal in appearance (uniformly hypoechoic) and shape with no evidence of a mass effect.

Spleen

The spleen is subjectively normal in size (1.92 cm), echotexture is homogenous, and the splenic capsule is smooth with no irregularities. The blood flow through the hilus and splenic parenchyma appears normal. No focal parenchymal abnormalities are visualized.

Liver

The liver is normal/borderline small in size, and normal in echogenicity with smooth peripheral margins. The parenchyma is homogenous echotexture. The visible portions of the vasculature and biliary tract appear normal. No focal nodules or cystic lesions are observed.



PATIENT

Ned Vaughn

The gall bladder lumen is moderately distended. The wall of the gall bladder is not thickened and has a smooth mucosal surface. Luminal contents are mild and likely incidental at this time. The cystic and common bile ducts are normal/not visible.

SPECIES

Canine

Gastrointestinal

The stomach contains minimal luminal contents. It measures at a normal thickness of <0.7cm with some variability due to the presence of rugal folds. The distinction of the gastric wall layers is adequate and there is no impression of reduced peristaltic activity. No masses or focal lesions were observed.

BREED

Australian Shepherd x

The visualized areas of duodenum, jejunum and ileum have a relatively uniform diameter with minimal fluid distension. Wall thickness is normal. Bowel loops follow a curvilinear path with distinct wall layering maintaining the typical 1:3 muscularis:mucosa layer ratio. Duodenum wall measures 0.43 cm. Jejunum wall measures 0.30 cm. Visualized peristalsis appears appropriate. There were no focal lesions consistent with obstruction or a mass effect observed.

SEX

Neutered Male

Sections of colon are visualized with formed fecal material and gas shadowing distally. There is no observed focal or generalized colon wall thickening or loss of layering.

AGE

6 Years 6 Months

Pancreas

The pancreas is normal and isoechoic to surrounding mesentery. There is no evidence of nodules or cystic lesions. There is no evidence of regional mesenteric inflammation or fluid.

WEIGHT

62.6 lbs

Free Abdomen

Evaluation of the peritoneal cavity did not reveal any evidence of effusion, or subjective lymphadenomegaly. The Medial iliac nodes appear normal and there was no evidence of a caudal aortic thrombus at the bifurcation. The omentum is of normal uniform echogenicity.

INTERPRETED BY

Kathleen Sennello DVM,
 MS, Diplomate ACVIM
 (Small Animal Internal
 Medicine)

ULTRASONOGRAPHIC FINDINGS

- Two shadowing calculi visualized in the urinary bladder – Correlate with urinalysis, culture and radiographs.
- Normal/borderline small liver – The significance of this is uncertain. This could be normal for this individual. Correlate with current labs, radiographic findings +/- liver function test.
- Mild peri diverticular mineralization – The significance of this is currently unclear. This is likely an incidental finding at this time.

IMAGING PERFORMED BY

Kathleen Byrnes

INTERPRETATION OF THE FINDINGS & FURTHER RECOMMENDATIONS

There are two shadowing stones visualized in the urinary bladder. Correlate these findings with a urinalysis, culture and radiographs to better assess the number and size of stones present. There is some mild mineralization in the kidneys. No evidence of an obstruction is present at this time.

HOSPITAL NAME

Stoney Creek
 Veterinary Hospital

Subjectively, the liver is normal to slightly small in size. This is likely within normal limits for this individual. If there is any concern for abnormal liver function or similar or could consider pre- and post-prandial bile acids.

REFERRING VET

Dr. Eldred

INVOICE

74263

DATE

4/7/26



PATIENT

Ned Vaughn

SPECIES

Canine

BREED

Australian Shepherd x

SEX

Neutered Male

AGE

6 Years 6 Months

WEIGHT

62.6 lbs

INTERPRETED BY

Kathleen Sennello DVM,
 MS, Diplomate ACVIM
 (Small Animal Internal
 Medicine)

IMAGING PERFORMED BY

Kathleen Byrnes

HOSPITAL NAME

Stoney Creek
 Veterinary Hospital

REFERRING VET

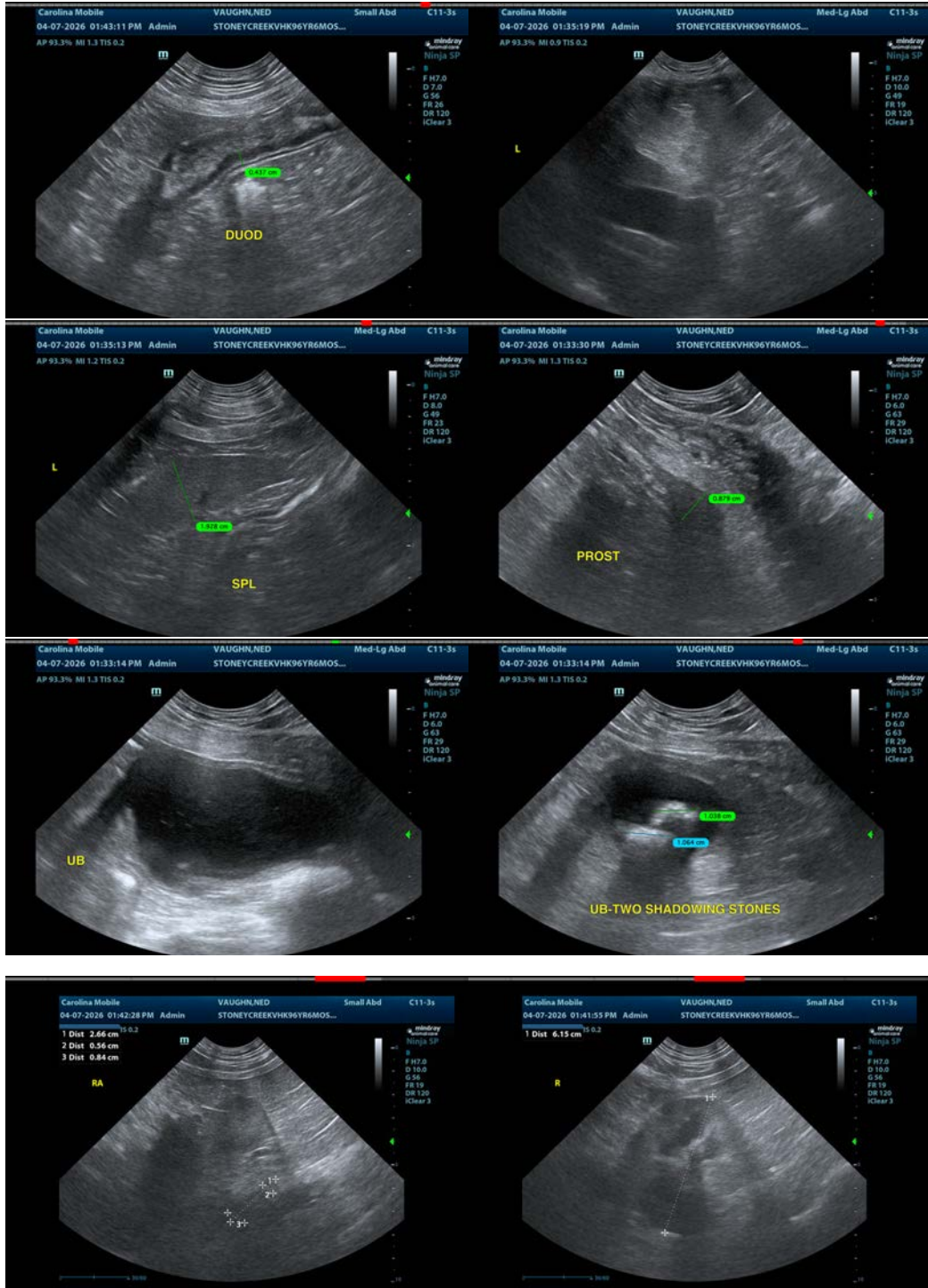
Dr. Eldred

INVOICE

74263

DATE

4/7/26





PATIENT

Ned Vaughn

SPECIES

Canine

BREED

Australian Shepherd x

SEX

Neutered Male

AGE

6 Years 6 Months

WEIGHT

62.6 lbs

INTERPRETED BY

Kathleen Sennello DVM,
MS, Diplomate ACVIM
(Small Animal Internal
Medicine)

IMAGING PERFORMED BY

Kathleen Byrnes

HOSPITAL NAME

Stoney Creek
Veterinary Hospital

REFERRING VET

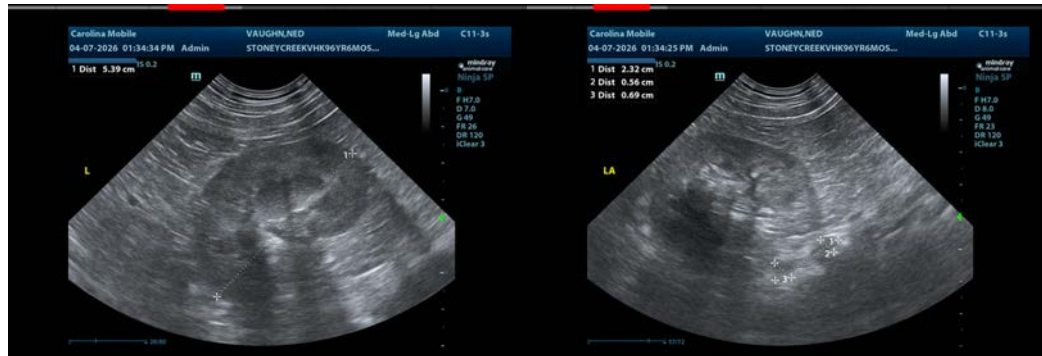
Dr. Eldred

INVOICE

74263

DATE

4/7/26



The information and recommendations provided are based on the images presented by the referring veterinarian/sonographer. No evaluation can be communicated regarding pathology that was not visible in the image/video clips provided.

Thank you for this referral. If the clinical or image interpretation does not parallel your findings or if I can be of any further assistance please contact me.

Kathleen Sennello DVM,MS, Diplomate ACVIM (Small animal Internal Medicine)

info@sonopath.com