



**PATIENT**

Maggie Fowler

**SPECIES**

Canine

**BREED**

Shih Poo

**SEX**

Spayed Female

**AGE**

12 Years

**WEIGHT**

7.1 kg

**INTERPRETED BY**

Kathleen Sennello DVM,  
 MS, Diplomate ACVIM  
 (Small Animal Internal  
 Medicine)

**IMAGING PERFORMED BY**

Crystal Hill

**HOSPITAL NAME**

Headon Forest Animal  
 Hospital

**REFERRING VET**

Dr. Gibson

**INVOICE**

74249

**DATE**

4/7/26

**PRESENTING CLINICAL SIGNS**

P presented with 2 week history of always being hungry and thirsty, panting more, mild alopecia on tip of tail and a solid feeling pudgy belly with possible lower back pain. Concerns for Cushings disease but bloodwork does not support this. Echo recommended due to excessive panting. No meds

Abnormal PE/Chem/CBC/UA Results: Mild neutrophilia without left shift, increased platelets, ALT 279(was 171 one year ago) ALP WNL, mild hypochloridemia, T4 WNL, Urine pending.

**ULTRASONOGRAPHIC EXAMINATION OF THE ABDOMEN**

**Urinary System**

The urinary bladder is moderately distended with urine. In some views there is some mild echogenic material visualized in the trigone region, possibly consistent with mild echogenic debris. The bladder wall appears of normal thickness with a smooth mucosal surface. The regions of the ureters and proximal urethra appear free of any mass lesions or calculi. Lack of full urine distention interferes with evaluation of some areas of the urinary bladder.

The left kidney has a normal shape and size (3.71 cm). Overall echogenicity is slightly hyperechoic with mildly reduced corticomedullary distinction and a typical 1:3 cortex:medulla ratio. There is no evidence of focal perinephric inflammation or effusion. There is no evidence of pyelectasia, nephroliths, infarcts or hydroureter. Renal vasculature is normal.

The right kidney has a normal shape and size (4.07 cm). Overall echogenicity is slightly hyperechoic with mildly reduced corticomedullary distinction and a typical 1:3 cortex:medulla ratio. There is no evidence of focal perinephric inflammation or effusion. There is no evidence of pyelectasia, nephroliths, infarcts or hydroureter. Renal vasculature is normal.

**Adrenal Glands**

The left adrenal gland is “plump” measuring 0.64 cm at the cranial pole and 0.70 cm at the caudal pole. It is observed in its normal position cranial to the left renal artery. It is normal in appearance (uniformly hypoechoic) and shape with no evidence of a mass effect.

The right adrenal gland is “plump” measuring 1.15 cm at the cranial pole and 0.76 cm at the caudal pole. It is observed in its normal position between the cranial aspect of the right kidney and the caudal vena cava. It is normal in appearance (uniformly hypoechoic) and shape with no evidence of a mass effect.

**Spleen**

The spleen is subjectively normal in size (0.72 cm), echotexture is homogenous, and the splenic capsule is smooth with no irregularities. The blood flow through the hilus and splenic parenchyma appears normal. No focal parenchymal abnormalities are visualized.

**Liver**

The liver is large in size and rounded. The parenchyma is heterogenous in echotexture with subtle, indistinct focal mottling. The visible portions of the vasculature and biliary tract appear normal. No focal nodules or cystic lesions are observed.



**PATIENT**

Maggie Fowler

The gall bladder lumen is moderately distended. The wall of the gall bladder is not thickened and has a smooth mucosal surface. There is a moderate amount of non-organized echogenic debris. The cystic and common bile ducts are normal/not visible.

**SPECIES**

Canine

**Gastrointestinal**

The stomach contains mild/moderate fluid and shadowing ingesta. It measures at a normal thickness of <0.7cm with some variability due to the presence of rugal folds. The distinction of the gastric wall layers is adequate and there is no impression of reduced peristaltic activity. No masses or focal lesions were observed.

**BREED**

Shih Poo

The visualized areas of duodenum, jejunum and ileum have a relatively uniform diameter with minimal fluid distension. Wall thickness is normal. Bowel loops follow a curvilinear path with distinct wall layering maintaining the typical 1:3 muscularis:mucosa layer ratio. Duodenum wall measures 0.54 cm. Jejunum wall measures 0.36 cm. Visualized peristalsis appears appropriate. There were no focal lesions consistent with obstruction or a mass effect observed.

**SEX**

Spayed Female

Sections of colon are visualized with formed fecal material and gas shadowing distally. There is no observed focal or generalized colon wall thickening or loss of layering.

**AGE**

12 Years

**Pancreas**

The pancreas is normal and isoechoic to surrounding mesentery. There is no evidence of nodules or cystic lesions. There is no evidence of regional mesenteric inflammation or fluid.

**WEIGHT**

7.1 kg

**Free Abdomen**

**INTERPRETED BY**

Kathleen Sennello DVM,  
 MS, Diplomate ACVIM  
 (Small Animal Internal  
 Medicine)

Evaluation of the peritoneal cavity did not reveal any evidence of effusion, or subjective lymphadenomegaly. The Medial iliac nodes appear normal and there was no evidence of a caudal aortic thrombus at the bifurcation. The omentum is of normal uniform echogenicity.

**IMAGING PERFORMED BY**

Crystal Hill

- Mild dependent echogenic debris in the urinary bladder – The echogenic debris in the bladder lumen could be consistent with cells, crystals, and/or mucus.
- Borderline “plump” adrenal glands – Findings could be consistent with anatomic variation or mild early hyperplasia.
- Age related changes visualized associated with both kidneys.
- Large, heterogeneous liver – The diffuse hepatic changes are non-specific and could be consistent with vacuolar hepatopathy, nodular hyperplasia, inflammatory/immune-mediated disease, fibrosis, extramedullary hematopoiesis, toxic hepatopathy (e.g., copper), infiltrative neoplasia (less likely) or other hepatopathy.
- Moderate gallbladder debris – The significance of the aggregated gallbladder debris is unclear. This could represent an early mucocele, cholestasis, or may be secondary to fasting but seems unlikely to be causing a current issue. Recommend continued monitoring.

**HOSPITAL NAME**

Headon Forest Animal  
 Hospital

**REFERRING VET**

Dr. Gibson

**INVOICE**

74249

**DATE**

4/7/26



**PATIENT**

Maggie Fowler

**SPECIES**

Canine

**BREED**

Shih Poo

**SEX**

Spayed Female

**AGE**

12 Years

**WEIGHT**

7.1 kg

**INTERPRETED BY**

Kathleen Sennello DVM,  
MS, Diplomate ACVIM  
(Small Animal Internal  
Medicine)

**IMAGING  
PERFORMED BY**

Crystal Hill

**HOSPITAL NAME**

Headon Forest Animal  
Hospital

**REFERRING VET**

Dr. Gibson

**INVOICE**

74249

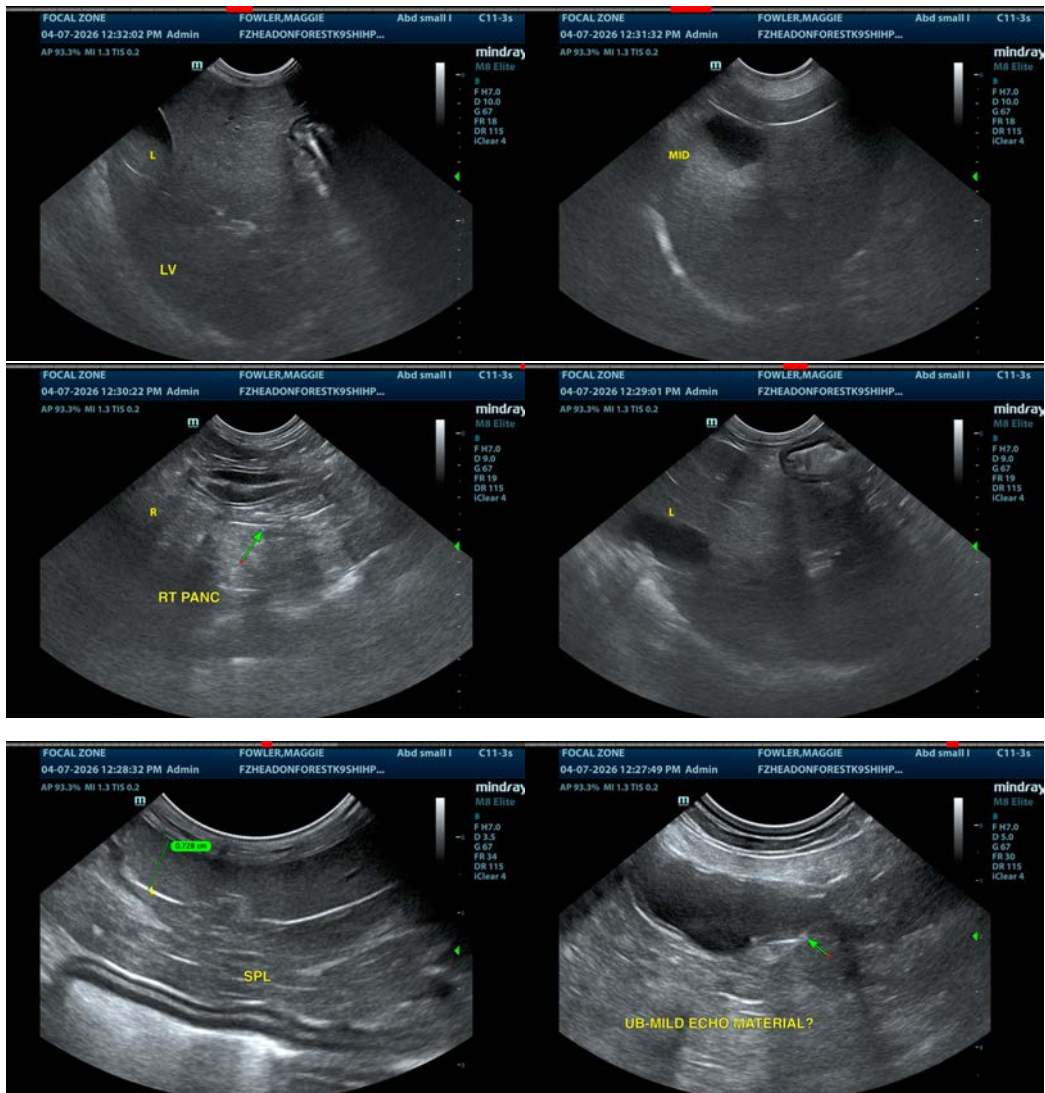
**DATE**

4/7/26

**INTERPRETATION OF THE FINDINGS & FURTHER RECOMMENDATIONS**

Both adrenals appear somewhat “plump”. This could be consistent with early hyperplasia, and the liver is round, large and heterogeneous, possibly consistent with a vacuolar hepatopathy. These findings could be consistent with Cushing’s, although the elevation in ALT is atypical. Consider a fine needle aspirate of the liver. Additionally, you could consider adrenal function testing if symptoms are fairly classic for Cushing’s.

If a more significant hepatopathy is suspected, consider a liver function test +/- biopsies of the liver with samples for histopathology, culture and copper levels.





**PATIENT**

Maggie Fowler

**SPECIES**

Canine

**BREED**

Shih Poo

**SEX**

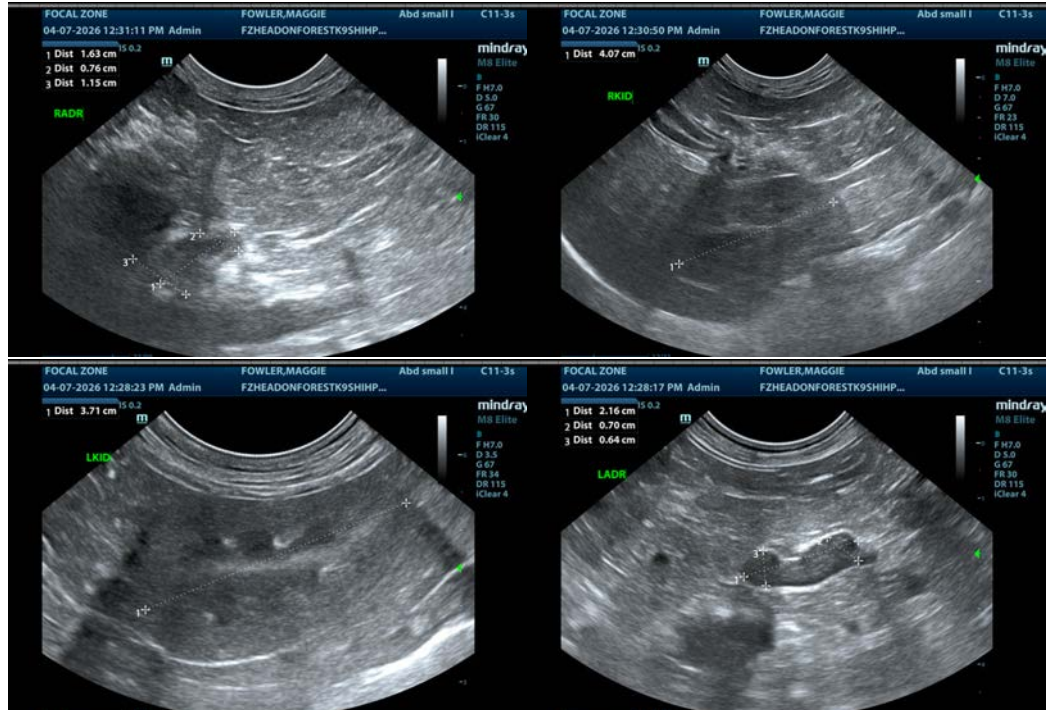
Spayed Female

**AGE**

12 Years

**WEIGHT**

7.1 kg



**INTERPRETED BY**

Kathleen Sennello DVM,  
 MS, Diplomate ACVIM  
 (Small Animal Internal  
 Medicine)

The information and recommendations provided are based on the images presented by the referring veterinarian/sonographer. No evaluation can be communicated regarding pathology that was not visible in the image/video clips provided.

Thank you for this referral. If the clinical or image interpretation does not parallel your findings or if I can be of any further assistance please contact me.

**IMAGING PERFORMED BY**

Crystal Hill

Kathleen Sennello DVM,MS, Diplomate ACVIM (Small animal Internal Medicine)

info@sonopath.com

**HOSPITAL NAME**

Headon Forest Animal  
 Hospital

**REFERRING VET**

Dr. Gibson

**INVOICE**

74249

**DATE**

4/7/26