

**DATE PRESENTING CLINICAL SIGNS**

4/7/23 Anemia with possible mass in the abdomen.

PATIENT Current Medications: Prednisone 20mg- 1 tab BID, taper dose over 3-6 months.

Sugar Bear Harris

Lab Results: See attached.

Date of Previous IntraPet Ultrasound: No previous.

Sedation: Not required to complete full diagnostic ultrasound.

Stat Report: Declined

SPECIES

Canine

Imaging Performed By: Andi Parkinson, BS, RDMS.

ULTRASONOGRAPHIC EXAMINATION OF THE ABDOMEN**BREED**

Shepherd X

Urinary System

The urinary bladder is moderately distended with anechoic urine. The Bladder wall, trigone, ureteral papillae and visible urethra (to a depth of 2cm) appear normal with no evidence of wall thickening, mucosal irregularities, or masses. In the dependent portion of the urinary bladder, there are at least 3 hyperechoic shadowing calculi. Measurements include 0.86, 0.49, and 0.94 cm.

SEX

Neutered Male

The prostate is normal in size (1.2 cm) and shape for this neutered male dog. The parenchyma is homogenous and the external margins are smooth. The prostatic urethra appears normal with no evidence of irregularity, invasion, or mass effect. There are two hyperechoic shadowing calculi visualized within the prostatic urethra measuring 0.40 and 0.41 cm.

AGE

3/19/13

WEIGHT

46.4 Pounds

The left kidney has a normal shape and size (6.12 cm) with pinpoint non-obstructive nephroliths. Overall echogenicity is slightly hyperechoic with poor corticomedullary distinction and a typical 1:3 cortex:medulla ratio. There is no evidence of focal perinephric inflammation or effusion. There is no evidence of pyelectasia, nephroliths, infarcts or hydroureter. Renal vasculature is normal.

INTERPRETED BY

Kathleen Sennello DVM,
MS, Diplomate ACVIM
(Small Animal Internal
Medicine)

The right kidney has a normal shape and size (6.28 cm) with pinpoint non-obstructive nephroliths. Overall echogenicity is slightly hyperechoic with poor corticomedullary distinction and a typical 1:3 cortex:medulla ratio. There is no evidence of focal perinephric inflammation or effusion. There is no evidence of pyelectasia, nephroliths, infarcts or hydroureter. Renal vasculature is normal.

HOSPITAL NAME

Edgewood VH

Adrenal Glands

The left adrenal gland is normal in size measuring 0.68 cm at the caudal pole. It is observed in its normal position cranial to the left renal artery. It is normal in appearance (uniformly hypoechoic) and shape with no evidence of a mass effect.

REFERRING VET

Dr. Wright

The right adrenal gland is normal in size measuring 0.77 cm at the caudal pole. It is observed in its normal position between the cranial aspect of the right kidney and the caudal vena cava. It is normal in appearance (uniformly hypoechoic) and shape with no evidence of a mass effect.

INVOICE

46485

Spleen

The spleen is large and irregular. The spleen echotexture is heterogenous and mottled, the splenic capsule is smooth with no irregularities. The blood flow through the hilus and splenic parenchyma appears normal. There is a large expansile, irregular, mixed echogenic mass effect arising from the head of the spleen measuring at least 7.67 cm x 5.84 cm. Additionally, there is an irregular hypoechoic "moth eaten" mass effect visualized towards the tail of the spleen measuring approximately 2.2 cm in diameter with a small pocket of free fluid surrounding this region.

Liver

The liver is subjectively normal in size, and echogenicity with smooth peripheral margins. The parenchyma is heterogenous in echotexture with subtle, indistinct focal mottling. The visible portions of the vasculature and biliary tract appear normal. There are occasional ill-defined hyperechoic nodules visualized within the liver. One such nodule measures 1.13 cm.

The gall bladder lumen is moderately distended. The wall of the gall bladder is not thickened and has a smooth mucosal surface. There is a moderate amount of non-organized echogenic debris. The cystic and common bile ducts are normal/not visible.

Gastrointestinal

The stomach contains minimal luminal contents. It measures at a normal thickness of <0.7cm with some variability due to the presence of rugal folds. The distinction of the gastric wall layers is adequate and there is no impression of reduced peristaltic activity. No masses or focal lesions were observed.

The visualized areas of duodenum, jejunum and ileum have a relatively uniform diameter with minimal fluid distension. Wall thickness is normal. Bowel loops follow a curvilinear path with distinct wall layering maintaining the typical 1:3 muscularis:mucosa layer ratio. Duodenum wall measures 0.45 cm. Jejunum wall measures 0.37 cm. Visualized peristalsis appears appropriate. There were no focal lesions consistent with obstruction or a mass effect observed.

The ileocecal junction was visualized and exhibited normal intact wall layering and is subjectively of normal thickness. Sections of colon are visualized with formed fecal material and gas shadowing distally. There is no observed focal or generalized colon wall thickening or loss of layering.

Pancreas

The pancreas is prominent and mottled compared to the surrounding isoechoic mesentery. There is no evidence of nodules or cystic lesions. There is no evidence of regional mesenteric inflammation or fluid.

Free Abdomen

There is a small volume of free abdominal fluid. A prominent, hypoechoic lymph node is noted in the cranial abdomen measuring 0.74 cm. The omentum is hyperechoic around the splenic masses.

Other

A brief view of the heart was submitted. No significant pericardial effusion was seen.

PRIMARY FINDINGS

- Calculi visualized in the urinary bladder and the prostatic urethra – correlate with abdominal radiographs, urinalysis and culture.
- Decreased corticomedullary distinction in both kidneys with pinpoint non-obstructive nephroliths – The bilateral renal findings are consistent with age-related change.
- Mixed echogenic mass effect arising from the head of the spleen with a 2nd ill-defined “moth eaten” mass effect towards the tail, and a small amount of surrounding free fluid – Differentials include benign lesions (lymphoid hyperplasia, hemangioma etc..) or cancerous lesions (hemangiosarcoma, lymphoma, histiocytic sarcoma etc..)
- Heterogeneous liver with ill-defined hyperechoic nodules – The diffuse hepatic changes are non-specific and could be consistent with vacuolar hepatopathy, nodular hyperplasia, inflammatory/immune-mediated disease, fibrosis, extramedullary hematopoiesis, toxic hepatopathy (e.g., copper), infiltrative neoplasia (less likely) or other hepatopathy. The appearance of the

hyperechoic nodules trends towards a benign etiology. An underlying neoplastic process cannot be ruled out.

- Moderate gallbladder debris – The significance of the aggregated gallbladder debris is unclear. This could represent an early mucocele, cholestasis, or may be secondary to fasting but seems unlikely to be causing a current issue. Recommend continued monitoring.
- Small volume free abdominal fluid – Recommend sampling to differentiate hemorrhage from ascites.
- Prominent, hypoechoic cranial abdominal lymph node – The prominent abdominal lymph nodes are most consistent with reactive lymphadenitis or lymphoid hyperplasia. Neoplastic infiltration is considered less likely.

SECONDARY FINDINGS

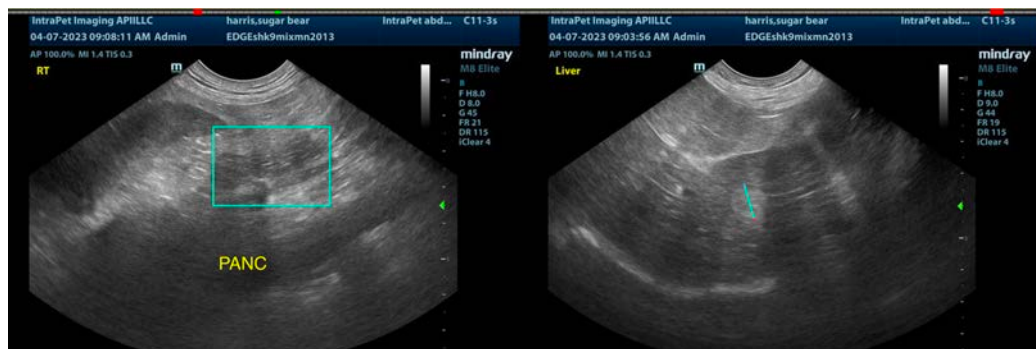
- Prominent, mottled pancreas – The pancreatic changes are most consistent with age-related parenchymal remodeling, potentially secondary to a prior inflammatory episode, early fibrosis or chronic pancreatitis.

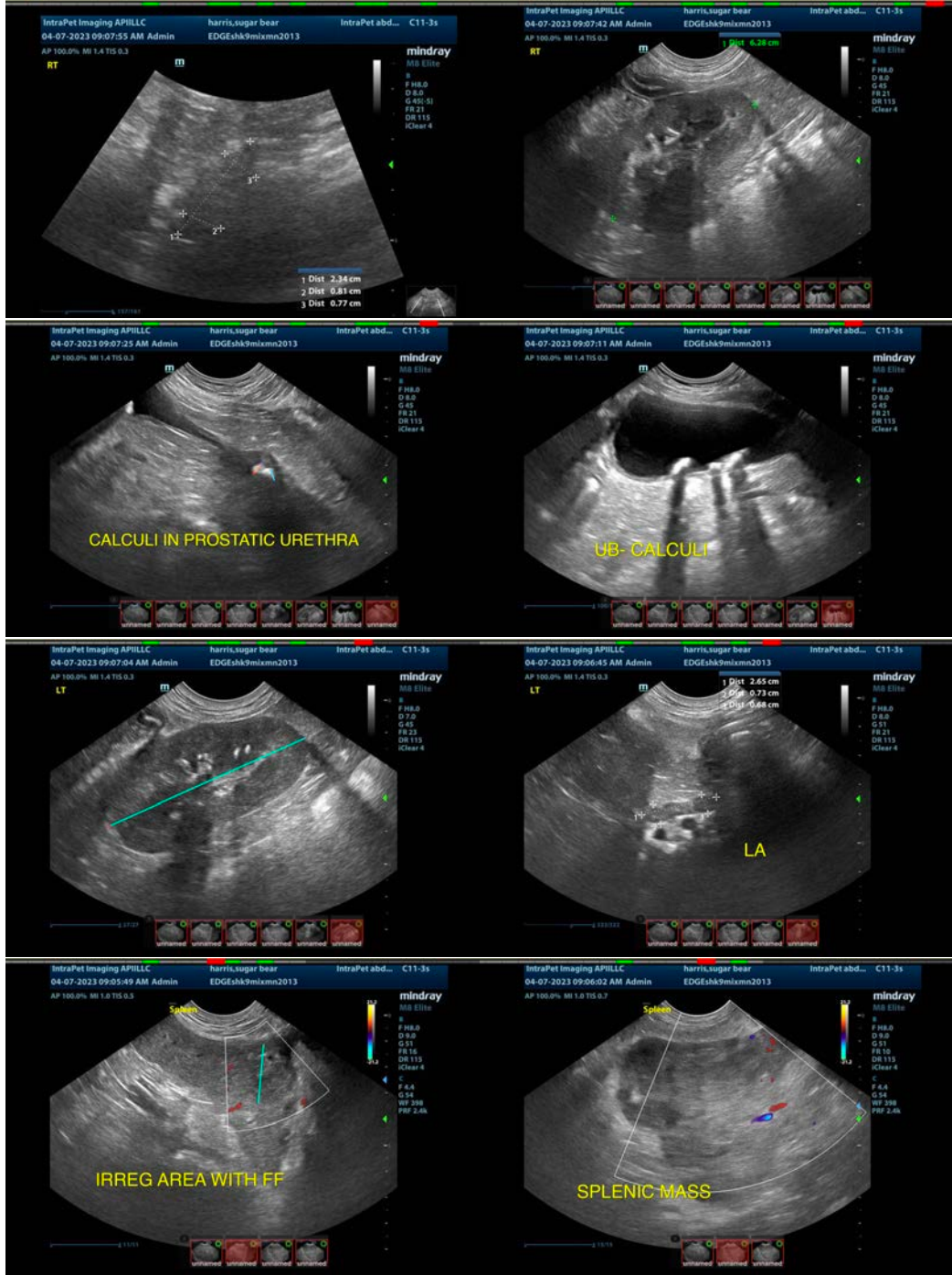
INTERPRETATION OF THE FINDINGS & FURTHER RECOMMENDATIONS

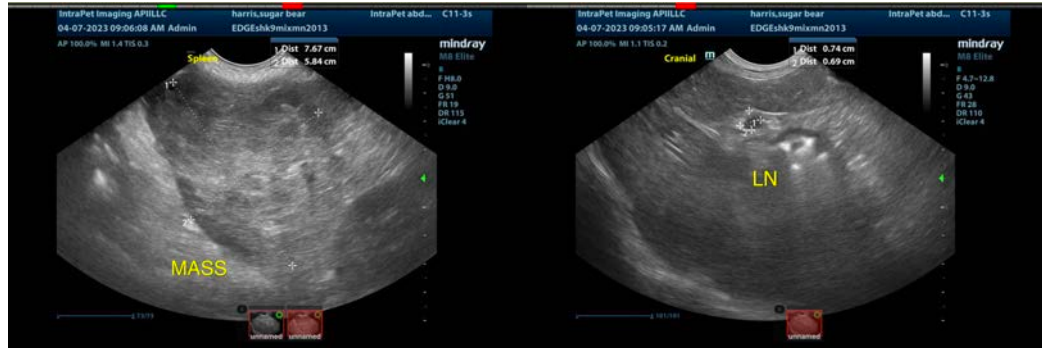
There are two significantly abnormal areas in the spleen, one of which has some surrounding fluid and could have a previous episode of hemorrhage. The appearance of these lesions is concerning for a possible neoplastic process, but a benign lesion is possible. Consider splenectomy for both diagnostic and therapeutic purposes. Additionally, there is a slightly irregular hypoechoic cranial abdominal lymph node, which could represent inflammation or a metastatic lesion.

There are multiple calculi visualized with the urinary bladder and the prostatic urethra. Correlate these findings with abdominal radiographs, urinalysis and culture. If cystotomy is considered, recommend radiographs and catheterization to ensure all stones are removed.

Recommend three view thoracic radiographs to evaluate for possible concurrent thoracic disease/involvement.







The information and recommendations provided are based on the images presented by the referring veterinarian/sonographer. No evaluation can be communicated regarding pathology that was not visible in the image/video clips provided.

Thank you for this referral. If the clinical or image interpretation does not parallel your findings or if I can be of any further assistance please contact me.

Kathleen Sennello DVM,MS, Diplomate ACVIM (Small animal Internal Medicine)
kathleen.sennello@sonopath.com