

IMAGING PERFORMED BY

IntraPet.com



SonoPath

Clinical Sonography & Telectology

EDUCATIONAL TELECONSULTATION SERVICES™

1-800-838-4268 info@sonopath.com SonoPath.com

DATE PRESENTING CLINICAL SIGNS

4/6/22 Pet presented 3/31 for changes in behavior specifically urinary and fecal accidents. A firm soft tissue mass was palpated on physical exam.

PATIENT

Emma Morris

Current Medications: None.
Date of Previous IntraPet Ultrasound: No previous.
Sedation: Not required to complete full diagnostic ultrasound.
Stat Report: Not requested.

SPECIES

Canine

BREED

Cocker Spaniel

SEX

Spayed Female

AGE

11/14/10

WEIGHT

22.2 Pounds

INTERPRETED BY

Kathleen Sennello DVM,
MS, Diplomate ACVIM
(Small Animal Internal
Medicine)

IMAGING PERFORMED BY

Rachel Brilhart RDMS

HOSPITAL NAME

Frederick Road VH

REFERRING VET

Dr. Cannon

INVOICE

36771

ULTRASONOGRAPHIC EXAMINATION OF THE ABDOMEN

Urinary System

The urinary bladder is moderately distended with anechoic urine. The Bladder wall, trigone, ureteral papillae and visible urethra (to a depth of 2cm) appear normal with no evidence of wall thickening, mucosal irregularities, masses or cystic calculi.

The left kidney has a normal shape and size (4.53 cm). Overall echogenicity is normal with adequate corticomedullary distinction and a typical 1:3 cortex:medulla ratio. There is no evidence of perinephric inflammation or effusion. There is no evidence of pyelectasia, nephroliths, infarcts or hydroureter. Renal vasculature is normal.

The right kidney has a normal shape and size (4.56 cm). Overall echogenicity is normal with adequate corticomedullary distinction and a typical 1:3 cortex:medulla ratio. There is no evidence of perinephric inflammation or effusion. There is no evidence of pyelectasia, nephroliths, infarcts or hydroureter. Renal vasculature is normal.

Adrenal Glands

The left adrenal gland is normal in size measuring 0.67 cm at the caudal pole. It is observed in its normal position cranial to the left renal artery. It is normal in appearance (uniformly hypoechoic) and shape with no evidence of a mass effect.

The right adrenal gland is normal in size measuring 0.77 cm at the caudal pole. It is observed in its normal position between the cranial aspect of the right kidney and the caudal vena cava. It is normal in appearance (uniformly hypoechoic) and shape with no evidence of a mass effect.

Spleen

The spleen is subjectively normal in size, echotexture is homogenous, and the splenic capsule is smooth with no irregularities. The blood flow through the hilus and splenic parenchyma appears normal. No focal parenchymal abnormalities are visualized.

Liver

The liver is large in size and hypoechoic. The parenchyma is heterogenous in echotexture with subtle, indistinct focal mottling. The visible portions of the vasculature and biliary tract appear normal. No focal nodules or cystic lesions are observed.

The gallbladder lumen is moderately distended. The wall of the gall bladder is not thickened and has a smooth mucosal surface. Luminal contents are primarily anechoic. The cystic and common bile ducts are normal/not visible.

Gastrointestinal

The stomach contains minimal luminal contents. It measures at a normal thickness of <0.7cm with some variability due to the presence of rugal folds. The distinction of the gastric wall layers is adequate and there is no impression of reduced peristaltic activity. No masses or focal lesions were observed.

The visualized areas of duodenum, jejunum and ileum have a uniform diameter with minimal fluid distension. Wall appears subjectively, mildly increased. Bowel loops follow a typical curvilinear path with distinct wall layering. No mucosal speckling visualized. Visualized peristalsis appears appropriate. There is a large area of small intestine that is severely thickened and irregular with a hypoechoic wall and complete loss of wall layering. In this area, the bowel wall measures at 1.43 cm in thickness, and this extends for over 5.0 cm in length.

The ileocecal junction was visualized and exhibited normal intact wall layering and is subjectively of normal thickness. Sections of colon are visualized with formed fecal material and gas shadowing distally. There is no observed focal or generalized colon wall thickening or loss of layering.

Pancreas

The pancreas is normal and isoechoic to surrounding mesentery. There is no evidence of nodules or cystic lesions. There is no evidence of regional mesenteric inflammation or fluid.

Free Abdomen

There is a scant amount of free abdominal fluid. There is a moderate abdominal lymphadenopathy with enlarged lymph nodes measuring 2.22 cm x 0.82 cm and 2.18 cm x 1.09 cm. The omentum is of increased echogenicity around the bowel mass.

Other

Ringdown artifact visualized at the level of the diaphragm. This can be associated with pulmonary parenchymal disease. Recommend thoracic radiographs.

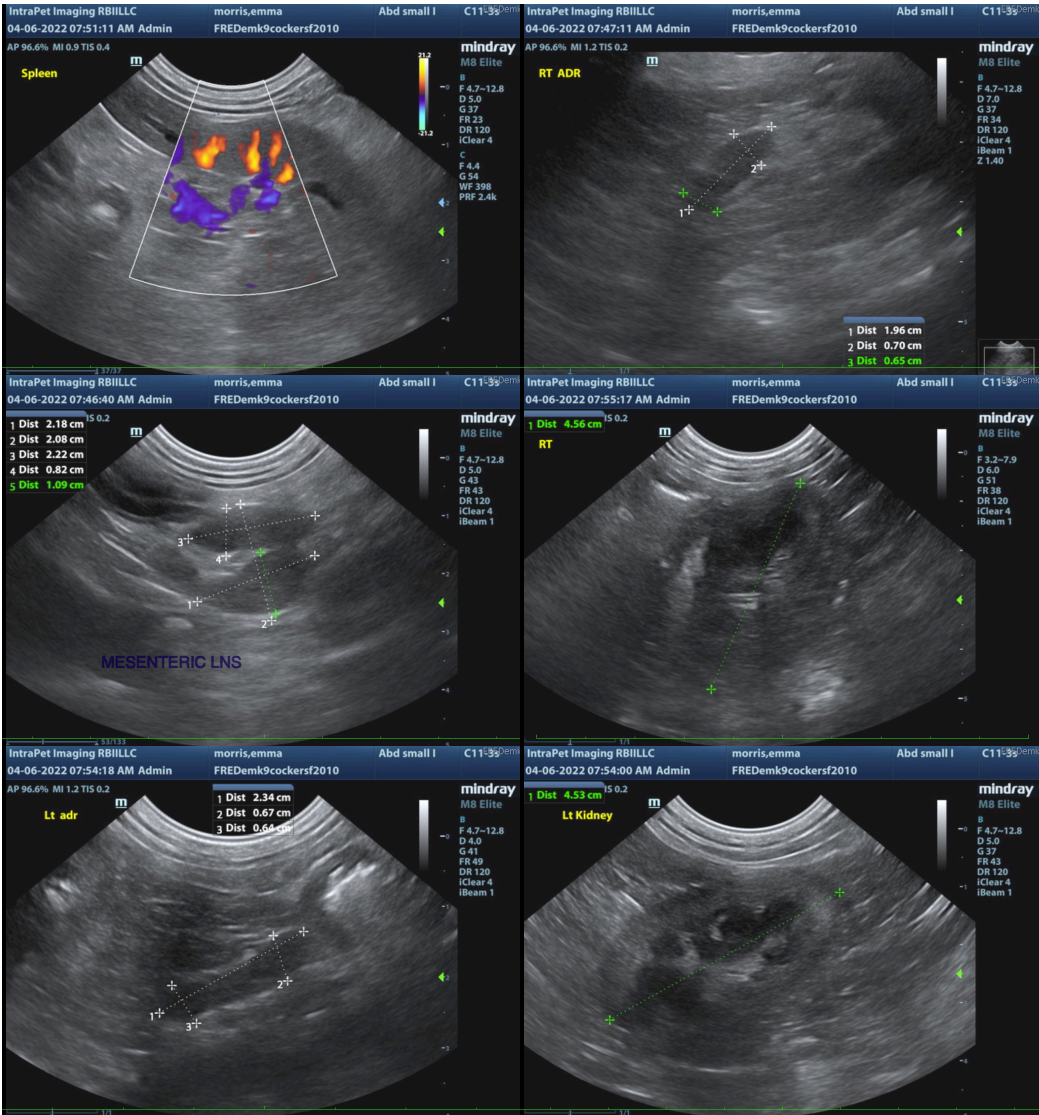
ULTRASONOGRAPHIC FINDINGS

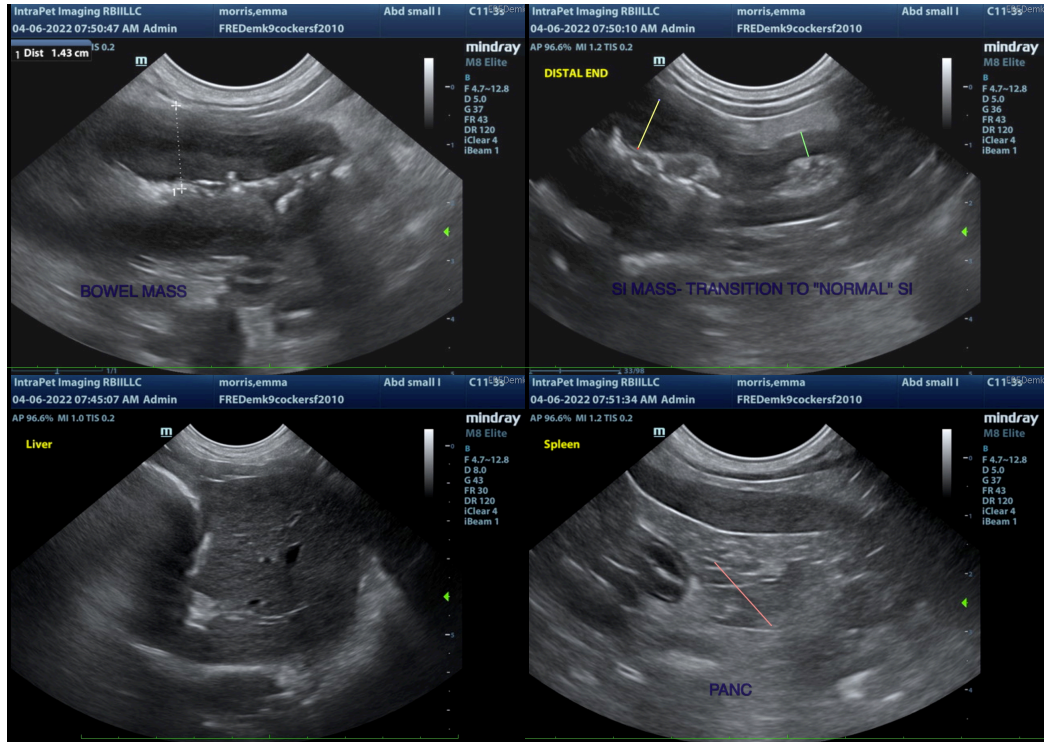
- Large, hypoechoic, heterogeneous liver – The diffuse hepatic changes are non-specific and could be consistent with vacuolar hepatopathy, nodular hyperplasia, inflammatory/immune-mediated disease, fibrosis, extramedullary hematopoiesis, toxic hepatopathy (e.g., copper), infiltrative neoplasia (less likely) or other hepatopathy.
- Focal area of bowel with severely thickened, irregular wall and complete loss of layering – Findings are most consistent with a bowel mass. Of primary concern would be round cell neoplasia, or other possibilities such as carcinoma, leiomyoma, leiomyosarcoma, etc.
- Moderate mesenteric lymphadenopathy – The moderate mesenteric lymphadenopathy could be concerning for a neoplastic process, although you can see significant lymphadenopathy in some cases of autoimmune/inflammatory disease, infectious disease (tick born disease-such as bartonella, fungal infections, FIP (cats)) etc. A fine needle aspirate with cytology is recommended for further evaluation.

INTERPRETATION OF THE FINDINGS & FURTHER RECOMMENDATIONS

A large bowel mass is present. This is very concerning for an underlying neoplastic process. Recommend a fine needle aspirate of the bowel wall and a mesenteric lymph node (if able to reach). Additionally, the liver is large, heterogeneous and hypoechoic. This could be consistent with infiltrative disease. If a cytologic diagnosis cannot be obtained via fine needle aspirate of the bowel wall itself, you could consider a hepatic aspirate.

Ringdown artifact was noted at the level of the diaphragm. This could be an indicator of pulmonary parenchymal disease. Recommend 3-view thoracic radiographs and surgical biopsies/resection if a cytologic diagnosis cannot be obtained.





The information and recommendations provided are based on the images presented by the referring veterinarian/sonographer. No evaluation can be communicated regarding pathology that was not visible in the image/video clips provided.

Thank you for this referral. If the clinical or image interpretation does not parallel your findings or if I can be of any further assistance please contact me.

Kathleen Sennello DVM,MS, Diplomate ACVIM (Small animal Internal Medicine)
kathleen.sennello@sonopath.com