

**DATE**

4/6/22

**PRESENTING CLINICAL SIGNS**

Patient has referral for decreased appetite, losing weight, and lethargic. The rDVM seen the patient when we go for a decreased appetite they did x-rays and there is was stool present in the colon and 1 area that was suspicious of a foreign body. The blood work showed increase in globulins. The rDVM did sq fluids given an appetite stimulant and patient ate in hospital and they wanted to recheck in 1 week. At the recheck the patient was not vomiting x-rays still the same she discussed with the Owner about a possible foreign body. And the risk of resection and anastomosis. The owner said that the patient has always been a picky eater and has been losing weight but over the past week the patient has lost a lot of weight in a short time frame. Current Medications: Unasyn, Buprenorphine, Protonix.

**PATIENT**

Ellie Virgilio

**SPECIES**

Feline

**BREED**

Domestic Shorthair

**SEX**

Spayed Female

**AGE**

10/5/20

**WEIGHT**

4.8 lbs

**INTERPRETED BY**

Kathleen Sennello  
DVM, MS, Diplomate  
ACVIM (Small Animal  
Internal Medicine)

**HOSPITAL NAME**

Animal Emergency  
Hospital

**REFERRING VET**

Dr. Roper

**INVOICE**

98077

**ULTRASONOGRAPHIC EXAMINATION OF THE ABDOMEN****Urinary System**

The urinary bladder is moderately distended with anechoic urine. The Bladder wall, trigone, ureteral papillae and visible urethra (to a depth of 2cm) appear normal with no evidence of wall thickening, mucosal irregularities, masses or cystic calculi.

The left kidney has a normal shape and size (3.36 cm). Overall echogenicity is normal with adequate corticomedullary distinction and a typical 1:3 cortex:medulla ratio. There is no evidence of perinephric inflammation or effusion. There is no evidence of pyelectasia, nephroliths, infarcts or hydroureter. Renal vasculature is normal.

The right kidney has a normal shape and size (3.46 cm). Overall echogenicity is normal with adequate corticomedullary distinction and a typical 1:3 cortex:medulla ratio. There is no evidence of perinephric inflammation or effusion. There is no evidence of pyelectasia, nephroliths, infarcts or hydroureter. Renal vasculature is normal.

**Adrenal Glands**

The left adrenal gland is normal in size measuring 0.49 cm at the caudal pole. It is observed in its normal position cranial to the left renal artery. It is normal in appearance (uniformly hypoechoic) and shape with no evidence of a mass effect.

The right adrenal gland is normal in size measuring 0.35 cm at the caudal pole. It is observed in its normal position between the cranial aspect of the right kidney and the caudal vena cava. It is normal in appearance (uniformly hypoechoic) and shape with no evidence of a mass effect.

**Spleen**

The spleen is subjectively normal in size, echotexture is homogenous, and the splenic capsule is smooth with no irregularities. The blood flow through the hilus and splenic parenchyma appears normal. No focal parenchymal abnormalities are visualized.

**Liver**

The liver is subjectively normal in size, and echogenicity with smooth peripheral margins. The parenchyma is hypoechoic and heterogenous in echotexture with subtle, indistinct focal mottling. The visible portions of the vasculature and biliary tract appear normal. No focal nodules or cystic lesions are observed. The gallbladder

lumen is moderately distended. The wall of the gallbladder is not thickened and has a smooth mucosal surface. Luminal contents are primarily anechoic. The cystic and common bile ducts are normal/not visible.

### ***Gastrointestinal***

The stomach contains minimal luminal contents. It measures at a normal thickness of <0.36cm with some variability due to the presence of rugal folds. The distinction of the gastric wall layers is adequate and there is no impression of reduced peristaltic activity. No masses or focal lesions were observed.

The visualized areas of duodenum, jejunum and ileum have a uniform diameter with minimal fluid distension. Wall thickness is normal to slightly increased. The jejunum measured 0.27 cm. Bowel loops follow a typical curvilinear path with distinct wall layering, but some areas display a prominent muscularis layer which does not display the typical 1:3 muscularis:mucosa layer ratio. Visualized peristalsis appears appropriate. There were no focal lesions consistent with obstruction or a mass effect observed.

The ileocecal junction was visualized and exhibited normal intact wall layering at that location. Almost immediately as the colon traverses distally it becomes severely thickened and irregular with a complete loss of layering. The colonic wall measures 0.6-0.8 cm in thickness. The mesentery is hyperechoic surrounding the distal colon.

### ***Pancreas***

The pancreas is normal and isoechoic to surrounding mesentery. There is no evidence of nodules or cystic lesions. There is no evidence of regional mesenteric inflammation or fluid.

### ***Free Abdomen***

There is a small amount of free abdominal fluid. There is a lymphadenopathy present particularly at the ileocecal junction where lymph nodes are visualized with a width of 0.52 cm, 0.41 cm. The omentum is of increased echogenicity around the colon and enlarged lymph nodes.

## **ULTRASONOGRAPHIC FINDINGS**

### **PRIMARY FINDINGS:**

- Hypoechoic, heterogenous liver. Hepatic changes are non-specific and could be consistent with inflammation/infection (cholangiohepatitis), infiltrative neoplasia, lipidosis or other hepatopathy.
- Prominent and hypoechoic pancreas. The pancreatic changes are most consistent with age-related parenchymal remodeling, potentially secondary to a prior inflammatory episode, early fibrosis or chronic pancreatitis.
- Prominent muscularis layer to the small intestine. The small intestinal wall changes are most consistent with an inflammatory process (i.e., inflammatory bowel disease) with a low possibility of emerging lymphoma.
- Severely thickened and irregular colon wall with loss of layering. This appears to affect the entire area of colon visualized (from ileocecal junction to distal colon at the level of the urinary bladder). The findings are concerning for infiltrative disease (LMA, carcinoma, FIP, etc.).
- Mild to moderate mesenteric lymphadenopathy. The prominent abdominal lymph nodes are most consistent with reactive lymphadenitis or lymphoid hyperplasia. Neoplastic infiltration is considered less likely.

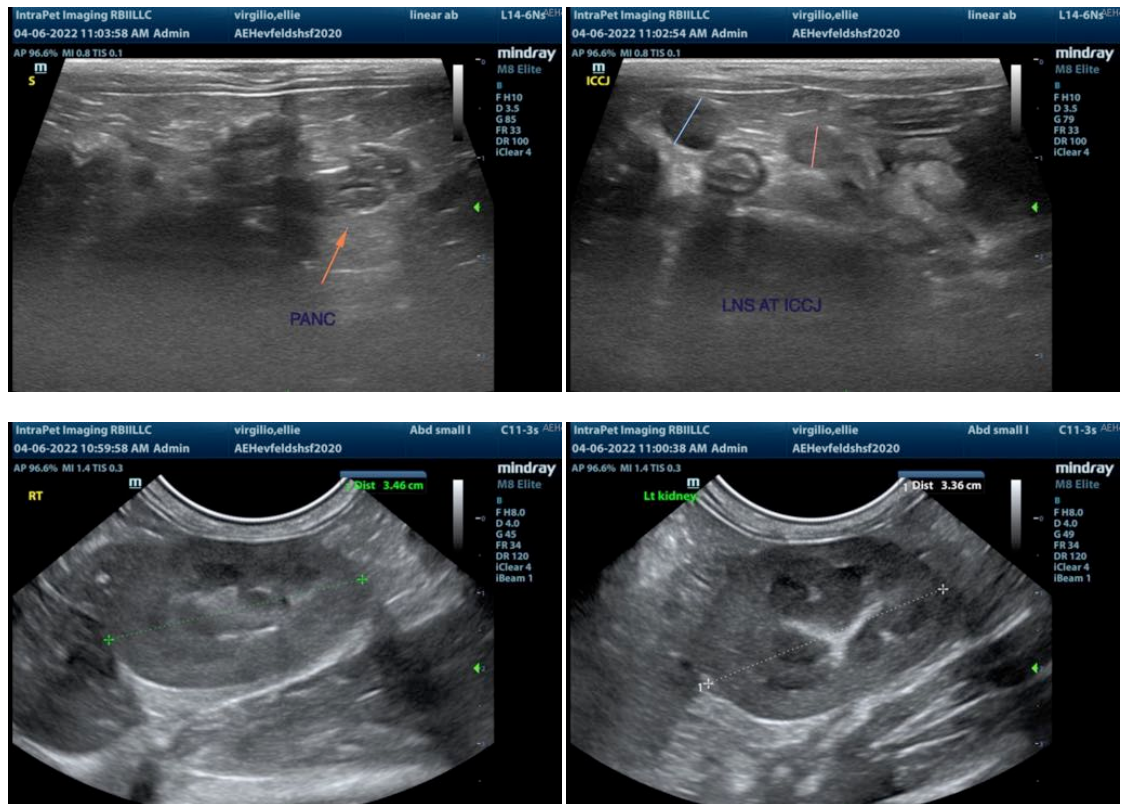
### INTERPRETATION OF THE FINDINGS & FURTHER RECOMMENDATIONS

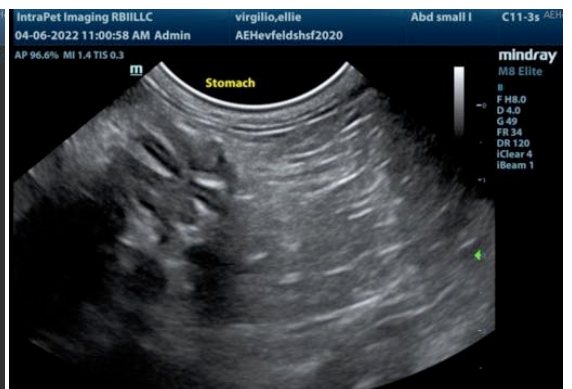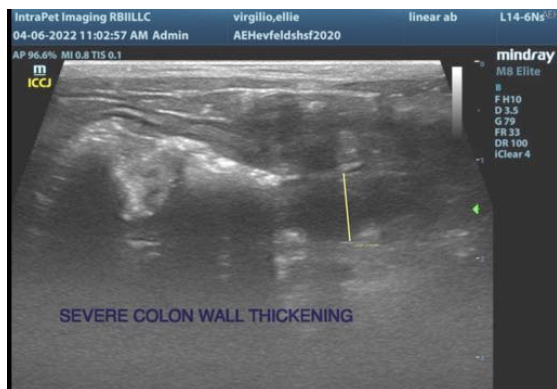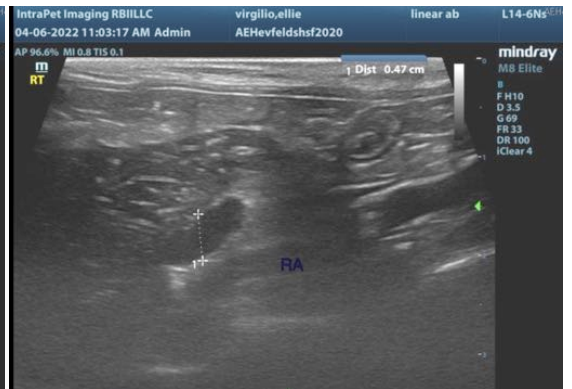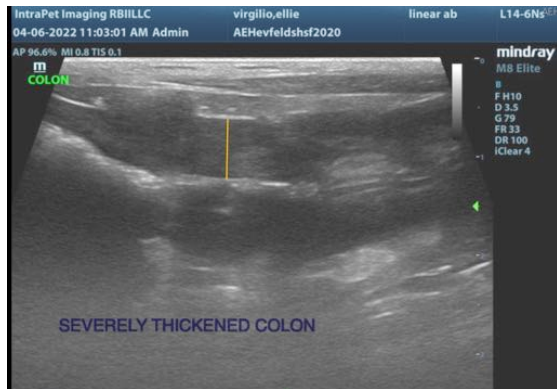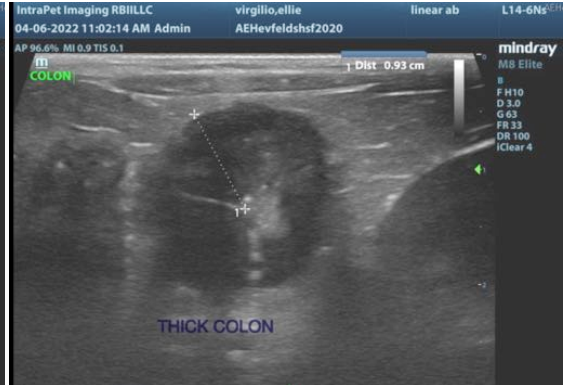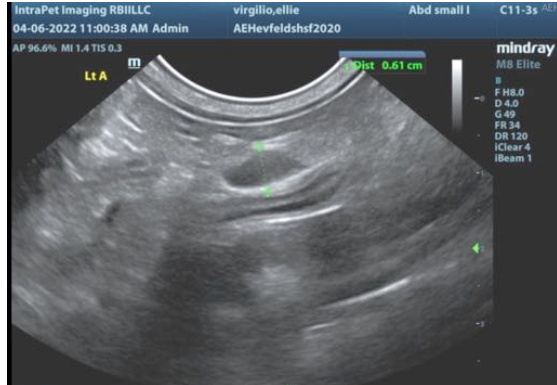The colonic wall is severely thickened and irregular. My suspicion is that the fecal material visualized within the colon on radiographs is actually colonic wall/colonic mass. It is very thickened in its entirety. There is concern for an underlying neoplastic process, but other differentials such as FIP, granulomatous, colitis, etc. could be possible. Consider a FNA of the colon wall and a mesenteric lymph node.

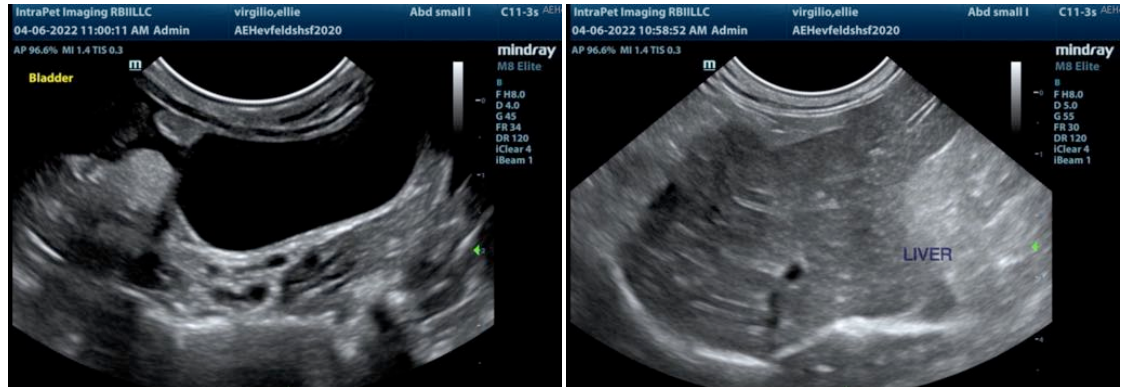
Additionally the liver is somewhat hypoechoic. An aspirate of this can be considered if an answer is not achieved based on cytology from the colon. If an answer cannot be obtained based on cytology and aspirates then it is likely that a surgical colonic biopsy would be necessary.

Due to the young age of this pet I would encourage a biopsy (if cytology is not diagnostic) to rule out a more treatable cause of this lesion.

Consider three view thoracic radiographs to rule out concurrent thoracic disease/involvement.







The information and recommendations provided are based on the images presented by the referring veterinarian. No evaluation can be communicated regarding pathology that was not visible in the image/video clips provided.

Thank you for this referral. If the clinical or image interpretation does not parallel your findings or if I can be of any further assistance please contact me.

Kathleen Sennello DVM,MS, Diplomate ACVIM (Small animal Internal Medicine)  
kathleen.sennello@sonopath.com