

**DATE PRESENTING CLINICAL SIGNS**

4/5/23

Presented today for evaluation of a progressively enlarging masses over his right lateral tibia. The owners reported that the masses have been present for about 5 weeks but have gotten significantly larger since they were first noted. Tucker does not seem to be bothered by them but does occasionally lick the area. Also, Tucker has had a significantly reduced appetite for approximately 10 days and is only willing to eat the gravy over his food the last few days. The owners feel he is otherwise acting normally. He is not currently receiving any medications.

PATIENT

Tucker Patey

SPECIES

Feline

Current Medications: Ciproheptadine 4mg tab - 1/2 tab SID PRN to stimulate appetite.
Lab Results: Pre-Anesthetic Blood Panel (In-House) IDEXX Vet Lab Station - within normal limits.
Date of Previous IntraPet Ultrasound: No previous.

BREED

DSH

Sedation: Sedated with Torbugesic and Midazolam.
Stat Report: Not requested.
Imaging Performed By: Andi Parkinson, BS, RDMS.

SEX

Neutered Male

ULTRASONOGRAPHIC EXAMINATION OF THE ABDOMEN**Urinary System**

The urinary bladder is moderately distended with mild primarily suspended echogenic debris present. The Bladder wall, trigone, ureteral papillae and visible urethra (to a depth of 2cm) appear normal with no evidence of wall thickening, mucosal irregularities, masses or calculi. Echogenic debris of this type can be associated with small crystals, cellular debris and proteinaceous debris.

AGE

3/7/17

WEIGHT

6.7 kg

The left kidney has a normal shape and size (4.07 cm). Overall echogenicity is normal with adequate corticomedullary distinction and a typical 1:3 cortex:medulla ratio. There is no evidence of focal perinephric inflammation or effusion. There is no evidence of pyelectasia, nephroliths, infarcts or hydroureter. Renal vasculature is normal.

INTERPRETED BY

Kathleen Sennello DVM,
MS, Diplomate ACVIM
(Small Animal Internal
Medicine)

The right kidney has a normal shape and size (4.24 cm). Overall echogenicity is normal with adequate corticomedullary distinction and a typical 1:3 cortex:medulla ratio. There is no evidence of focal perinephric inflammation or effusion. There is no evidence of pyelectasia, nephroliths, infarcts or hydroureter. Renal vasculature is normal.

HOSPITAL NAME

Nexus Vet Specialists

Adrenal Glands

The left adrenal gland is normal in size measuring 0.39 cm at the caudal pole. It is observed in its normal position cranial to the left renal artery. It is normal in appearance (uniformly hypoechoic) and shape with no evidence of a mass effect.

REFERRING VET

Dr. Havemann

The right adrenal gland is normal in size measuring 0.42 cm at the caudal pole. It is observed in its normal position between the cranial aspect of the right kidney and the caudal vena cava. It is normal in appearance (uniformly hypoechoic) and shape with no evidence of a mass effect.

INVOICE

46423

Spleen

The spleen is borderline large in size (1.0-1.2 cm in width at the level of the hilus), echotexture is homogenous, with mildly scalloped margins. The blood flow through the hilus and splenic parenchyma appears normal. No focal parenchymal abnormalities are visualized.

Liver

The liver is subjectively normal in size, and echogenicity with smooth peripheral margins. The parenchyma is homogenous echotexture. The visible portions of the vasculature and biliary tract appear normal. No focal nodules or cystic lesions are observed.

The gallbladder lumen is moderately distended. The wall of the gall bladder is not thickened and has a smooth mucosal surface. Luminal contents are mild and primarily anechoic. The cystic and common bile ducts are normal/not visible.

Gastrointestinal

The stomach contains minimal luminal contents. It measures at a normal thickness of <0.36cm with some variability due to the presence of rugal folds. The distinction of the gastric wall layers is adequate and there is no impression of reduced peristaltic activity. No masses or focal lesions were observed.

The visualized areas of duodenum, jejunum and ileum have a relatively uniform diameter with minimal fluid distension. Wall thickness is normal. Bowel loops follow a curvilinear path with distinct wall layering maintaining the typical 1:3 muscularis:mucosa layer ratio. The duodenum measured as normal (between 0.13-0.38cm in wall thickness) and the jejunum measured as normal (between 0.15-0.36cm.) Visualized peristalsis appears appropriate. There were no focal lesions consistent with obstruction or a mass effect observed.

The ileocecal junction was visualized and exhibited normal intact wall layering and is subjectively of normal thickness. Sections of colon are visualized with formed fecal material and gas shadowing distally. There is no observed focal or generalized colon wall thickening or loss of layering.

Pancreas

The pancreas is normal and isoechoic to surrounding mesentery. There is no evidence of nodules or cystic lesions. There is no evidence of regional mesenteric inflammation or fluid.

Free Abdomen

Evaluation of the peritoneal cavity did not reveal any evidence of effusion, or subjective lymphadenomegaly. The Medial iliac nodes appear normal and there was no evidence of a caudal aortic thrombus at the bifurcation. The omentum is of normal uniform echogenicity.

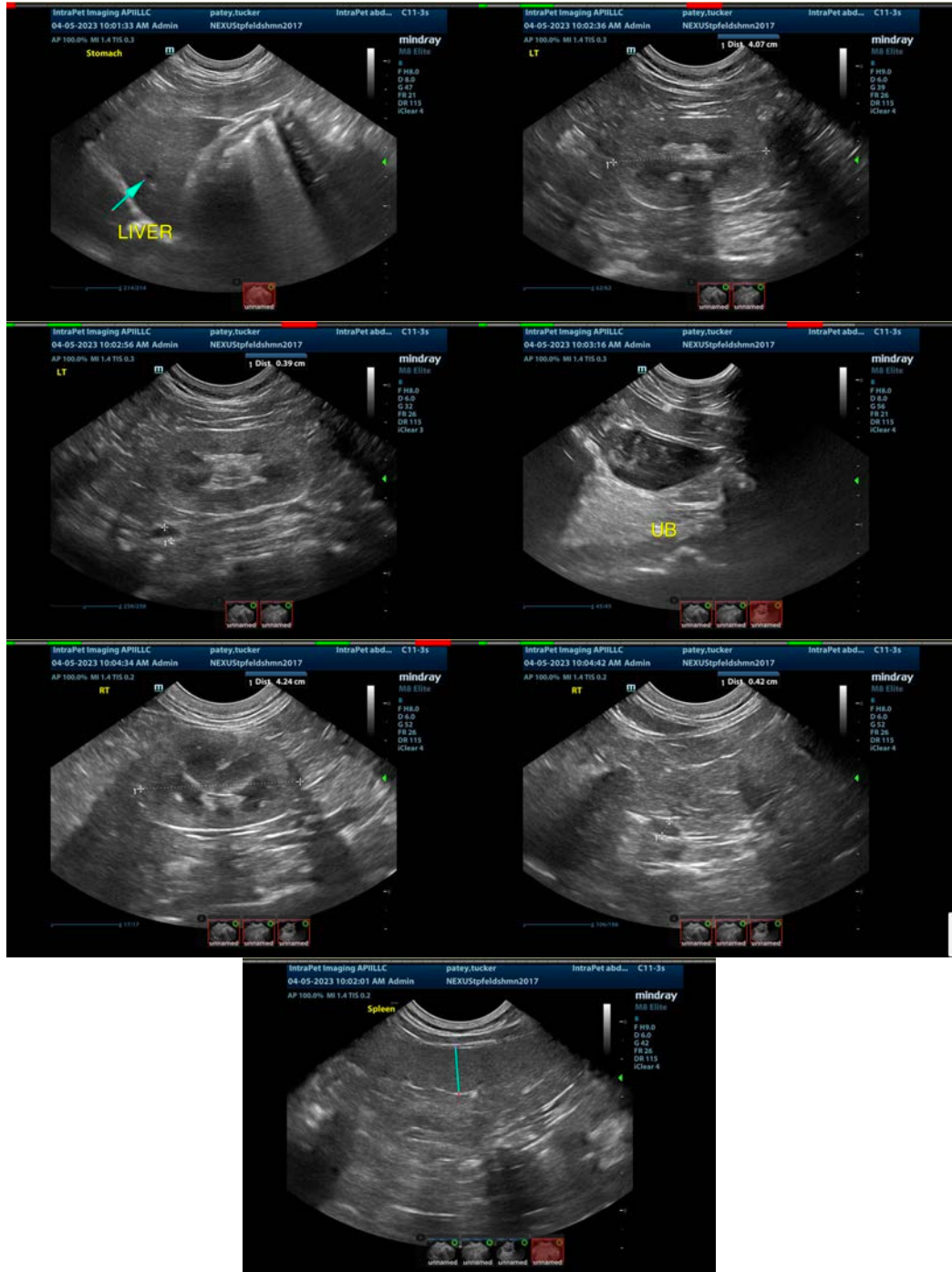
ULTRASONOGRAPHIC FINDINGS

- Echogenic debris in the urinary bladder – The echogenic debris in the bladder lumen could be consistent with cells, crystals, and/or mucus.
- Subjectively large/scalloped spleen – This could be normal for a large cat. Other differentials would include infiltrative disease, congestion, etc.

INTERPRETATION OF THE FINDINGS & FURTHER RECOMMENDATIONS

The changes observed on today's scan are relatively mild. There is a moderate amount of echogenic debris visualized in the urinary bladder, and the spleen measures as slightly enlarged with scalloped edge and normal echogenicity.

Further diagnostic and therapeutic recommendations regarding this exam to be made by Dr. Cara Steele.



The information and recommendations provided are based on the images presented by the referring veterinarian/sonographer. No evaluation can be communicated regarding pathology that was not visible in the image/video clips provided.

Thank you for this referral. If the clinical or image interpretation does not parallel your findings or if I can be of any further assistance please contact me.

Kathleen Sennello DVM,MS, Diplomate ACVIM (Small animal Internal Medicine)
kathleen.sennello@sonopath.com