

PATIENT PRESENTING CLINICAL SIGNS

Sammy Cremer

SPECIES

Canine

BREED

Chihuahua Mix

SEX

Neutered Male

AGE

5/23/2013

WEIGHT

3.4kg

INTERPRETED BY

Kathleen Sennello DVM,
MS, Diplomate ACVIM
(Small Animal Internal
Medicine)

**IMAGING
PERFORMED BY**

Loetitia Saint-Jacques,
LVT

HOSPITAL NAME

Deserts Hills Animal
Hospital

REFERRING VET

Dr. Michelle Caldwell

INVOICE

10157

DATE

4/4/2023

Initially was at ophthalmologist for an enucleation due to a ruptured globe due to neurogenic KCS. While at ophthalmologist P had elevated 12/1/22 Alk Phos & ALT-was seen for bile acids here 12/2/22 which were WNL. Started on Denamarin, cerenia & clavamox & labs were WNL 12/21/22. P seen here again 3/24/23 for a dental consult & hepatic values were again elevated, not as high as 12/1/22. Eye was enucleated mid-December. MEDS: Denamarin 90 mg 1 PO q 24 hours; Clindamycin 12.5mg Po q 12 hours, multiple eye drops including Genteal, Pilocarpine 3 drops PO BID, NeoPolyDex, Tacrolimus

Abnormal PE/Chem/CBC/UA Results: 2/24/23-Superchem- ALT=325 (was >1000 12/1/22), Alk Phos=138-barely above normal range (was 72 12/1/22), GGT=18 (was 41 12/1/22); Bile Acids 12/2/22: Bile Acid 40 Bile Acids Post- Meal 48.4

ULTRASONOGRAPHIC EXAMINATION OF THE ABDOMEN

Urinary System

The urinary bladder is moderately distended with anechoic urine. The Bladder wall, trigone, ureteral papillae, and visible urethra (to a depth of 2cm) appear normal with no evidence of wall thickening, mucosal irregularities, masses, or cystic calculi.

The prostate is normal in size (0.86 cm) and shape for this neutered male dog. The parenchyma is homogenous, and the external margins are smooth. The prostatic urethra appears normal with no evidence of irregularity, invasion, mass effect or calculi.

The left kidney has a normal shape and size (3.42 cm). Overall echogenicity is normal with adequate corticomedullary distinction and a typical 1:3 cortex: medulla ratio. There is no evidence of focal perinephric inflammation or effusion. There is no evidence of pyelectasia, nephroliths, infarcts or hydroureter. Renal vasculature is normal.

The right kidney has a normal shape and size (3.94 cm). Overall echogenicity is normal with adequate corticomedullary distinction and a typical 1:3 cortex: medulla ratio. There is no evidence of focal perinephric inflammation or effusion. There is no evidence of pyelectasia, nephroliths, infarcts or hydroureter. Renal vasculature is normal.

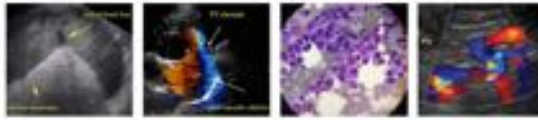
Adrenal Glands

The left adrenal gland is normal in size measuring 0.51 cm at the caudal pole. It is observed in its normal position cranial to the left renal artery. It is normal in appearance (uniformly hypoechoic) and shape with no evidence of a mass effect.

The right adrenal gland is normal in size measuring 0.51 cm at the caudal pole. It is observed in its normal position between the cranial aspect of the right kidney and the caudal vena cava. It is normal in appearance (uniformly hypoechoic) and shape with no evidence of a mass effect.

Spleen

The spleen is subjectively normal in size, echotexture is homogenous, and the splenic capsule is smooth with no irregularities. The blood flow through the hilus and splenic parenchyma appears normal. No focal parenchymal abnormalities are visualized.



PATIENT *Liver*

Sammy Cremer

The liver is subjectively normal in size, and echogenicity with smooth peripheral margins. The parenchyma is mildly heterogenous in echotexture with subtle, indistinct focal mottling. The visible portions of the vasculature and biliary tract appear normal. No focal nodules or cystic lesions are observed.

SPECIES

Canine

BREED

Chihuahua Mix

The gall bladder lumen is moderately distended. The wall of the gall bladder is not thickened and has a smooth mucosal surface. There is a moderate amount of non-organized echogenic debris. The cystic and common bile ducts are normal/not visible.

SEX

Neutered Male

The stomach contains minimal luminal contents. It measures at a normal thickness of <0.7cm with some variability due to the presence of rugal folds. The distinction of the gastric wall layers is adequate and there is no impression of reduced peristaltic activity. No masses or focal lesions were observed.

AGE

5/23/2013

The visualized areas of duodenum, jejunum and ileum have a relatively uniform diameter with minimal fluid distension. Wall thickness is normal. Bowel loops follow a curvilinear path with distinct wall layering maintaining the typical 1:3 muscularis: mucosa layer ratio. The duodenum measured as normal (0.46 cm), and the jejunum measured as normal (0.3 cm.) Visualized peristalsis appears appropriate. There were no focal lesions consistent with obstruction or a mass effect observed.

WEIGHT

3.4kg

The ileocecal junction was visualized and exhibited normal intact wall layering and is subjectively of normal thickness. Sections of colon are visualized with formed fecal material and gas shadowing distally. There is no observed focal or generalized colon wall thickening or loss of layering.

INTERPRETED BY

Kathleen Sennello DVM,
MS, Diplomate ACVIM
(Small Animal Internal
Medicine)

Pancreas

The pancreas is normal and isoechoic to surrounding mesentery. There is no evidence of nodules or cystic lesions. There is no evidence of regional mesenteric inflammation or fluid.

IMAGING PERFORMED BY

Loetitia Saint-Jacques,
LVT

Free Abdomen

Evaluation of the peritoneal cavity did not reveal any evidence of effusion, or subjective lymphadenomegaly. The Medial iliac nodes appear normal and there was no evidence of a caudal aortic thrombus at the bifurcation. The omentum is of normal uniform echogenicity.

HOSPITAL NAME

Deserts Hills Animal
Hospital

PRIMARY FINDINGS

- Mildly heterogenous liver. The diffuse hepatic changes are non-specific and could be consistent with vacuolar hepatopathy, nodular hyperplasia, inflammatory/immune-mediated disease, fibrosis, extramedullary hematopoiesis, toxic hepatopathy (e.g., copper), infiltrative neoplasia (less likely) or other hepatopathy.
- Moderate gallbladder debris. The significance of the aggregated gallbladder debris is unclear. This could represent an early mucocele, cholestasis, or may be secondary to fasting but seems unlikely to be causing a current issue. Recommend continued monitoring.

REFERRING VET

Dr. Michelle Caldwell

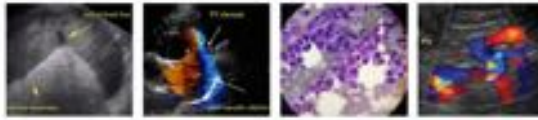
INVOICE

10157

DATE

4/4/2023

INTERPRETATION OF THE FINDINGS & FURTHER RECOMMENDATIONS



PATIENT

Sammy Cremer

SPECIES

Canine

BREED

Chihuahua Mix

SEX

Neutered Male

AGE

5/23/2013

WEIGHT

3.4kg

INTERPRETED BY

Kathleen Sennello DVM,
MS, Diplomate ACVIM
(Small Animal Internal
Medicine)

**IMAGING
PERFORMED BY**

Loetitia Saint-Jacques,
LVT

HOSPITAL NAME

Deserts Hills Animal
Hospital

REFERRING VET

Dr. Michelle Caldwell

INVOICE

10157

DATE

4/4/2023

No focal lesions are visualized in the liver to explain the elevation in liver enzymes described. Consider the possibility of elevations in response to any of the medications associated with the eyes? Additionally, many common antibiotics can cause liver enzymes elevations, such as Clavamox, Doxycycline, etc. Also consider the possibility of leptospirosis (possibly the previous episode.)

The previous bile acid evaluation was mildly elevated, this would be something I would watch closely to ensure it does not appear more elevated over time, as rarely liver enzymes can go down with loss of function. (I do not think that is the case here) The changes observed in the gallbladder are minimal but there is a small chance of mild cholestasis events. In this case you could consider chronic ursodiol therapy in case it helps to promote bile flow and potentially reduce these episodes.

