

PATIENT PRESENTING CLINICAL SIGNS

Caleb Clifford

SPECIES

Feline

BREED

DSH

SEX

Intact Male

AGE

9 Months

WEIGHT

4.5 kg

INTERPRETED BY

Kathleen Sennello DVM,
MS, Diplomate ACVIM
(Small Animal Internal
Medicine)

IMAGING PERFORMED BY

Loetitia Saint-Jacques,
LVT

HOSPITAL NAME

AMC of Reno

REFERRING VET

Dr. Eryn Taormino

INVOICE

46402

DATE

4/4/23

No murmur. History of sibling cat having death during anesthesia - suspected FIP or thromboembolism. Assess prior to anesthesia. Echo done w/Sonopath- Echo: Overtly normal cardiac structure and function. The LV wall thickness is normal and there is no evidence of elevated left atrial pressure. No obvious congenital issues are documented. The ECG is unremarkable with a normal sinus rhythm. These findings would suggest mild cardiomegaly on the CXR is a normal variant. These films should be used as a baseline for future comparison.

ULTRASONOGRAPHIC EXAMINATION OF THE ABDOMEN

Urinary System

The urinary bladder is moderately distended with anechoic urine. The Bladder wall, trigone, ureteral papillae and visible urethra (to a depth of 2cm) appear normal with no evidence of wall thickening, mucosal irregularities, masses or cystic calculi.

The left kidney has a normal shape and size (3.91 cm). Overall echogenicity is normal with adequate corticomedullary distinction and a typical 1:3 cortex:medulla ratio. There is no evidence of focal perinephric inflammation or effusion. There is no evidence of pyelectasia, nephroliths, infarcts or hydroureter. Renal vasculature is normal.

The right kidney has a normal shape and size (4.0 cm) with a small cortical cyst in the cranial pole at 0.55 cm. Overall echogenicity is normal with adequate corticomedullary distinction and a typical 1:3 cortex:medulla ratio. There is no evidence of focal perinephric inflammation or effusion. There is no evidence of pyelectasia, nephroliths, infarcts or hydroureter. Renal vasculature is normal.

Adrenal Glands

The left adrenal gland is normal in size measuring 0.32 cm at the caudal pole. It is observed in its normal position cranial to the left renal artery. It is normal in appearance (uniformly hypoechoic) and shape with no evidence of a mass effect.

The right adrenal gland is normal in size measuring 0.34 cm at the caudal pole. It is observed in its normal position between the cranial aspect of the right kidney and the caudal vena cava. It is normal in appearance (uniformly hypoechoic) and shape with no evidence of a mass effect.

Spleen

The spleen is subjectively normal in size (0.81 cm), echotexture is homogenous, and the splenic capsule is smooth with no irregularities. The blood flow through the hilus and splenic parenchyma appears normal. No focal parenchymal abnormalities are visualized.

Liver

The liver is subjectively normal in size, and echogenicity with smooth peripheral margins. The parenchyma is homogenous echotexture. The visible portions of the vasculature and biliary tract appear normal. No focal nodules or cystic lesions are observed.

The gallbladder lumen is moderately distended. The wall of the gall bladder is not thickened and has a smooth mucosal surface. Luminal contents are mild and primarily anechoic. The cystic and common bile ducts are normal/not visible.



PATIENT *Gastrointestinal*

Caleb Clifford

The stomach contains minimal luminal contents. It measures at a normal thickness of <0.36cm with some variability due to the presence of rugal folds. The distinction of the gastric wall layers is adequate and there is no impression of reduced peristaltic activity. No masses or focal lesions were observed.

SPECIES

Feline

The visualized areas of duodenum, jejunum and ileum have a relatively uniform diameter with minimal fluid distension. Wall thickness is normal. Bowel loops follow a curvilinear path with distinct wall layering maintaining the typical 1:3 muscularis:mucosa layer ratio. Duodenum wall measures 0.34 cm. Jejunum wall measures 0.18 cm. Visualized peristalsis appears appropriate. There were no focal lesions consistent with obstruction or a mass effect observed.

BREED

DSH

SEX

Intact Male

The ileocecal junction was visualized and exhibited normal intact wall layering and is subjectively of normal thickness. Sections of colon are visualized with formed fecal material and gas shadowing distally. There is no observed focal or generalized colon wall thickening or loss of layering.

AGE

9 Months

Pancreas

The area of the pancreas is normal and isoechoic to surrounding mesentery. There is no evidence of nodules or cystic lesions. There is no evidence of regional mesenteric inflammation or fluid.

WEIGHT

4.5 kg

Free Abdomen

Evaluation of the peritoneal cavity did not reveal any evidence of effusion. There are numerous prominent mesenteric lymph nodes. The left sublumbar lymph node measures 0.55 cm. The right measures 0.57 cm. Pancreaticoduodenal lymph node measures 0.53 cm. A mesenteric lymph node is visualized at 0.75 cm. The omentum is of normal echogenicity.

INTERPRETED BY

Kathleen Sennello DVM,
MS, Diplomate ACVIM
(Small Animal Internal
Medicine)

Both testicles are visualized and appear within normal limits.

IMAGING PERFORMED BY

Loetitia Saint-Jacques,
LVT

ULTRASONOGRAPHIC FINDINGS

- Cystic structure in the cranial pole of the right kidney – findings are most consistent with a benign renal cyst.
- Visible/prominent mesenteric lymph nodes – This is likely a normal finding in a young cat. Recommend continued monitoring.

HOSPITAL NAME

AMC of Reno

INTERPRETATION OF THE FINDINGS & FURTHER RECOMMENDATIONS

Today's scan appears relatively normal for a young cat. Recommend bloodwork and a urinalysis to assess organ function. Subjectively, the kidneys are on the big side of normal (normal is up to 4.0-4.5 cm), and this is a big cat, so I suspect this is within normal limits.

REFERRING VET

Dr. Eryn Taormino

INVOICE

46402

DATE

4/4/23



PATIENT

Caleb Clifford

SPECIES

Feline

BREED

DSH

SEX

Intact Male

AGE

9 Months

WEIGHT

4.5 kg

INTERPRETED BY

Kathleen Sennello DVM,
MS, Diplomate ACVIM
(Small Animal Internal
Medicine)

IMAGING PERFORMED BY

Loetitia Saint-Jacques,
LVT

HOSPITAL NAME

AMC of Reno

REFERRING VET

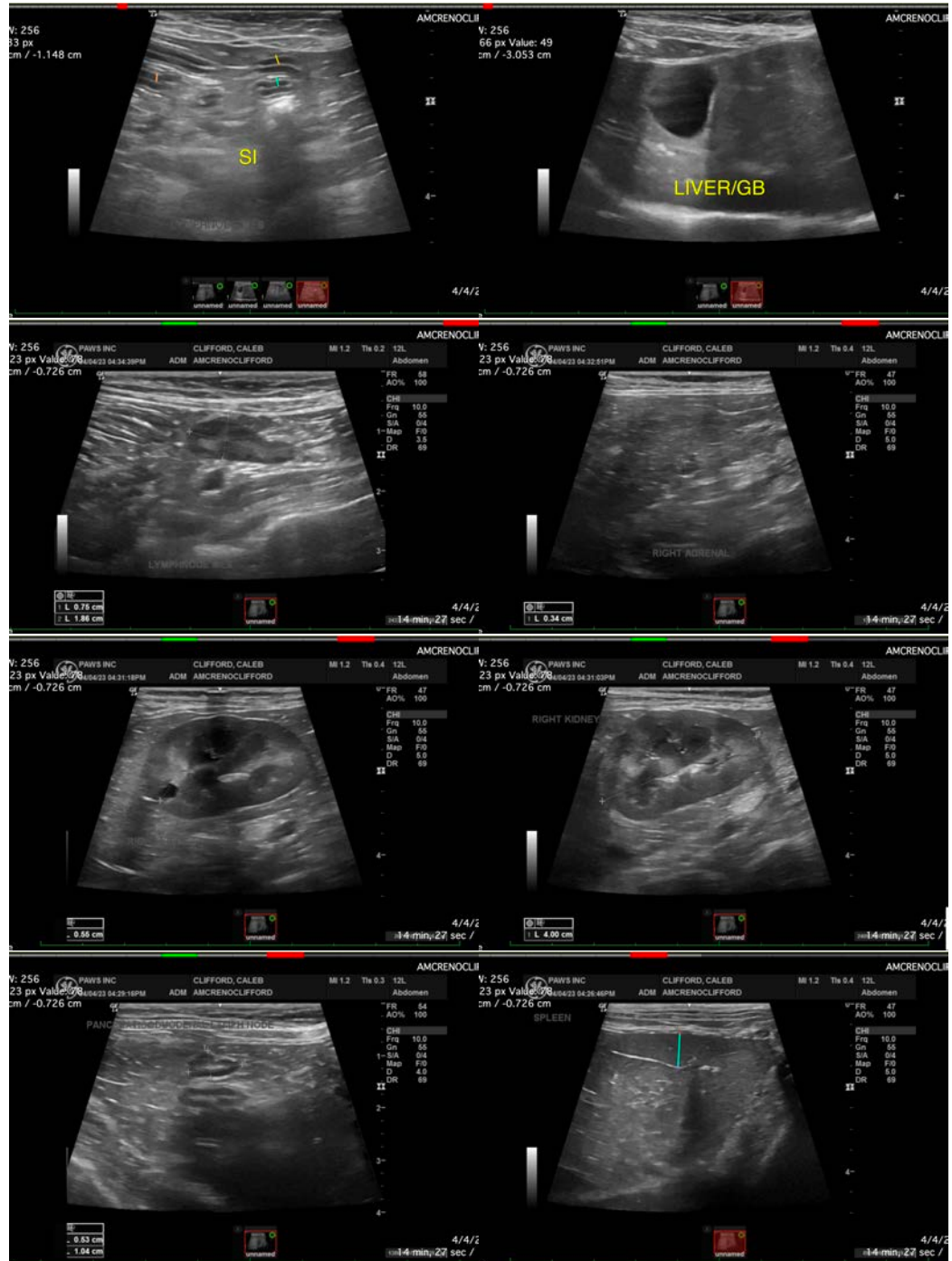
Dr. Eryn Taormino

INVOICE

46402

DATE

4/4/23





PATIENT

Caleb Clifford

SPECIES

Feline

BREED

DSH

SEX

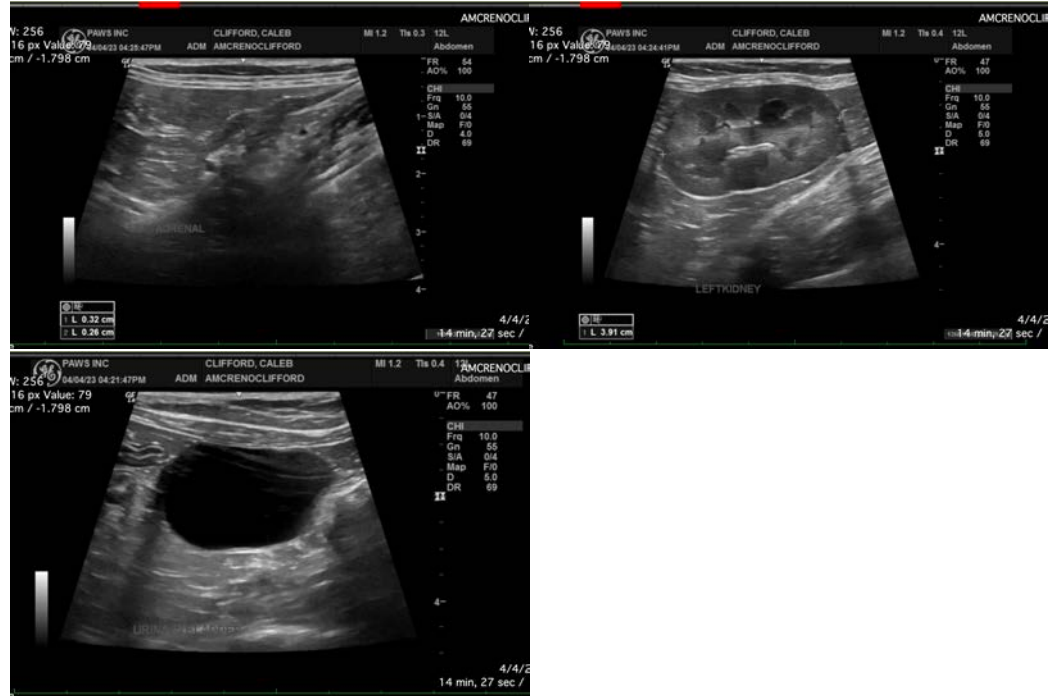
Intact Male

AGE

9 Months

WEIGHT

4.5 kg



INTERPRETED BY

Kathleen Sennello DVM,
MS, Diplomate ACVIM
(Small Animal Internal
Medicine)

**IMAGING
PERFORMED BY**

Loetitia Saint-Jacques,
LVT

HOSPITAL NAME

AMC of Reno

REFERRING VET

Dr. Eryn Taormino

INVOICE

46402

DATE

4/4/23

The information and recommendations provided are based on the images presented by the referring veterinarian/sonographer. No evaluation can be communicated regarding pathology that was not visible in the image/video clips provided.

Thank you for this referral. If the clinical or image interpretation does not parallel your findings or if I can be of any further assistance please contact me.

Kathleen Sennello DVM,MS, Diplomate ACVIM (Small animal Internal Medicine)

kathleen.sennello@sonopath.com