



PATIENT

Salem Watson

SPECIES

Feline

BREED

DSH

SEX

Neutered Male

AGE

9 Years

WEIGHT

10.8 lbs

INTERPRETED BY

Kathleen Sennello DVM,
 MS, Diplomate ACVIM
 (Small Animal Internal
 Medicine)

**IMAGING
 PERFORMED BY**

Kelly Reschny

HOSPITAL NAME

Dog and Cat Clinic of
 Niagara

REFERRING VET

Dr. Habib

INVOICE

74839

DATE

4/30/26

PRESENTING CLINICAL SIGNS

Weight loss, vomits here and there and sometimes diarrhea.

ULTRASONOGRAPHIC EXAMINATION OF THE ABDOMEN

Urinary System

The urinary bladder is moderately distended with echogenic urine. In the dependent portion of the urinary bladder there is a focal hyperechoic shadowing structure most consistent with a stone, measuring 1.15 cm in diameter. The region of the trigone, ureteral papillae and proximal urethra appear free of any mass lesions or calculi.

The left kidney has a normal shape and size (3.85 cm). Overall echogenicity is normal with adequate corticomedullary distinction and a typical 1:3 cortex:medulla ratio. There is no evidence of focal perinephric inflammation or effusion. There is no evidence of pyelectasia, nephroliths, infarcts or hydroureter. Renal vasculature is normal.

The right kidney has a normal shape and size (4.43 cm). Overall echogenicity is normal with adequate corticomedullary distinction and a typical 1:3 cortex:medulla ratio. There is no evidence of focal perinephric inflammation or effusion. There is no evidence of pyelectasia, nephroliths, infarcts or hydroureter. Renal vasculature is normal.

Adrenal Glands

The left adrenal gland is normal in size measuring 0.26 cm at the caudal pole. It is observed in its normal position cranial to the left renal artery. It is normal in appearance (uniformly hypoechoic) and shape with no evidence of a mass effect.

The right adrenal gland is normal in size measuring 0.42 cm at the caudal pole. It is observed in its normal position between the cranial aspect of the right kidney and the caudal vena cava. It is normal in appearance (uniformly hypoechoic) and shape with no evidence of a mass effect.

Spleen

The spleen is borderline large, hypoechoic and mottled. The blood flow through the hilus and splenic parenchyma appears normal. There are hyperechoic nodules visualized associated with the spleen, examples measure 0.51 cm and 0.37 cm, most consistent with benign myelolipomas.

Liver

The liver is subjectively normal in size, and echogenicity with smooth peripheral margins. The parenchyma is homogenous echotexture. The visible portions of the vasculature and biliary tract appear normal. No focal nodules or cystic lesions are observed.

The gall bladder lumen is moderately distended. The wall of the gall bladder is not thickened and has a smooth mucosal surface. Luminal contents are mild and likely incidental at this time. The cystic and common bile ducts are normal/not visible.



PATIENT

Salem Watson

SPECIES

Feline

BREED

DSH

SEX

Neutered Male

AGE

9 Years

WEIGHT

10.8 lbs

INTERPRETED BY

Kathleen Sennello DVM,
 MS, Diplomate ACVIM
 (Small Animal Internal
 Medicine)

IMAGING PERFORMED BY

Kelly Reschny

HOSPITAL NAME

Dog and Cat Clinic of
 Niagara

REFERRING VET

Dr. Habib

INVOICE

74839

DATE

4/30/26

Gastrointestinal

The stomach contains mild to moderate fluid and gas. It measures at a normal thickness of <0.36cm with some variability due to the presence of rugal folds. The distinction of the gastric wall layers is adequate and there is no impression of reduced peristaltic activity. No masses or focal lesions were observed.

The small intestine appears diffusely significantly fluid distended. The bowel wall appears thickened, measuring at 0.27 cm. Some areas appear more significantly thickened with reduced detail of wall layering, measuring up to 0.36 cm. The duodenum wall measures 0.46 cm. No focal obstructive lesions are visualized findings are suggestive of diffuse ileus.

Sections of colon are visualized with non-formed fecal material and gas shadowing distally. The descending colon appears prominent and thickened with reduced detail of wall layering, measuring at 0.36 cm.

Pancreas

The left limb of the pancreas is prominent and mottled compared to the surrounding isoechoic mesentery. There is no evidence of nodules or cystic lesions. There is scant free mesenteric fluid and inflammation in the left cranial quadrant of the abdomen.

Free Abdomen

The omentum appears diffusely hyperechoic with scant surrounding free fluid.

In the left cranial aspect of the abdomen there are numerous ill-defined, hypoechoic omental nodules, examples measure 0.49, 0.83, and 0.67 cm. Some of these could represent mesenteric lymph nodes.

There is a large, irregular, hypoechoic nodule/mass effect visualized adjacent to the cranial aspect of the spleen measuring 0.90 cm x 2.07 cm (a splenic mass effect cannot be ruled out).

ULTRASONOGRAPHIC FINDINGS

- Suspended echogenic debris and a dependent mineralization/stone visualized in the urinary bladder – Recommend urinalysis, culture and radiographs to confirm.
- Subjectively large, hypoechoic, mottled spleen – The diffuse splenic changes are non-specific and could be consistent with lymphoid hyperplasia, extramedullary hematopoiesis, infiltrative neoplasia, inflammation, other. Cytology or histopathology would be necessary to get a definitive diagnosis.
- Pancreatic changes most consistent with pancreatic remodeling +/- chronic pancreatitis.
- Diffusely fluid distended small bowel with a thickened wall with some areas exhibiting reduced detail of wall layering – Findings are most consistent with severe ileus (a focal distal obstructive lesion cannot be definitively ruled out) and infiltrative disease or significant inflammation to the bowel wall.
- Colonic wall thickening with reduced detail of wall layering – Findings are most consistent with severe inflammatory or early neoplastic infiltration.
- Small amount of free abdominal fluid, mesenteric inflammation, and omental nodules –



PATIENT

Salem Watson

Findings are concerning for metastatic disease/carcinomatosis.

- Irregular/nodular mass effect medial to the spleen– Findings are most consistent with a large omental nodule or a splenic mass lesion-a neoplastic lesion is suspected.

SPECIES

Feline

INTERPRETATION OF THE FINDINGS & FURTHER RECOMMENDATIONS

BREED

DSH

The small intestine appears diffusely fluid distended with a thickened wall and some areas exhibiting reduced detail of wall layering. Additionally, the colon appears thickened with reduced detail of wall layering. Findings are concerning for diffuse ileus and severe inflammatory or neoplastic change. An obstructive lesion is not visualized but cannot be definitively ruled out.

SEX

Neutered Male

The spleen is large, hypoechoic and mottled. Recommend a fine needle aspirate to evaluate for possible underlying neoplasia.

AGE

9 Years

Medial to the spleen the omentum is highly reactive with numerous hypoechoic nodules. These are concerning for omental nodules, and an irregular mass effect/large nodule is visualized adjacent to the spleen, most consistent with a very large omental nodule (or possibly splenic lesion?). Recommend a fine needle aspirate of the large omental nodule and fluid analysis and cytology of a fluid sample.

WEIGHT

10.8 lbs

There is focal mineralization/stone visualized in the dependent portion of the urinary bladder. Correlate with urinalysis +/- culture and radiographs.

INTERPRETED BY

Kathleen Sennello DVM,
 MS, Diplomate ACVIM
 (Small Animal Internal
 Medicine)

Recommend three view thoracic radiographs to evaluate for possible concurrent thoracic disease/involvement (disregard if this has already been done).

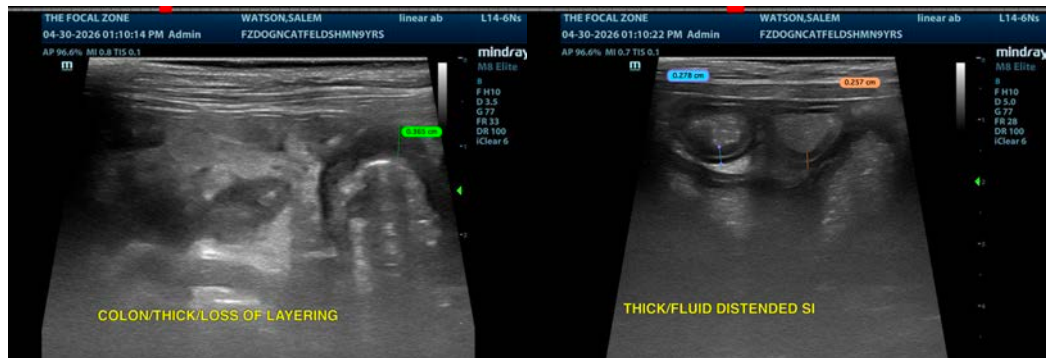
IMAGING PERFORMED BY

Kelly Reschny

If a cytologic diagnosis can be obtained, recommend consultation with veterinary oncologist regarding treatment options and prognosis. If a diagnosis cannot be obtained, surgical biopsies may be necessary.

HOSPITAL NAME

Dog and Cat Clinic of
 Niagara



REFERRING VET

Dr. Habib

INVOICE

74839

DATE

4/30/26



PATIENT

Salem Watson

SPECIES

Feline

BREED

DSH

SEX

Neutered Male

AGE

9 Years

WEIGHT

10.8 lbs

INTERPRETED BY

Kathleen Sennello DVM,
 MS, Diplomate ACVIM
 (Small Animal Internal
 Medicine)

**IMAGING
 PERFORMED BY**

Kelly Reschny

HOSPITAL NAME

Dog and Cat Clinic of
 Niagara

REFERRING VET

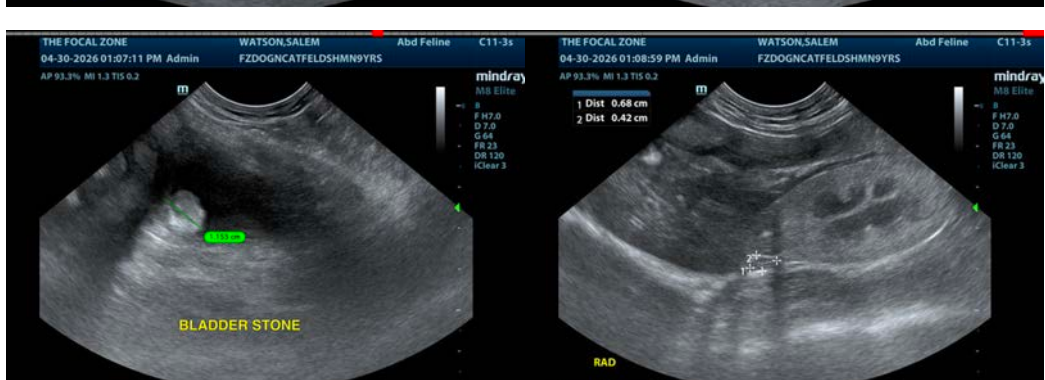
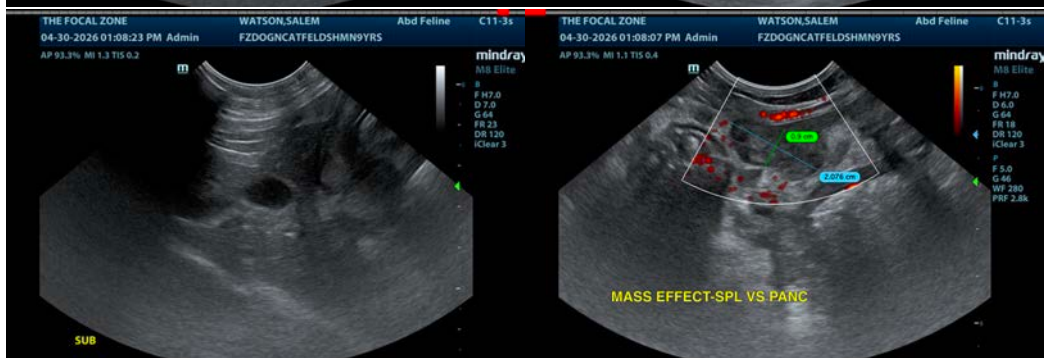
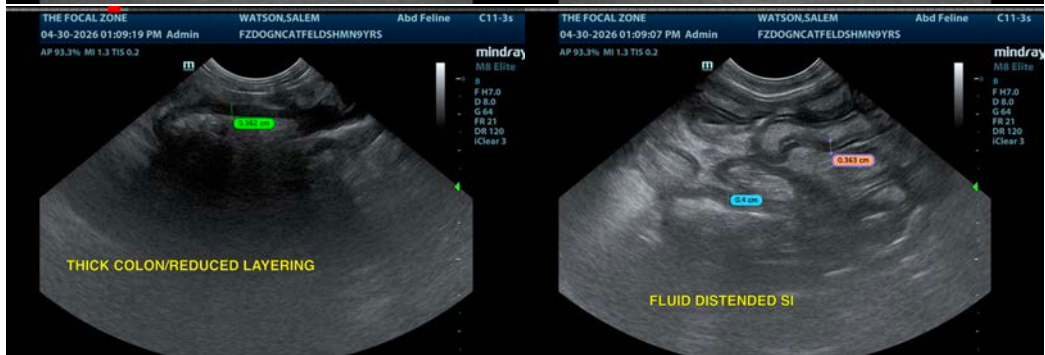
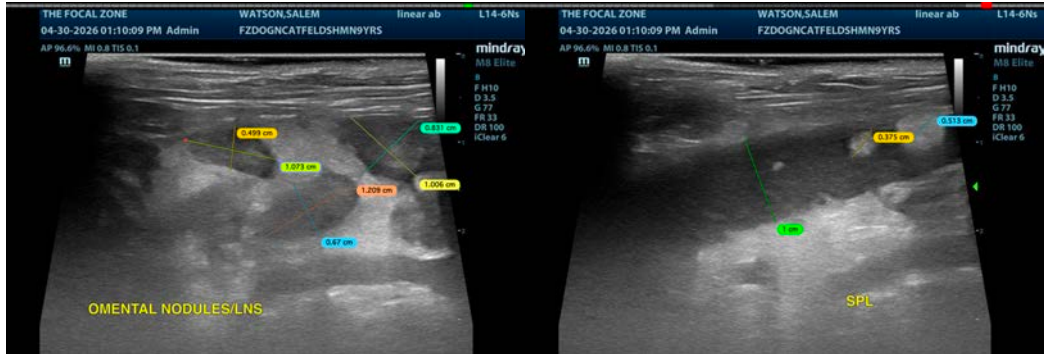
Dr. Habib

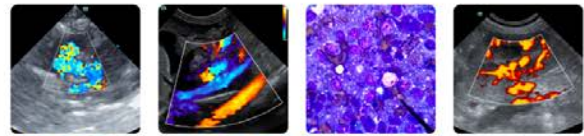
INVOICE

74839

DATE

4/30/26





PATIENT

Salem Watson

SPECIES

Feline

BREED

DSH

SEX

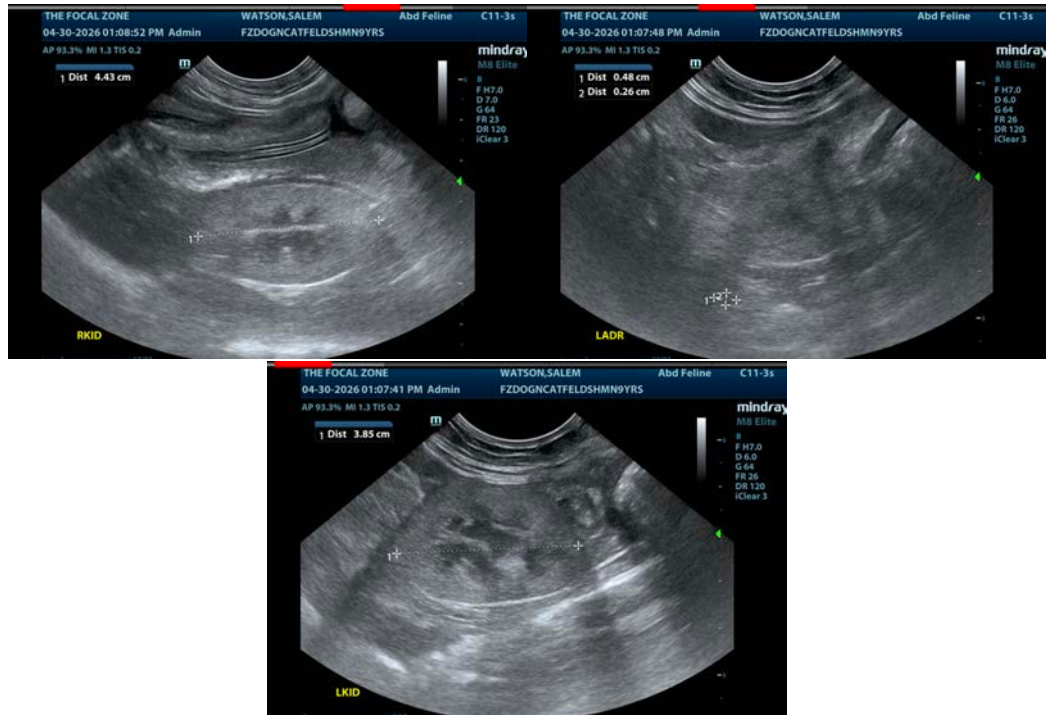
Neutered Male

AGE

9 Years

WEIGHT

10.8 lbs



INTERPRETED BY

Kathleen Sennello DVM,
MS, Diplomate ACVIM
(Small Animal Internal
Medicine)

The information and recommendations provided are based on the images presented by the referring veterinarian/sonographer. No evaluation can be communicated regarding pathology that was not visible in the image/video clips provided.

Thank you for this referral. If the clinical or image interpretation does not parallel your findings or if I can be of any further assistance please contact me.

IMAGING PERFORMED BY

Kelly Reschny

Kathleen Sennello DVM,MS, Diplomate ACVIM (Small animal Internal Medicine)

info@sonopath.com

HOSPITAL NAME

Dog and Cat Clinic of
Niagara

REFERRING VET

Dr. Habib

INVOICE

74839

DATE

4/30/26