



DATE PRESENTING CLINICAL SIGNS

4/30/26 **Patient History:** Losing weight, trouble eating, vomiting foam sometimes.

PATIENT Current Medications: None listed.

Bella Orefice **Labwork Results:** Labwork not attached.

Date of Previous IntraPet Ultrasound: No previous.

Sedation: TEL/TORB.

Stat Report: Declined at this time.

SPECIES Imaging Performed by: Stephanie Warga RDCS, RVT.

Feline

ULTRASONOGRAPHIC EXAMINATION OF THE ABDOMEN

BREED *Urinary System*

DSH The urinary bladder is moderately distended with anechoic urine. The Bladder wall, trigone, ureteral papillae and visible urethra (to a depth of 2cm) appear normal with no evidence of wall thickening, mucosal irregularities, masses or cystic calculi.

SEX

Spayed Female

The left kidney has a normal shape and size (4.23 cm). Overall echogenicity is normal with adequate corticomedullary distinction and a typical 1:3 cortex:medulla ratio. There is no evidence of focal perinephric inflammation or effusion. There is no evidence of pyelectasia, nephroliths, infarcts or hydroureter. Renal vasculature is normal.

AGE

12/6/16

WEIGHT

12.6 lbs

The right kidney has a normal shape and size (4.58 cm). Overall echogenicity is normal with adequate corticomedullary distinction and a typical 1:3 cortex:medulla ratio. There is no evidence of focal perinephric inflammation or effusion. There is no evidence of pyelectasia, nephroliths, infarcts or hydroureter. Renal vasculature is normal.

INTERPRETED BY

Kathleen Sennello DVM,
MS, Diplomate ACVIM
(Small Animal Internal
Medicine)

Adrenal Glands

The left adrenal gland is normal in size measuring 0.47 cm at the caudal pole. It is observed in its normal position cranial to the left renal artery. It is normal in appearance (uniformly hypoechoic) and shape with no evidence of a mass effect.

HOSPITAL NAME

Honeygo Animal
Hospital

The right adrenal gland is normal in size measuring 0.40 cm at the caudal pole. It is observed in its normal position between the cranial aspect of the right kidney and the caudal vena cava. It is normal in appearance (uniformly hypoechoic) and shape with no evidence of a mass effect.

REFERRING VET

Dr. Wright-Weichert

Spleen

The spleen is subjectively normal in size (1.04 cm), echotexture is homogenous, and the splenic capsule is smooth with no irregularities. The blood flow through the hilus and splenic parenchyma appears normal. No focal parenchymal abnormalities are visualized.

INVOICE

74873

Liver

The liver is subjectively normal in size, and echogenicity with smooth peripheral margins. The parenchyma is homogenous echotexture. The visible portions of the vasculature and biliary tract appear normal. No focal nodules or cystic lesions are observed.

The gall bladder lumen is moderately distended. The wall of the gall bladder is not thickened and has a smooth mucosal surface. There is a moderate amount of non-organized echogenic debris. The cystic and common bile ducts are normal/not visible.

Gastrointestinal

The stomach contains minimal luminal contents. It measures at a normal thickness of 0.27 cm with some variability due to the presence of rugal folds. The distinction of the gastric wall layers is adequate and there is no impression of reduced peristaltic activity. No masses or focal lesions were observed.

The visualized areas of duodenum, jejunum and ileum have a uniform diameter with minimal fluid distension. Wall thickness is increased. Bowel loops follow a typical curvilinear path. Some areas have reduced detail of wall layering. Duodenum wall measures 0.28 cm. Jejunum wall measures 0.34 cm. Ileum wall measures 0.46 cm. Visualized peristalsis appears appropriate. The small intestine appears diffusely thickened with a very prominent muscularis layer. Additionally, there is a focal wall thickening and loss of layering creating a distinct intestinal mass effect measuring 4.0 cm x 3.35 cm. In this area the bowel wall measures 2.0 cm in thickness.

The ileocecal junction was visualized and exhibited normal intact wall layering and is subjectively of normal thickness. Sections of colon are visualized with formed fecal material and gas shadowing distally. There is no observed focal or generalized colon wall thickening or loss of layering.

Pancreas

The pancreas is visible/mildly mottled in the left limb. There is no evidence of nodules or cystic lesions. There is no evidence of regional mesenteric inflammation or fluid.

Free Abdomen

Evaluation of the peritoneal cavity did not reveal any evidence of effusion. There are occasional prominent mesenteric lymph nodes. There is a large, hypoechoic, slightly irregular mid abdominal mass effect measuring 5.87 cm x 3.18 cm, most consistent with an enlarged mesenteric lymph node. Prominent mesenteric lymph nodes are visualized measuring 0.47, 0.52, and 0.59 cm in diameter. The omentum is diffusely hyperechoic.

PRIMARY FINDINGS

- Diffusely thickened small intestine with a very prominent muscularis layer and a focal mass effect exhibiting severe focal wall thickening and loss of layering – Findings are most consistent with a diffuse enteropathy with significant concern for diffuse round cell neoplasia and a focal mass effect most consistent with a neoplastic lesion (round cell neoplasia, carcinoma, other). Other differentials are possible.
- Focal mid abdominal mass effect – Findings are suggestive of an enlarged mesenteric lymph node.

SECONDARY FINDINGS

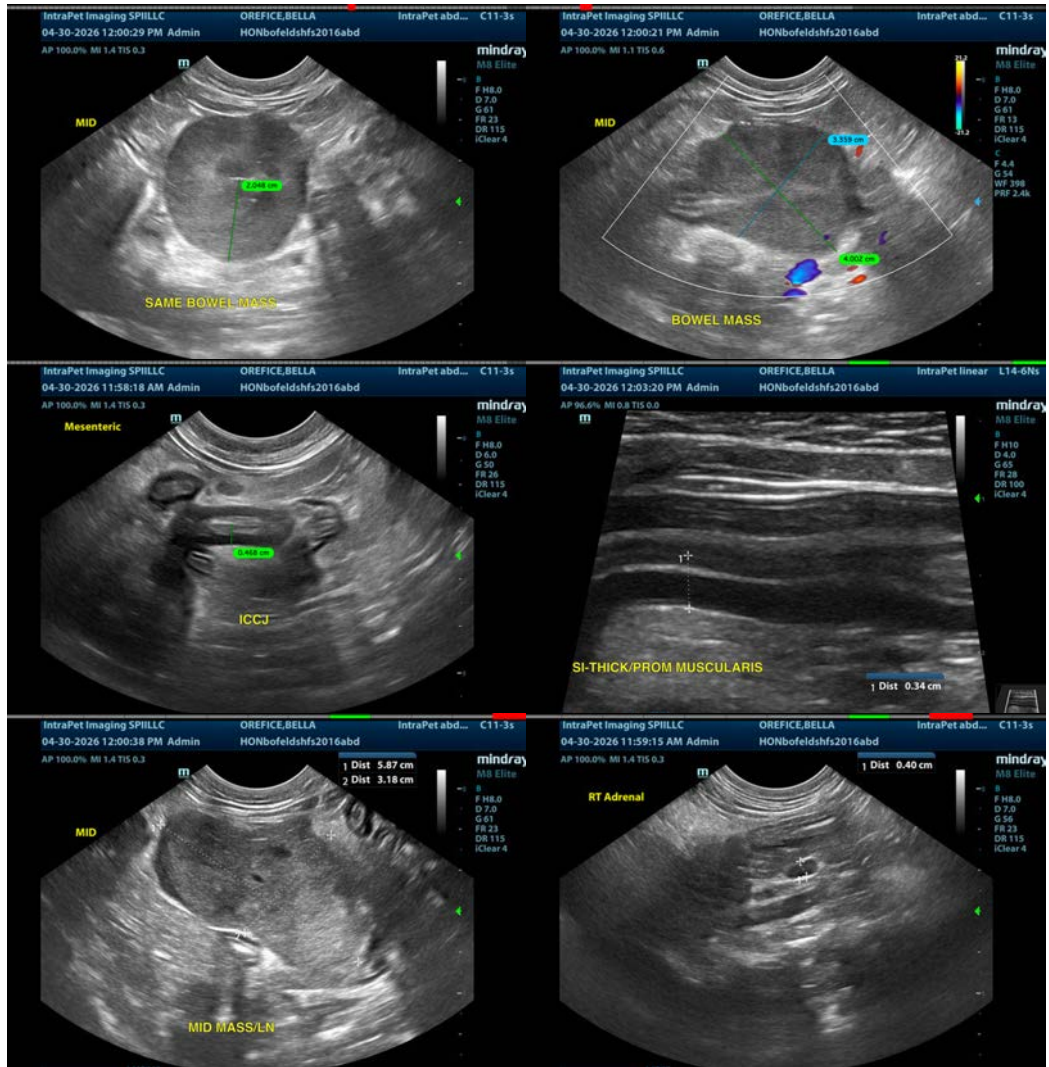
- Pancreatic changes consistent with mild pancreatic remodeling.
- Moderate gallbladder debris – The significance of the aggregated gallbladder debris is unclear. This could represent an early mucocele, cholestasis, or may be secondary to fasting. Incidental gall bladder debris is less common in cats.

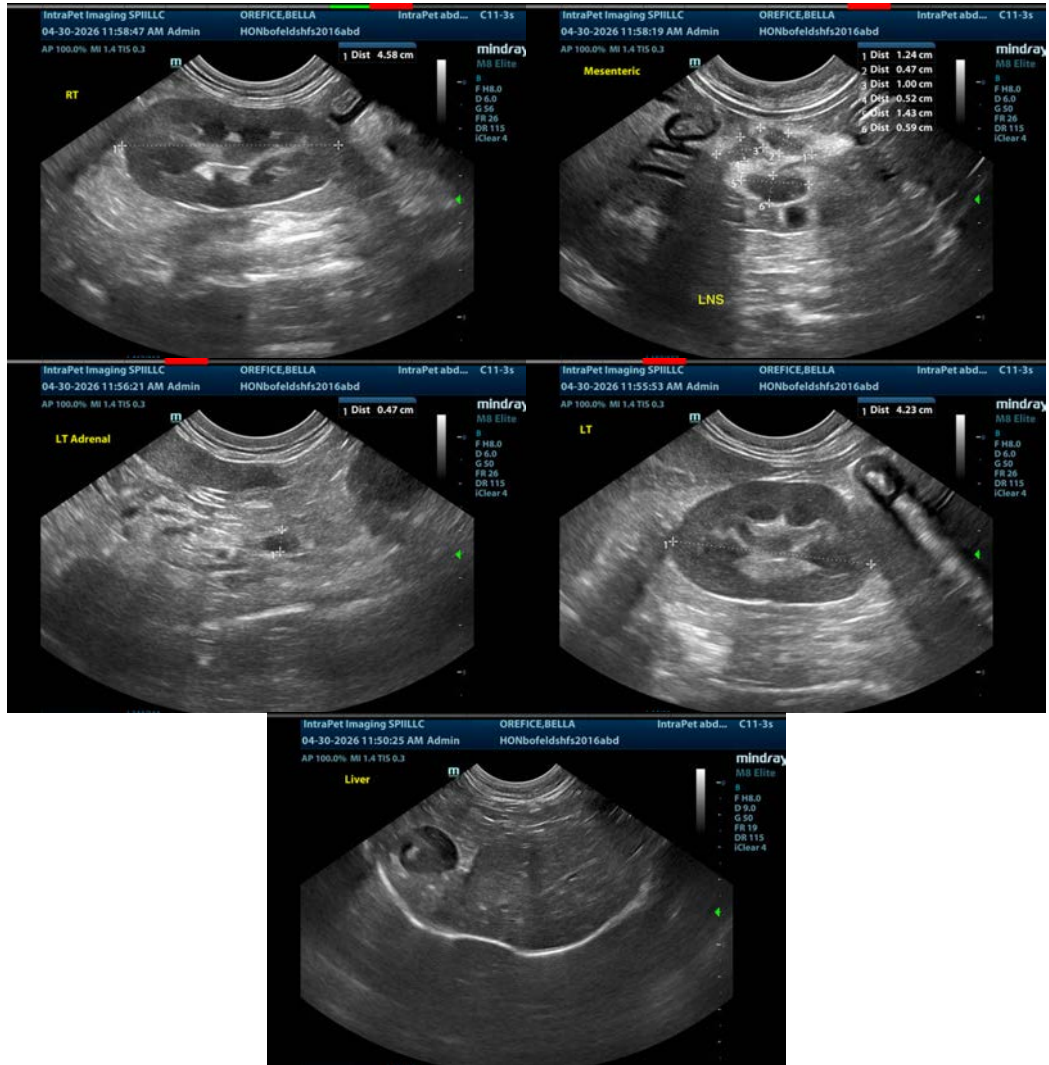
INTERPRETATION OF THE FINDINGS & FURTHER RECOMMENDATIONS

The small intestine appears diffusely thickened with a very prominent muscularis layer. Additionally, there is a focal bowel mass lesion visualized, characterized by severe wall thickening and loss of layering creating a discrete mass effect. In the mid abdomen there is a large, irregular, hypoechoic mass effect most consistent

with a severely enlarged mesenteric lymph node. Recommend a fine needle aspirate of a mesenteric lymph node and the bowel mass lesion for cytologic evaluation. If a diagnosis can be obtained, recommend consultation with a veterinary oncologist regarding best treatment options and prognosis.

If not already done, recommend 3-view thoracic radiographs.





The information and recommendations provided are based on the images presented by the referring veterinarian/sonographer. No evaluation can be communicated regarding pathology that was not visible in the image/video clips provided.

Thank you for this referral. If the clinical or image interpretation does not parallel your findings or if I can be of any further assistance please contact me.

Kathleen Sennello DVM,MS, Diplomate ACVIM (Small animal Internal Medicine)
info@sonopath.com