

**DATE PRESENTING CLINICAL SIGNS**

4/29/22 History of chronic vomiting of food, some lethargy.

PATIENT Current Medications: None.

Meowzer DuBois

Lab Results: WNL.

Date of Previous IntraPet Ultrasound: No previous.

Sedation: Not required to complete full diagnostic ultrasound.

Stat Report: Not requested.

SPECIES

Feline

ULTRASONOGRAPHIC EXAMINATION OF THE ABDOMEN**BREED *Urinary System***

DSH

The urinary bladder is moderately distended with anechoic urine. The Bladder wall, trigone, ureteral papillae and visible urethra (to a depth of 2cm) appear normal with no evidence of wall thickening, mucosal irregularities, masses or cystic calculi.

SEX

Neutered Male

The left kidney has a normal shape and size (4.13 cm). Overall echogenicity is normal with adequate corticomedullary distinction and a typical 1:3 cortex:medulla ratio. There is no evidence of perinephric inflammation or effusion. There is no evidence of pyelectasia, nephroliths, infarcts or hydroureter. Renal vasculature is normal.

AGE

5/3/14

The right kidney has a normal shape and size (3.28 cm). Overall echogenicity is normal with adequate corticomedullary distinction and a typical 1:3 cortex:medulla ratio. There is no evidence of perinephric inflammation or effusion. There is no evidence of pyelectasia, nephroliths, infarcts or hydroureter. Renal vasculature is normal.

WEIGHT

10.2 Pounds

Adrenal Glands**INTERPRETED BY**

Kathleen Sennello DVM,
MS, Diplomate ACVIM
(Small Animal Internal
Medicine)

The region of left adrenal (Cranial to left renal artery) is unremarkable but the adrenal is not distinctly visualized. No evidence of a mass effect.

The region of the right adrenal (between right cranial kidney and vena cava) is unremarkable, but the adrenal is not distinctly visualized. No evidence of a mass effect.

IMAGING PERFORMED BY

Andi Parkinson RDMS

Spleen

The spleen is subjectively normal in size, echotexture is homogenous, and the splenic capsule is smooth with no irregularities. The blood flow through the hilus and splenic parenchyma appears normal. No focal parenchymal abnormalities are visualized.

HOSPITAL NAME

Aberdeen Vet Clinic

Liver

The liver is subjectively normal in size, and echogenicity with smooth peripheral margins. The parenchyma is homogenous echotexture. The visible portions of the vasculature and biliary tract appear normal. No focal nodules or cystic lesions are observed.

REFERRING VET

Dr. Fritz

The gallbladder lumen is moderately distended. The wall of the gall bladder is not thickened and has a smooth mucosal surface. Luminal contents are primarily anechoic. The cystic and common bile ducts are normal/not visible.

INVOICE

37297

Gastrointestinal

The stomach contains minimal luminal contents. It measures at a normal thickness of <0.36cm with some variability due to the presence of rugal folds. The distinction of the gastric wall layers is adequate and there is no impression of reduced peristaltic activity. No masses or focal lesions were observed.

The visualized areas of duodenum, jejunum and ileum have a relatively uniform diameter with minimal fluid distension. Wall thickness is normal. Bowel loops follow a curvilinear path with distinct wall layering maintaining the typical 1:3 muscularis:mucosa layer ratio. Jejunum wall measured 0.28 cm. Visualized peristalsis appears appropriate. There were no focal lesions consistent with obstruction or a mass effect observed.

The ileocecal junction was visualized and exhibited normal intact wall layering and is subjectively of normal thickness. Sections of colon are visualized with formed fecal material and gas shadowing distally. There is no observed focal or generalized colon wall thickening or loss of layering.

Pancreas

The pancreas is normal and isoechoic to surrounding mesentery. There is no evidence of nodules or cystic lesions. There is no evidence of regional mesenteric inflammation or fluid.

Free Abdomen

Evaluation of the peritoneal cavity did not reveal any evidence of effusion. One prominent mesenteric lymph node is visualized at 0.32 cm. The omentum is of normal echogenicity.

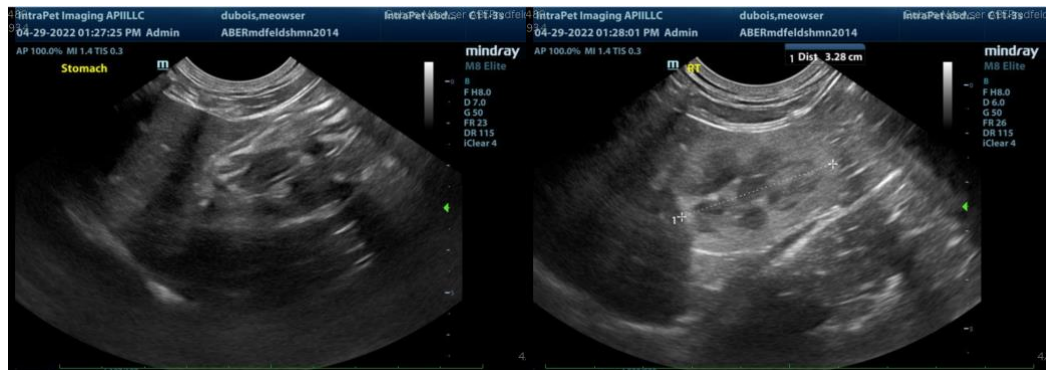
ULTRASONOGRAPHIC FINDINGS

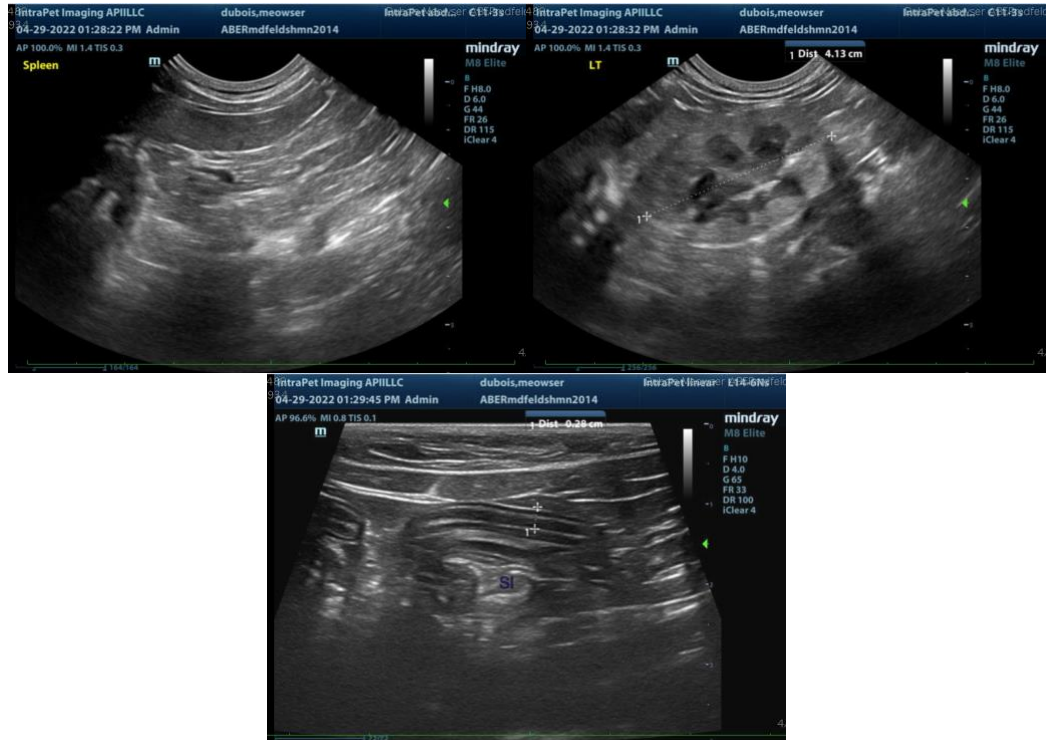
- No significant ultrasonographic lesions observed on today's exam

INTERPRETATION OF THE FINDINGS & FURTHER RECOMMENDATIONS

If metabolic causes such as hyperthyroidism, renal disease, etc. have been ruled out based on routine bloodwork, then consider primary GI causes. There are many causes for vomiting that cannot be diagnosed by ultrasound alone. Consider such differentials as food allergy/dietary intolerance, chronic pancreatitis, dietary indiscretion, IBD, and less likely intestinal neoplasia.

- Consider a novel protein/hydrolyzed protein prescription diet.
- Consider a GI panel to Texas A&M for a qualitative fPLI, TLI, cobalamin and folate to further evaluate the pancreas and small intestine.
- If chronic vomiting persists despite a dietary change, consider obtaining GI biopsies.
- Consider three view thoracic radiographs to rule out concurrent thoracic disease/involvement.





The information and recommendations provided are based on the images presented by the referring veterinarian/sonographer. No evaluation can be communicated regarding pathology that was not visible in the image/video clips provided.

Thank you for this referral. If the clinical or image interpretation does not parallel your findings or if I can be of any further assistance please contact me.

Kathleen Sennello DVM,MS, Diplomate ACVIM (Small animal Internal Medicine)
kathleen.sennello@sonopath.com