



PATIENT PRESENTING CLINICAL SIGNS

Lily Gonzales marked elevation in ALP
Abnormal PE/Chem/CBC/UA Results: ALP 1922 (5-131)

SPECIES ULTRASONOGRAPHIC EXAMINATION OF THE ABDOMEN

Canine

Urinary System

BREED

Shih Poo

The urinary bladder is moderately distended with anechoic urine. The Bladder wall, trigone, ureteral papillae and visible urethra (to a depth of 2cm) appear normal with no evidence of wall thickening, mucosal irregularities, or masses. There is a small pile of mildly shadowing, hyperechoic debris in the dependent portion of the urinary bladder. This measures approximately 0.64 cm in length and is most likely consistent with a pile of mineralized sandy debris or small stones.

SEX

Spayed Female

The left kidney has a normal shape and size (4.83 cm) with a large cyst in the caudal pole measuring 1.18 cm. Overall echogenicity is slightly hyperechoic with poor corticomedullary distinction and a typical 1:3 cortex:medulla ratio. There is no evidence of perinephric inflammation or effusion. There is no evidence of pyelectasia, nephroliths, infarcts or hydroureter. Renal vasculature is normal.

AGE

11 Years

The right kidney has a normal shape and size (4.46 cm) with small cortical cysts. Overall echogenicity is slightly hyperechoic with poor corticomedullary distinction and a typical 1:3 cortex:medulla ratio. There is no evidence of perinephric inflammation or effusion. There is no evidence of pyelectasia, nephroliths, infarcts or hydroureter. Renal vasculature is normal.

WEIGHT

6.1 kg

Adrenal Glands

The left adrenal gland is normal in size measuring 0.48 cm at the caudal pole. It is observed in its normal position cranial to the left renal artery. It is normal in appearance (uniformly hypoechoic) and shape with no evidence of a mass effect.

INTERPRETED BY

Kathleen Sennello DVM,
MS, Diplomate ACVIM
(Small Animal Internal
Medicine)

The right adrenal gland is normal in size measuring 0.58 cm at the caudal pole. It is observed in its normal position between the cranial aspect of the right kidney and the caudal vena cava. It is normal in appearance (uniformly hypoechoic) and shape with no evidence of a mass effect.

IMAGING PERFORMED BY

Kelly Reschny

Spleen

The spleen is subjectively normal in size, echotexture is homogenous, and the splenic capsule is smooth with no irregularities. The blood flow through the hilus and splenic parenchyma appears normal. No focal parenchymal abnormalities are visualized.

HOSPITAL NAME

Westoak Animal
Hospital

Liver

The liver is large in size, and normal in echogenicity with smooth peripheral margins. The parenchyma is heterogenous in echotexture with subtle, indistinct focal mottling. The visible portions of the vasculature and biliary tract appear normal. No focal nodules or cystic lesions are observed.

REFERRING VET

Dr. Kohlmaier

The gall bladder lumen is significantly distended. Some areas of the wall appear mildly thickened with adherent debris. There is a large amount of primarily non-organized echogenic debris, but there is some subtle organization and stranding of the debris, most consistent with an early mucocele formation. There is no evidence of bile duct dilation.

INVOICE

37280

DATE

4/29/22



PATIENT *Gastrointestinal*

Lily Gonzales The stomach contains a moderate amount of shadowing debris within the lumen. It measures at a normal thickness of <0.7cm with some variability due to the presence of rugal folds. The distinction of the gastric wall layers is adequate and there is no impression of reduced peristaltic activity. No masses or focal lesions were observed.

SPECIES

Canine The visualized areas of duodenum, jejunum and ileum have a relatively uniform diameter with minimal fluid distension. Wall thickness is normal. Bowel loops follow a curvilinear path with distinct wall layering maintaining the typical 1:3 muscularis:mucosa layer ratio. The duodenum measured as normal (between 0.3-0.5cm in wall thickness) and the jejunum measured as normal (between 0.2-0.47cm.)

BREED

Shih Poo Visualized peristalsis appears appropriate. There were no focal lesions consistent with obstruction or a mass effect observed.

SEX

Spayed Female The ileocecal junction was visualized and exhibited normal intact wall layering and is subjectively of normal thickness. Sections of colon are visualized with formed fecal material and gas shadowing distally. There is no observed focal or generalized colon wall thickening or loss of layering.

AGE

11 Years The pancreas is normal and isoechoic to surrounding mesentery. There is no evidence of nodules or cystic lesions. There is no evidence of regional mesenteric inflammation or fluid.

Pancreas

WEIGHT

6.1 kg Evaluation of the peritoneal cavity did not reveal any evidence of effusion, or subjective lymphadenomegaly. The Medial iliac nodes appear normal and there was no evidence of a caudal aortic thrombus at the bifurcation. The omentum is of normal uniform echogenicity.

Free Abdomen

INTERPRETED BY

Kathleen Sennello DVM,
MS, Diplomate ACVIM
(Small Animal Internal
Medicine)

ULTRASONOGRAPHIC FINDINGS

- Hyperechoic, dependent shadowing debris within the urinary bladder – most consistent with mineralized sandy debris or small stones. Recommend urinalysis and culture.
- Decreased corticomedullary distinction in both kidneys with small cortical cysts – The bilateral renal findings are consistent with age-related change.
- Large, heterogeneous liver – The diffuse hepatic changes are non-specific and can be seen with vacuolar hepatopathy, reactive change, nodular hyperplasia or, less likely, inflammatory/immune-mediated disease, infiltrative neoplasia, or other hepatopathy.
- Large amount of gallbladder debris with early mucosal stranding and organization – most consistent with early mucocele development. Recommend Ursodiol and continued monitoring.

IMAGING PERFORMED BY

Kelly Reschny

HOSPITAL NAME

Westoak Animal
Hospital

REFERRING VET

Dr. Kohlmaier

INTERPRETATION OF THE FINDINGS & FURTHER RECOMMENDATIONS

No focal lesions are observed in the liver to explain the elevation in ALP reported. The gallbladder does have a large volume of debris that is starting to organize and attach to the gallbladder wall. This is most consistent with an early mucocele. Consider starting Ursodiol and continued monitoring, as this could develop into a surgical lesion.

INVOICE

37280

DATE

4/29/22

- Recommend starting Ursodiol and continued monitoring of the gallbladder.
- Consider a fine needle aspirate of the liver if coagulation parameters permit this, as this can help to rule out a more serious cause for hepatopathy such as round cell neoplasia, hepatitis,



PATIENT

etc.

Lily Gonzales

- If signs of Cushing's are present, you could consider adrenal function testing.

SPECIES

Canine

- If liver values continue to rise, you could consider liver function testing, and liver biopsy if liver function is abnormal.

BREED

Shih Poo

SEX

Spayed Female

AGE

11 Years

WEIGHT

6.1 kg

INTERPRETED BY

Kathleen Sennello DVM,
MS, Diplomate ACVIM
(Small Animal Internal
Medicine)

**IMAGING
PERFORMED BY**

Kelly Reschny

HOSPITAL NAME

Westoak Animal
Hospital

REFERRING VET

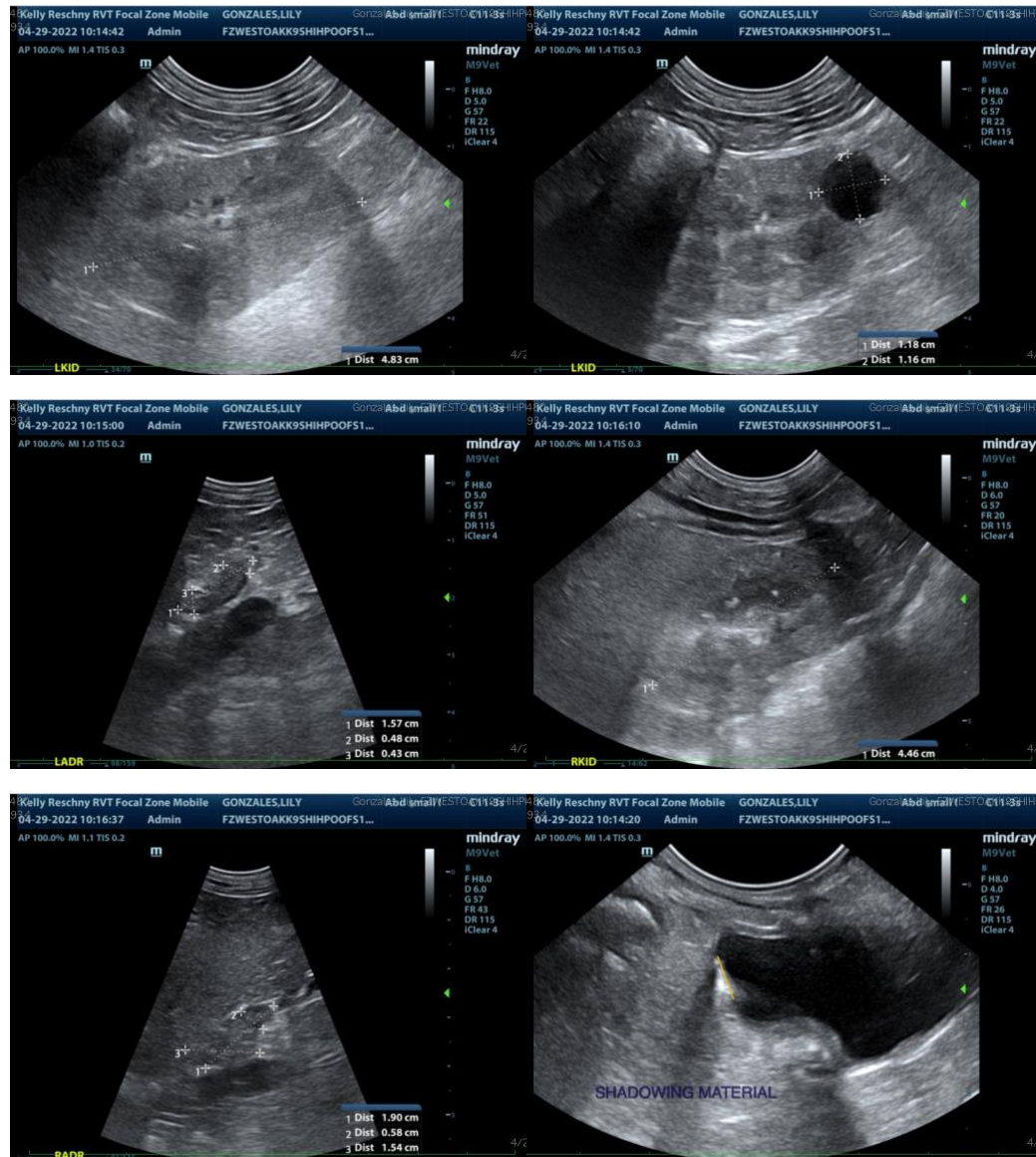
Dr. Kohlmaier

INVOICE

37280

DATE

4/29/22





PATIENT

Lily Gonzales

SPECIES

Canine

BREED

Shih Poo

SEX

Spayed Female

AGE

11 Years

WEIGHT

6.1 kg

INTERPRETED BY

Kathleen Sennello DVM,
MS, Diplomate ACVIM
(Small Animal Internal
Medicine)

**IMAGING
PERFORMED BY**

Kelly Reschny

HOSPITAL NAME

Westoak Animal
Hospital

REFERRING VET

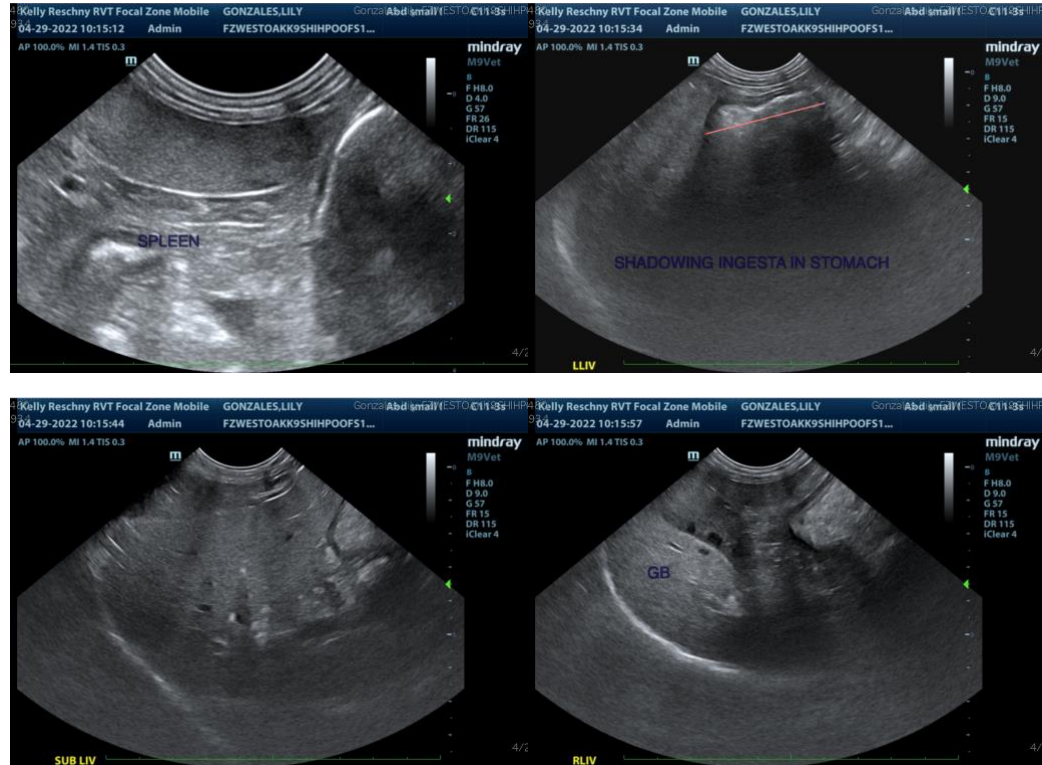
Dr. Kohlmaier

INVOICE

37280

DATE

4/29/22



The information and recommendations provided are based on the images presented by the referring veterinarian/sonographer. No evaluation can be communicated regarding pathology that was not visible in the image/video clips provided.

Thank you for this referral. If the clinical or image interpretation does not parallel your findings or if I can be of any further assistance please contact me.

Kathleen Sennello DVM,MS, Diplomate ACVIM (Small animal Internal Medicine)

kathleen.sennello@sonopath.com