

**DATE PRESENTING CLINICAL SIGNS**

4/29/22

Chronic mild liver value elevations; recent elevation in GGT. No clinical signs. H/O seizures- currently on Phenobarbital/Keppra, h/o elevated bile acids - suspect secondary to Pb -- decreased dosage by 50% and bile acids improved. h/o nephrolith and single bladder calculi, h/o heart murmur- managed by CVCA. no current medications, h/o hypothyroidism- currently on supplementation.

PATIENT

Dexter Ruff

SPECIES

Canine

BREED

Jack Russell

Current Medications: Thyroid 0.1mg tab: 1.5 tab PO BID, Phenobarbital 16.2mg tab: 1 tab PO BID, Levetiracetam 750mg -- extended release PO BID, Denamarin small/med dog: 1/2 tab PO SID, Gabapentin 50mg tab: 1 tab PO BID, Welactin

Lab Results: See attached.

Date of Previous IntraPet Ultrasound: 12/30/20. See attached.

Sedation: Not required to complete full diagnostic ultrasound.

Stat Report: Not requested.

ULTRASONOGRAPHIC EXAMINATION OF THE ABDOMEN**SEX**

Neutered Male

Urinary System

The urinary bladder is moderately distended with mildly echogenic urine. The Bladder wall, trigone, ureteral papillae and visible urethra (to a depth of 2cm) appear normal with no evidence of wall thickening, mucosal irregularities, or masses. There is a small, pinpoint hyperechoic mineralization visualized in the prostatic urethra, but it is mobile, and on additional views, was evident within the neck of the urinary bladder measuring at 0.20 cm.

AGE

8/31/06

WEIGHT

17 Pounds

The prostate is normal in size (0.89 cm) and shape for this neutered male dog. The parenchyma is homogenous and the external margins are smooth. The prostatic urethra appears normal with no evidence of irregularity, invasion, mass effect or calculi.

INTERPRETED BY

Kathleen Sennello DVM,
MS, Diplomate ACVIM
(Small Animal Internal
Medicine)

The left kidney has a normal shape and size (4.75 cm) with pinpoint non-obstructive nephroliths and slightly larger stone near the renal pelvis measuring 0.39 cm. Overall echogenicity is slightly hyperechoic with mildly reduced corticomedullary distinction and a typical 1:3 cortex:medulla ratio. There is no evidence of perinephric inflammation or effusion. There is no evidence of pyelectasia, infarcts or hydroureter. Renal vasculature is normal.

IMAGING PERFORMED BY

Andi Parkinson RDMS

The right kidney has a normal shape and size (4.6 cm) with pinpoint non-obstructive nephroliths. Overall echogenicity is slightly hyperechoic with mildly reduced corticomedullary distinction and a typical 1:3 cortex:medulla ratio. There is no evidence of perinephric inflammation or effusion. There is no evidence of pyelectasia, infarcts or hydroureter. Renal vasculature is normal.

HOSPITAL NAME

Timonium AH

Adrenal Glands

The left adrenal gland is normal in size measuring 0.87 cm at the caudal pole. It is observed in its normal position cranial to the left renal artery. It is normal in appearance (uniformly hypoechoic) and shape with no evidence of a mass effect.

REFERRING VET

Dr. McMichael

The right adrenal gland is normal in size measuring 0.68 cm at the caudal pole. It is observed in its normal position between the cranial aspect of the right kidney and the caudal vena cava. It is normal in appearance (uniformly hypoechoic) and shape with no evidence of a mass effect.

INVOICE

37305

Spleen

The spleen is subjectively normal in size, echotexture is homogenous, and the splenic capsule is smooth with no irregularities. The blood flow through the hilus and splenic parenchyma appears normal. No focal parenchymal abnormalities are visualized.

Liver

The liver is large in size, and normal in echogenicity with smooth peripheral margins. The parenchyma is heterogenous in echotexture with subtle, indistinct focal mottling. The visible portions of the vasculature and biliary tract appear normal. No focal nodules or cystic lesions are observed.

The gallbladder lumen is moderately distended. The wall of the gall bladder is not thickened and has a smooth mucosal surface. Luminal contents are primarily anechoic. The cystic and common bile ducts are normal/not visible.

Gastrointestinal

The stomach contains minimal luminal contents. It measures at a normal thickness of <0.7cm with some variability due to the presence of rugal folds. The distinction of the gastric wall layers is adequate and there is no impression of reduced peristaltic activity. No masses or focal lesions were observed.

The visualized areas of duodenum, jejunum and ileum have a relatively uniform diameter with minimal fluid distension. Wall thickness is normal. Bowel loops follow a curvilinear path with distinct wall layering maintaining the typical 1:3 muscularis:mucosa layer ratio. Duodenum wall measured 0.40 cm. Jejunum wall measured 0.32 cm. Visualized peristalsis appears appropriate. There were no focal lesions consistent with obstruction or a mass effect observed.

The ileocecal junction was visualized and exhibited normal intact wall layering and is subjectively of normal thickness. Sections of colon are visualized with formed fecal material and gas shadowing distally. There is no observed focal or generalized colon wall thickening or loss of layering.

Pancreas

The pancreas is normal and isoechoic to surrounding mesentery. There is no evidence of nodules or cystic lesions. There is no evidence of regional mesenteric inflammation or fluid.

Free Abdomen

Evaluation of the peritoneal cavity did not reveal any evidence of effusion, or subjective lymphadenomegaly. The Medial iliac nodes appear normal and there was no evidence of a caudal aortic thrombus at the bifurcation. The omentum is of normal uniform echogenicity.

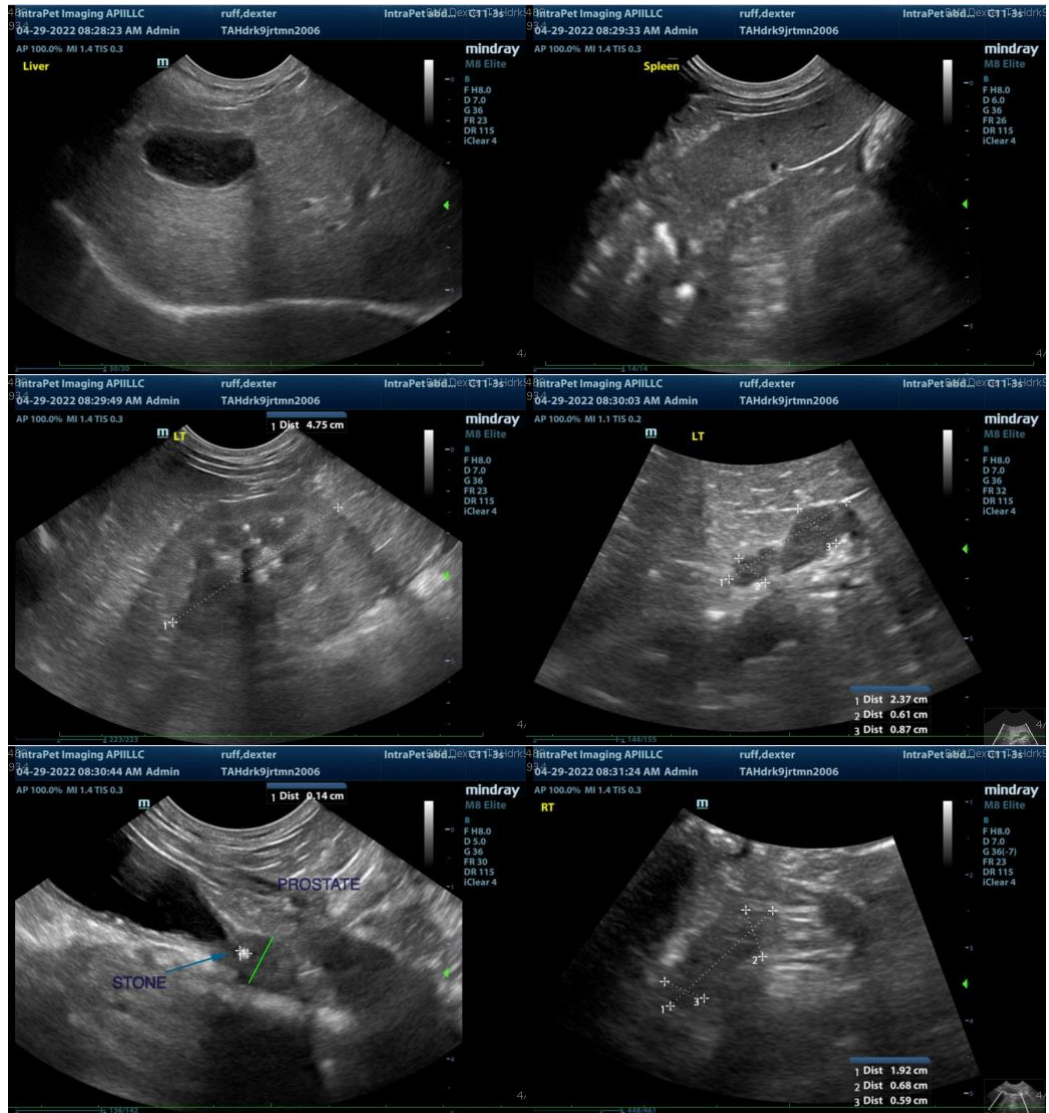
ULTRASONOGRAPHIC FINDINGS

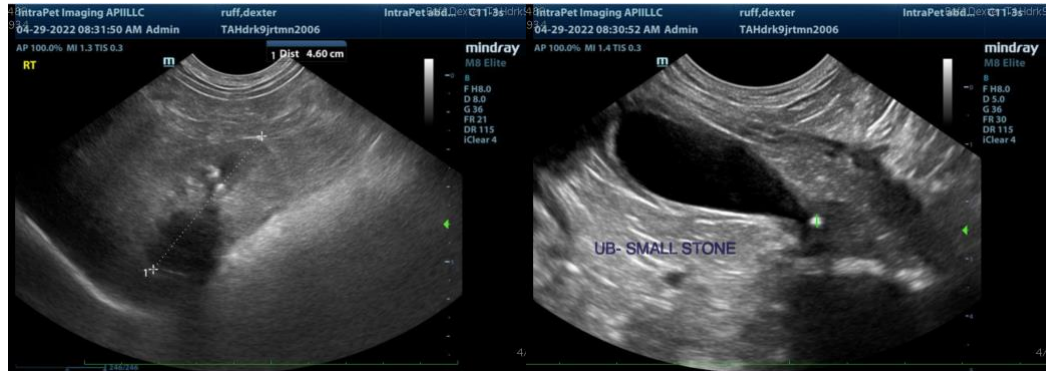
- Small pinpoint nephrolith visualized within the urinary bladder and prostatic urethra (mobile)
- Decreased corticomedullary distinction in both kidneys with pinpoint non-obstructive nephroliths and a small left-sided pelvic nephrolith – these changes are likely age related and are relatively similar to those visualized in the previous scan.
- Large, heterogeneous liver – The diffuse hepatic changes are non-specific and could be consistent with vacuolar hepatopathy, nodular hyperplasia, inflammatory/immune-mediated disease, fibrosis, extramedullary hematopoiesis, toxic hepatopathy (e.g., copper), infiltrative neoplasia (less likely) or other hepatopathy. These changes are possibly due to chronic Phenobarbital use.

INTERPRETATION OF THE FINDINGS & FURTHER RECOMMENDATIONS

The small bladder stones and nephroliths reported in the previous scan in 2020 appear relatively stable. There is no sign of an obstructive process, although the bladder stone is mobile and moving into the prostatic urethra on occasion. Continued monitoring is warranted, though I suspect attempts at dissolving this stone have not been successful.

The changes observed in the liver are likely secondary to the chronic Phenobarbital therapy, although something like concurrent Cushing's disease cannot be ruled out. Ideally, Phenobarbital therapy would be discontinued or replaced with another anti-seizure medication, but if liver function testing is normal, I can understand not wanting to take the risk of changing anti-seizure therapy.





The information and recommendations provided are based on the images presented by the referring veterinarian/sonographer. No evaluation can be communicated regarding pathology that was not visible in the image/video clips provided.

Thank you for this referral. If the clinical or image interpretation does not parallel your findings or if I can be of any further assistance please contact me.

Kathleen Sennello DVM,MS, Diplomate ACVIM (Small animal Internal Medicine)
kathleen.sennello@sonopath.com