

**DATE PRESENTING CLINICAL SIGNS**

4.28.2023 PU/PD as of last few months. Screening BW showed mild BUN elevation and elevated liver enzymes. Did low dose dex but came back inconclusive. Pet has pot belly on exam and grade 3/6 systolic murmur.

**PATIENT**

Jinx Kovacic Current Medications: None.  
 Lab Results: 3/24/23- BUN 34, alt 194, alp 1769, chol 366, lipase 2077, CBC unremarkable  
 UA - usg 1.034, prot 500 blood 10, some non-hyaline casts, otherwise quiet sediment

**SPECIES**

Canine

**BREED**

Maltese Mix

**SEX**

Neutered Male

**AGE**

4/20/2013

**WEIGHT**

12.7 lbs

**INTERPRETED BY**

Kathleen Sennello  
 DVM, MS, Diplomate  
 ACVIM (Small Animal  
 Internal Medicine)

**HOSPITAL NAME**

Greenbrier VC

**REFERRING VET**

Boccanfuso

**INVOICE**

12901

**PRESENTING CLINICAL SIGNS**

PU/PD as of last few months. Screening BW showed mild BUN elevation and elevated liver enzymes. Did low dose dex but came back inconclusive. Pet has pot belly on exam and grade 3/6 systolic murmur.

Current Medications: None.

Lab Results: 3/24/23- BUN 34, alt 194, alp 1769, chol 366, lipase 2077, CBC unremarkable  
 UA - usg 1.034, prot 500 blood 10, some non-hyaline casts, otherwise quiet sediment

Low Dose Dex - inconclusive

Date of Previous IntraPet Ultrasound: No previous.

Sedation: Not required to complete full diagnostic ultrasound.

Stat Report: Not requested.

Imaging Performed By: Rachel Brillhart, RDMS.

**ULTRASONOGRAPHIC EXAMINATION OF THE ABDOMEN****Urinary System**

The urinary bladder is mildly distended with anechoic urine. The Bladder wall is diffusely mildly thickened (0.26 cm) and the mucosa is mildly irregular. The trigone, ureteral papillae, and visible urethra (to a depth of 2cm) appear normal with no evidence of severe mucosal irregularities, masses or cystic calculi. Findings are most consistent with bacterial cystitis or lack of urine distension. Recommend urinalysis and culture

The left kidney has a normal shape and size (4.16 cm). Overall echogenicity is normal with decreased corticomedullary distinction and a typical 1:3 cortex:medulla ratio. There is no evidence of perinephric inflammation or effusion. There is no evidence of pyelectasia, nephroliths, infarcts or hydroureter. Renal vasculature is normal.

The right kidney has a normal shape and size (3.73 cm). Overall echogenicity is normal with decreased corticomedullary distinction and a typical 1:3 cortex:medulla ratio. There is no evidence of perinephric inflammation or effusion. There is no evidence of pyelectasia, nephroliths, infarcts or hydroureter. Renal vasculature is normal.

**Adrenal Glands**

The left adrenal gland is plump and hypoechoic, measuring 0.60 cm at the caudal pole. It is observed in its normal position cranial to the left renal artery. It is normal in appearance (uniformly hypoechoic) and shape with no evidence of a mass effect.

The right adrenal gland is borderline plump and hypoechoic, measuring 0.56 cm at the caudal pole. It is observed in its normal position between the cranial aspect of the right kidney and the caudal vena cava. It is normal in appearance (uniformly hypoechoic) and shape with no evidence of a mass effect.

**Spleen**

The spleen is subjectively normal in size, echotexture is homogenous, and the splenic capsule is smooth with no irregularities. The blood flow through the hilus and splenic parenchyma appears normal. No focal parenchymal abnormalities are visualized.

**Liver**

The liver is large, heterogenous and mildly hyperechoic. The parenchyma is homogenous echotexture. The visible portions of the vasculature and biliary tract appear normal. No focal nodules or cystic lesions are observed.

The gall bladder lumen is moderately distended. The wall of the gall bladder is not thickened and has a smooth mucosal surface. There is a moderate amount of non-organized echogenic debris. The cystic and common bile ducts are normal/not visible.

### ***Gastrointestinal***

The stomach contains minimal luminal contents. It measures at a normal thickness of <0.7cm with some variability due to the presence of rugal folds. The distinction of the gastric wall layers is adequate and there is no impression of reduced peristaltic activity. No masses or focal lesions were observed.

The visualized areas of duodenum, jejunum and ileum have a relatively uniform diameter with minimal fluid distension. Wall thickness is normal. Bowel loops follow a curvilinear path with distinct wall layering maintaining the typical 1:3 muscularis:mucosa layer ratio. The duodenum measured as normal (0.45 cm) and the jejunum measured as normal (0.24 cm). Visualized peristalsis appears appropriate. There were no focal lesions consistent with obstruction or a mass effect observed.

The ileocecal junction was visualized and exhibited normal intact wall layering and is subjectively of normal thickness. Sections of colon are visualized with formed fecal material and gas shadowing distally. There is no observed focal or generalized colon wall thickening or loss of layering.

### ***Pancreas***

The pancreas is prominent and mottled. There is no evidence of nodules or cystic lesions. There is no evidence of regional mesenteric inflammation or fluid.

### ***Free Abdomen***

Evaluation of the peritoneal cavity did not reveal any evidence of effusion, or subjective lymphadenomegaly. The Medial iliac nodes appear normal and there was no evidence of a caudal aortic thrombus at the bifurcation. The omentum is of normal uniform echogenicity.

## **ULTRASONOGRAPHIC FINDINGS**

### **Primary Findings**

- “Plump” hypoechoic adrenals - The bilateral adrenomegaly could be consistent with bilateral hyperplasia (e.g., secondary to pituitary-dependent hyperadrenocorticism), bilateral infiltrative neoplasia, inflammatory adrenal disease, other. Correlation with clinical findings is recommended.
- Large heterogenous, mildly hyperechoic liver - The diffuse hepatic changes are non-specific and could be consistent with vacuolar hepatopathy, nodular hyperplasia, inflammatory/immune-mediated disease, fibrosis, extramedullary hematopoiesis, toxic hepatopathy (e.g., copper), infiltrative neoplasia (less likely) or other hepatopathy. This is likely consistent with a vacuolar hepatopathy.

### **Secondary Findings**

- Mildly thickened urinary bladder wall – This could be within normal limits for this individual. Consider a urinalysis and culture, looking for possible cystitis.
- Decreased corticomedullary distinction in both kidneys - The bilateral renal findings are consistent with age-related change.
- Prominent mottled pancreas - The pancreatic changes are most consistent with age-related

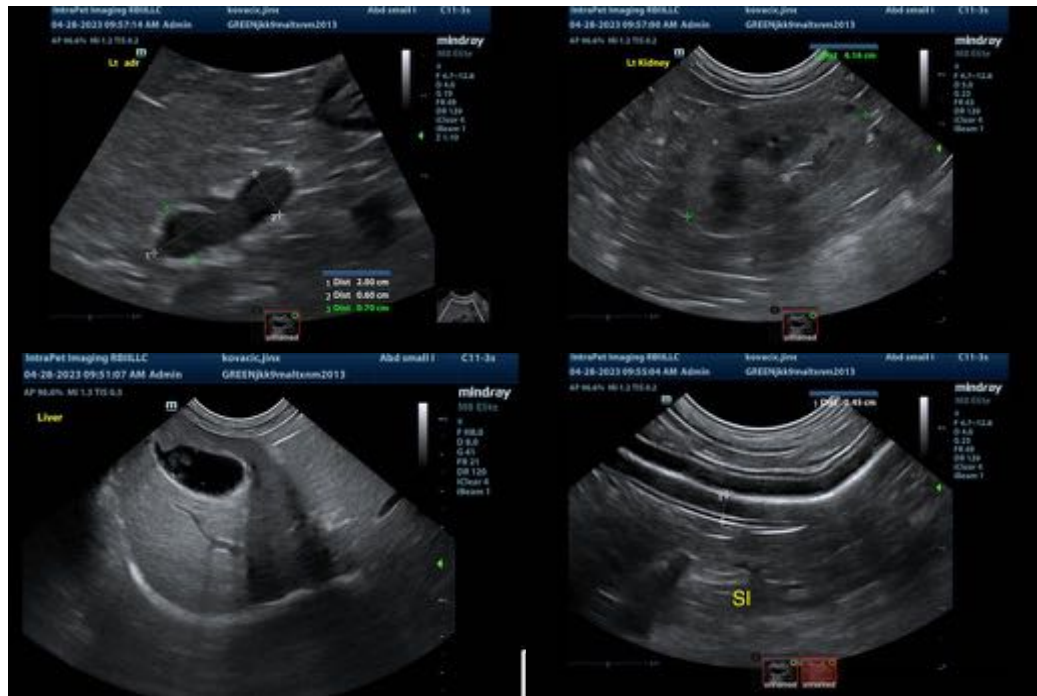parenchymal remodeling, potentially secondary to a prior inflammatory episode, early fibrosis or chronic pancreatitis.

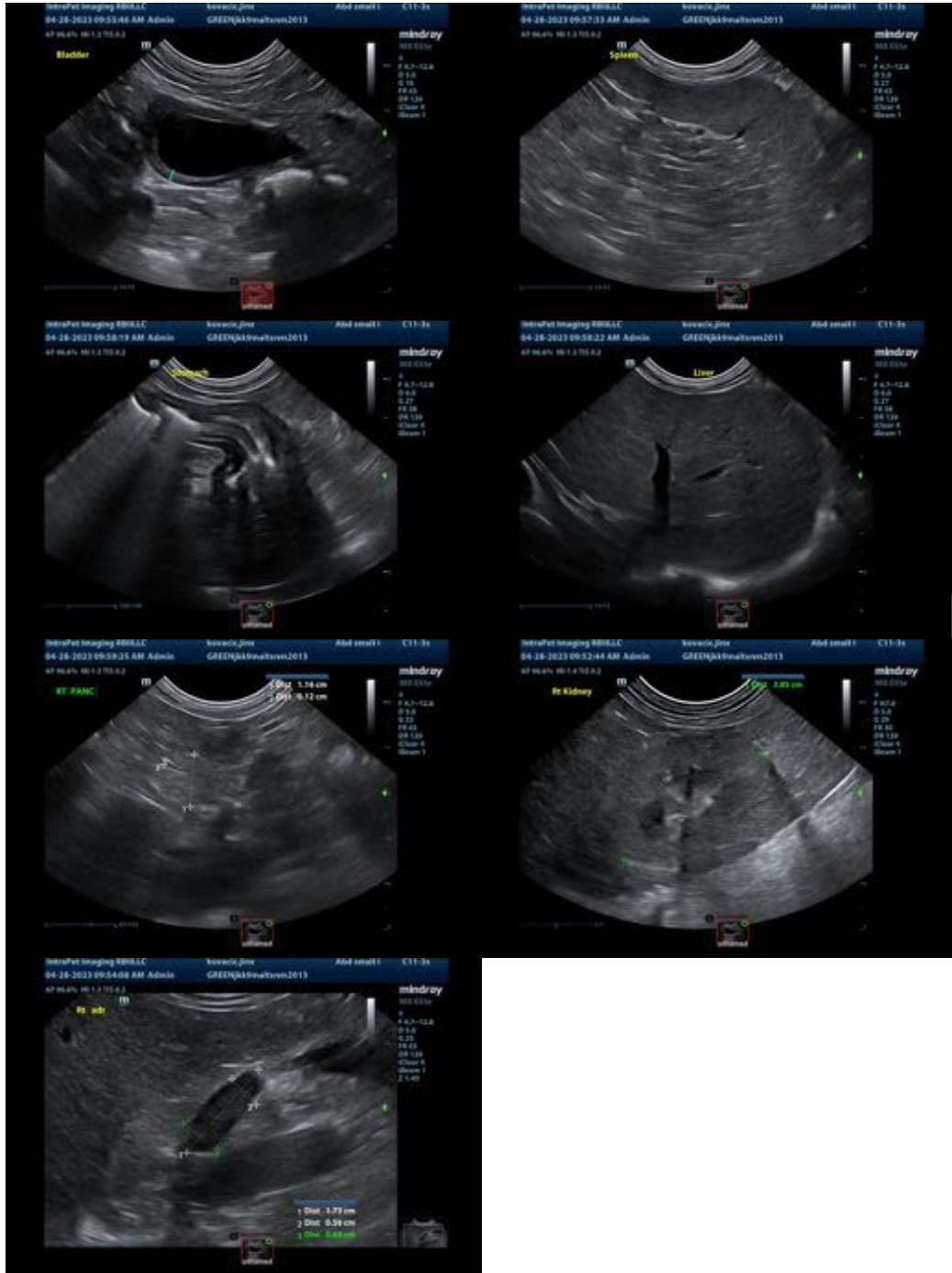
- Mild gall bladder debris - The significance of the aggregated gallbladder debris is unclear. This could represent an early mucocele, cholestasis, or may be secondary to fasting but seems unlikely to be causing a current issue. Recommend continued monitoring.

### INTERPRETATION OF THE FINDINGS & FURTHER RECOMMENDATIONS

The liver is large, rounded and somewhat hyperechoic. These are nonspecific findings, but no focal lesions are obstruction. This could certainly be consistent with a vacuolar hepatopathy. Additionally, the changes in the gall bladder are minimal.

The adrenals do not measure definitively as enlarged, but they are prominent and hypoechoic, and I would suspect large for this individual. These changes combined with the clinical signs described are highly suspicious for pituitary-dependent Cushing's Disease. If suspicion is very high and the owner would like to treat, I generally would recommend performing an ACTH stimulation test, so you have cortisol level to follow with treatment. Alternately, you could consider continued monitoring and evaluation in the future, as this could progress. Consider a urinalysis culture and blood pressure evaluation due to the renal changes observed and the concern for underlying hyperadrenocorticism.





The information and recommendations provided are based on the images presented by the referring veterinarian. No evaluation can be communicated regarding pathology that was not visible in the image/video clips provided.

Thank you for this referral. If the clinical or image interpretation does not parallel your findings or if I can be of any further assistance, please contact me.

Kathleen Sennello DVM, MS, Diplomate ACVIM (Small animal Internal Medicine)  
kathleen.sennello@sonopath.com