**DATE PRESENTING CLINICAL SIGNS**

4.28.2023

Owner reports that cat has been exhibiting a consistent issue with blood in the stool over the past few weeks associated with diarrhea. Over the past 4-5 days, cat has shown anorexia, vomiting and straining to pass stool with only a small amount of stool (semi-formed) being passed. Colt was under treatment with a maintenance dose of prednisolone 5.0 mg EOD for suspected IBD.

PATIENT

Colt Schwemmer

Current Medications: Prednisolone 5.0 mg - 1 1/2 tablet QD (change in dosage since the start of the clinical signs). Cerenia 24 mg - 1/2 tablet QD, Vitamin B12 injection Q 30 days. Recently completed a course of Flagyl 50 mg BID with little improvement in his clinical signs.

SPECIES

Feline

Lab Results: CBC/Chem 17 on 4/24/23: All values WNL.

BREED

DSH

Radiographs: No evidence of an obstructive pattern or constipation associated with the GI tract. Minimum amount of food/ingesta within the GI tract. No abdominal effusion and other organs have a generally normal appearance. Left kidney may be slightly enlarged.

SEX

Neutered Male

Date of Previous IntraPet Ultrasound: 1/2/23. See attached.

Sedation: Not required to complete full diagnostic ultrasound.

Stat Report: Not requested.

Imaging Performed By: Stephanie Warga RDCS, RVT.

ULTRASONOGRAPHIC EXAMINATION OF THE ABDOMEN**AGE**

4/3/2010

Urinary System

The urinary bladder is moderately distended with anechoic urine. The Bladder wall, trigone, ureteral papillae and visible urethra (to a depth of 2cm) appear normal with no evidence of wall thickening, mucosal irregularities, masses or cystic calculi.

WEIGHT

10 lbs

The left kidney has a normal shape and size (4.12 cm). Overall echogenicity is normal with decreased corticomedullary distinction and a typical 1:3 cortex:medulla ratio. There is no evidence of perinephric inflammation or effusion. Mild pyelectasia is present. There is no evidence of nephroliths, infarcts or hydroureter. Renal vasculature is normal.

INTERPRETED BY

Kathleen Sennello
DVM, MS, Diplomate
ACVIM (Small Animal
Internal Medicine)

The right kidney has a normal shape and size (3.15 cm). Overall echogenicity is normal with decreased corticomedullary distinction and a typical 1:3 cortex:medulla ratio. There is no evidence of perinephric inflammation or effusion. There is no evidence of pyelectasia, nephroliths, infarcts or hydroureter. Renal vasculature is normal.

HOSPITAL NAME

Fork VH

Adrenal Glands

The left adrenal gland is normal in size measuring 0.35 cm at the caudal pole. It is observed in its normal position cranial to the left renal artery. It is normal in appearance (uniformly hypoechoic) and shape with no evidence of a mass effect.

REFERRING VET

Dr. Doherty

The right adrenal gland is normal in size measuring 0.34 cm at the caudal pole. It is observed in its normal position between the cranial aspect of the right kidney and the caudal vena cava. It is normal in appearance (uniformly hypoechoic) and shape with no evidence of a mass effect.

INVOICE

12900

Spleen

The spleen is subjectively normal in size (0.62 cm) echotexture is homogenous, and the splenic capsule is smooth with no irregularities. The blood flow through the hilus and splenic parenchyma appears normal. No focal parenchymal abnormalities are visualized.

Liver

The liver is subjectively normal in size, and echogenicity with smooth peripheral margins. The parenchyma is homogenous echotexture. The visible portions of the vasculature and biliary tract appear normal. There is a

hyperechoic, somewhat “moth-eaten”/cystic-appearing mass/lesion visualized within the hepatic parenchyma (3.90 x 2.06 cm). Additionally, there are other hyperechoic nodules visualized (the largest of which measures at 1.34 x 1.10 cm). These lesions appear stable from the previous ultrasound (1/2/2023).

The gall bladder lumen is moderately distended. The wall of the gall bladder is not thickened and has a smooth mucosal surface. Luminal contents are primarily anechoic. The cystic and common bile ducts are normal/not visible.

Gastrointestinal

The stomach contains moderate fluid/ingesta. It measures at a normal thickness of <0.36cm with some variability due to the presence of rugal folds. The distinction of the gastric wall layers is adequate and there is no impression of reduced peristaltic activity. No masses or focal lesions were observed.

The visualized areas of duodenum, jejunum and ileum have a uniform diameter with minimal fluid distension. Wall thickness is normal to slightly increased. Bowel loops follow a typical curvilinear path with distinct wall layering, but some areas display a prominent muscularis layer which does not display the typical 1:3 muscularis:mucosa layer ratio. The jejunum measured 0.23 mm in diameter. Visualized peristalsis appears appropriate. There were no focal lesions consistent with obstruction or a mass effect observed.

The area of the ileocecal junction was visualized. The colon in this region appears of normal thickness normal wall layering. Distally at the level of the urinary bladder, there is focal thickening and irregularity of the colonic wall with loss of layering. In this area, the colonic wall measures at 0.57 cm, and is surrounded by hyperechoic mesentery and an enlarged lymph node.

Pancreas

The pancreas is large and hypoechoic to surrounding mesentery. There is no evidence of nodules or cystic lesions. There is evidence of regional mesenteric inflammation. Consistent with mild pancreatitis.

Free Abdomen

There is no free fluid. There is a large, irregular, hypoechoic lymph node visualized adjacent to the colon (0.74 x 0.69 cm). The omentum is hyperechoic around the thickened colon.

ULTRASONOGRAPHIC FINDINGS

Findings

- Decreased corticomedullary distinction in both kidneys with mild left-sided pyelectasia - Mild loss of corticomedullary distinction in both kidneys could be consistent with chronic degenerative disease or interstitial nephrosis.
- Hypoechoic prominent left and right limb of the pancreas - The appearance is stable from the previous scan and could represent mild active pancreatitis, or a previous/resolving episode of pancreatitis. Correlate with PLI levels.
- Hyperechoic “moth-eaten”/cystic mass/lesion and numerous hyperechoic lesions visualized within the liver - These have an appearance most consistent with benign lesions and appear stable from the previous scan. Recommend continued monitoring.
- Moderate fluid/ingesta within the gastric lumen - Correlate with the feeding history, if the patient was adequately fasted. Consider the possibility of delayed gastric emptying or a partial outflow tract obstruction (none observed).
- Prominent muscularis layer of the small intestine - The small intestinal wall changes are most

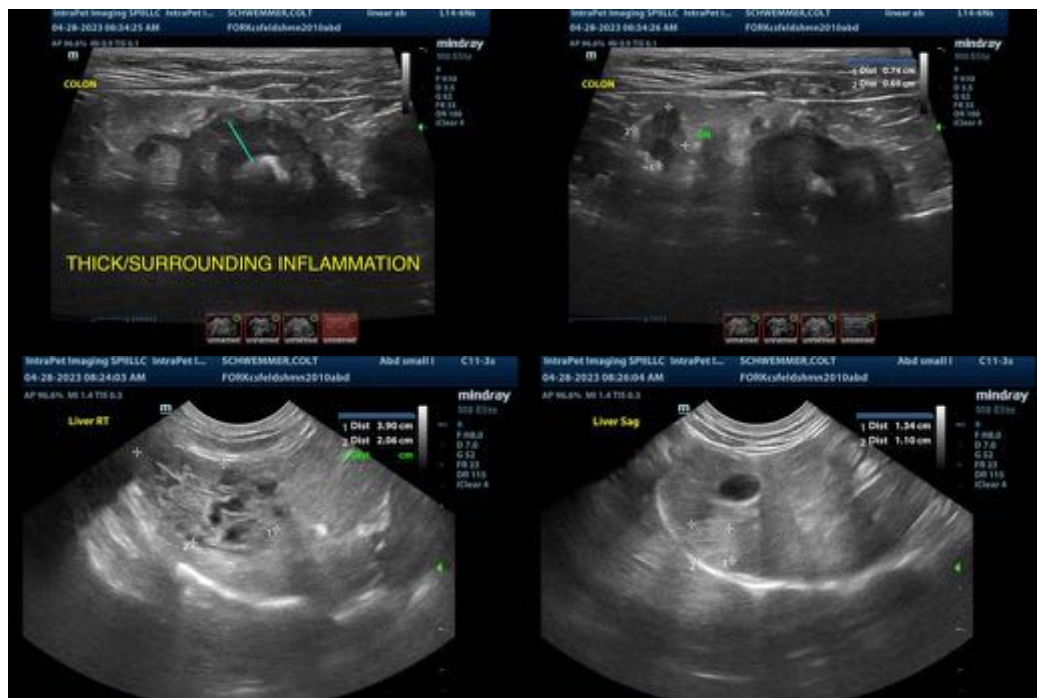
consistent with an inflammatory process (i.e., inflammatory bowel disease) with a low possibility of emerging lymphoma

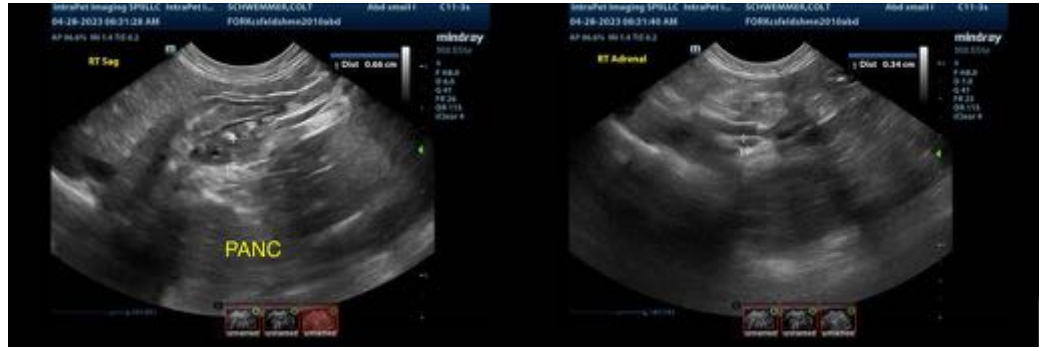
- Focal thickening with loss of layering in the distal colon - This could represent a severe inflammatory lesion or infiltrative neoplasia. Concern for an underlying neoplastic is high (round cell neoplasia, carcinoma, etc.).
- Large lymph node visualized adjacent to the thickened colon - This is concerning for a reactive or possibly metastatic lymph node.

INTERPRETATION OF THE FINDINGS & FURTHER RECOMMENDATIONS

The changes previously described in the kidneys, liver, pancreas and small bowel appear relatively stable. The changes in the small bowel are concerning for primary enteropathy. On today's exam, the distal colon appears significantly thickened and irregular with decreased detail of wall layering and a surrounding inflammation/lymphadenopathy. These changes are concerning for infiltrative disease, but focal severe colitis is possible. Consider a fine-needle aspirate of the colonic wall in this region, +/- the lymph node (if possible). If a cytology diagnosis cannot be obtained, consider upper and lower GI endoscopy to try and obtain endoscopic biopsies of the colon and small bowel.

Recommend three view thoracic radiographs to evaluate for possible concurrent thoracic disease/involvement.





The information and recommendations provided are based on the images presented by the referring veterinarian. No evaluation can be communicated regarding pathology that was not visible in the image/video clips provided.

Thank you for this referral. If the clinical or image interpretation does not parallel your findings or if I can be of any further assistance, please contact me.

Kathleen Sennello DVM, MS, Diplomate ACVIM (Small animal Internal Medicine)
kathleen.sennello@sonopath.com