



**PATIENT PRESENTING CLINICAL SIGNS**

**PATIENT**  
Puck Fine

**SPECIES**  
Canine

Had an U/S & GI panel in 2/21 due to long hx of vomiting and diarrhea, U/S consistent with IBD + pancreatitis, and GI panel had very low cobalamin and high PLI. Treated with low fat diet, gabapentin and cobalamin and signs all resolved until a few weeks ago. CBC / Chem revealed ALT 478, ALP 549 (both previously normal) else unremarkable. GI panel was normal. U/A pending. Patient was started on cerenia and metronidazole and signs have mostly resolved.

**ULTRASONOGRAPHIC EXAMINATION OF THE ABDOMEN**

**Urinary System**

**BREED**

Yorkie

The urinary bladder is moderately distended with anechoic urine. The Bladder wall, trigone, ureteral papillae and visible urethra (to a depth of 2cm) appear normal with no evidence of wall thickening, mucosal irregularities, masses or cystic calculi.

**SEX**

Neutered Male

The prostate is normal in size (0.98 cm) and shape for this neutered male dog. The parenchyma is homogenous and the external margins are smooth. The prostatic urethra appears normal with no evidence of irregularity, invasion, mass effect or calculi.

**AGE**

12 Years

The left kidney has a normal shape and size (4.14 cm). Overall echogenicity is slightly hyperechoic with mildly reduced corticomedullary distinction and a typical 1:3 cortex:medulla ratio. There is no evidence of perinephric inflammation or effusion. There is no evidence of pyelectasia, nephroliths, infarcts or hydroureter. Renal vasculature is normal.

**WEIGHT**

10.2 Pounds

The right kidney has a normal shape and size (4.42 cm). Overall echogenicity is slightly hyperechoic with poor corticomedullary distinction and a typical 1:3 cortex:medulla ratio. There is no evidence of perinephric inflammation or effusion. There is no evidence of pyelectasia, nephroliths, infarcts or hydroureter. Renal vasculature is normal.

**INTERPRETED BY**

Kathleen Sennello DVM,  
MS, Diplomate ACVIM  
(Small Animal Internal  
Medicine)

**Adrenal Glands**

The left adrenal gland is normal in size measuring 0.49 cm at the caudal pole. It is observed in its normal position cranial to the left renal artery. It is normal in appearance (uniformly hypoechoic) and shape with no evidence of a mass effect.

**IMAGING PERFORMED BY**

Dr. Tam Mengine

The right adrenal gland is normal in size measuring 0.48 cm at the caudal pole. It is observed in its normal position between the cranial aspect of the right kidney and the caudal vena cava. It is normal in appearance (uniformly hypoechoic) and shape with no evidence of a mass effect.

**HOSPITAL NAME**

Stoney Creek VH

**Spleen**

The spleen is subjectively normal in size, echotexture is homogenous, and the splenic capsule is smooth with no irregularities. The blood flow through the hilus and splenic parenchyma appears normal. No focal parenchymal abnormalities are visualized.

**REFERRING VET**

Dr. Tam Mengine

**Liver**

The liver is subjectively normal in size, and slightly hyperechoic with smooth peripheral margins. The parenchyma is heterogenous in echotexture with subtle, indistinct focal mottling. The visible portions of the vasculature and biliary tract appear normal. No focal nodules or cystic lesions are observed.

**INVOICE**

37250

The gallbladder lumen is moderately distended. The wall of the gall bladder is not thickened and has a smooth mucosal surface. Luminal contents are primarily anechoic. The cystic and common bile ducts are normal/not visible.

**DATE**

4/28/22



**PATIENT**

***Gastrointestinal***

Puck Fine

The stomach contains minimal luminal contents. It measures at a normal thickness of <0.7cm with some variability due to the presence of rugal folds. The distinction of the gastric wall layers is adequate and there is no impression of reduced peristaltic activity. No masses or focal lesions were observed.

**SPECIES**

Canine

The visualized areas of duodenum, jejunum and ileum have a uniform diameter with minimal fluid distension. Wall thickness is increased. Bowel loops follow a typical curvilinear path. Some areas have reduced detail of wall layering. Duodenum wall measured 0.51 cm. Jejunum wall measured 0.35 cm.

**BREED**

Yorkie

Visualized peristalsis appears appropriate. Some areas of the small intestine, particularly the duodenum, have some mild corrugation and mucosal fogging evident.

**SEX**

Neutered Male

The ileocecal junction was visualized and exhibited normal intact wall layering and is subjectively of normal thickness. Sections of colon are visualized with formed fecal material and gas shadowing distally. There is no observed focal or generalized colon wall thickening or loss of layering. Colon wall measured 0.31 cm.

***Pancreas***

**AGE**

12 Years

The pancreas is normal and isoechoic to surrounding mesentery. There is no evidence of nodules or cystic lesions. There is no evidence of regional mesenteric inflammation or fluid.

***Free Abdomen***

**WEIGHT**

10.2 Pounds

Evaluation of the peritoneal cavity did not reveal any evidence of effusion, or subjective lymphadenomegaly. The Medial iliac nodes appear normal and there was no evidence of a caudal aortic thrombus at the bifurcation. The omentum is of normal uniform echogenicity.

**ULTRASONOGRAPHIC FINDINGS**

**INTERPRETED BY**

Kathleen Sennello DVM,  
MS, Diplomate ACVIM  
(Small Animal Internal  
Medicine)

- Thickened small intestine with corrugation and mucosal fogging – findings are most consistent with inflammatory or infectious disease, less likely neoplastic change.
- Decreased corticomedullary distinction in both kidneys – The bilateral renal findings are consistent with age-related change.
- Heterogeneous liver – The diffuse hepatic changes are non-specific and could be consistent with vacuolar hepatopathy, nodular hyperplasia, inflammatory/immune-mediated disease, fibrosis, extramedullary hematopoiesis, toxic hepatopathy (e.g., copper), infiltrative neoplasia (less likely) or other hepatopathy.

**IMAGING PERFORMED BY**

Dr. Tam Mengine

**HOSPITAL NAME**

Stoney Creek VH

**REFERRING VET**

Dr. Tam Mengine

**INTERPRETATION OF THE FINDINGS & FURTHER RECOMMENDATIONS**

No focal lesions are observed in the liver. The gallbladder and bile ducts appear relatively normal. These findings are most consistent with primary hepatopathy. These would be my recommendations to further evaluate this liver enzyme elevation:

**INVOICE**

37250

- Consider close evaluation of history for possible toxic changes examine medications, diet, dietary indiscretion etc...
- Consider PCR on urine/serum for leptospirosis (if not on antibiotics)/serology if recent antibiotic history
- If not already done, consider pre and post prandial bile acids to evaluate liver function

**DATE**

4/28/22



**PATIENT**

Puck Fine

- If the ALP is significantly elevated relative to the ALT and symptoms consistent with cushings are present, consider adrenal function testing (ACTH stim)

**SPECIES**

Canine

- Consider Fine needle aspirate if round cell neoplasia is on your differential list (25 g needle, normal coags)

**BREED**

Yorkie

Additionally, the small intestine appears generally thickened, and some areas have mild corrugation and some mucosal fogging. These findings are concerning for possible chronic GI disease. Depending on what the diagnosis is, this could be managed with diet, etc., but often continued long-term treatment is required. Recommend repeating GI panel to see where these values are, and if additional long-term cobalamin therapy is recommended, etc.

**SEX**

Neutered Male

If a liver biopsy is considered in the near future, I would recommend obtaining GI biopsies at the same time to obtain a diagnosis and achieve better long-term management of the suspected concurrent GI disease.

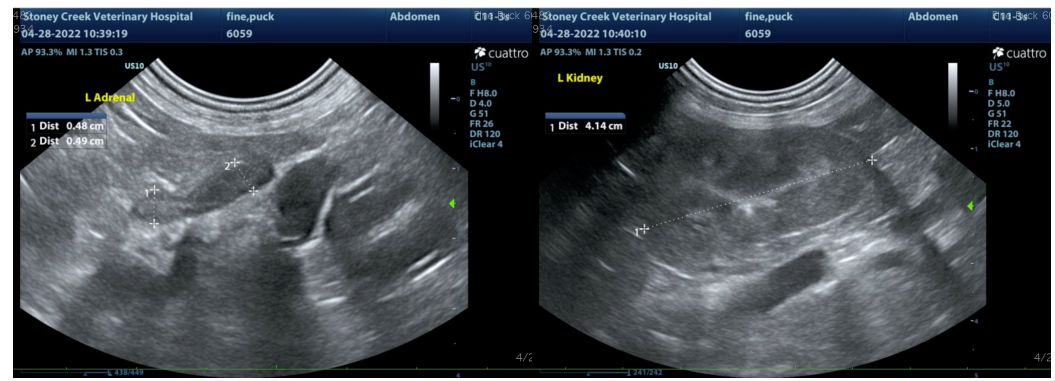
**AGE**

12 Years

Consider three view thoracic radiographs to rule out concurrent thoracic disease/involvement.

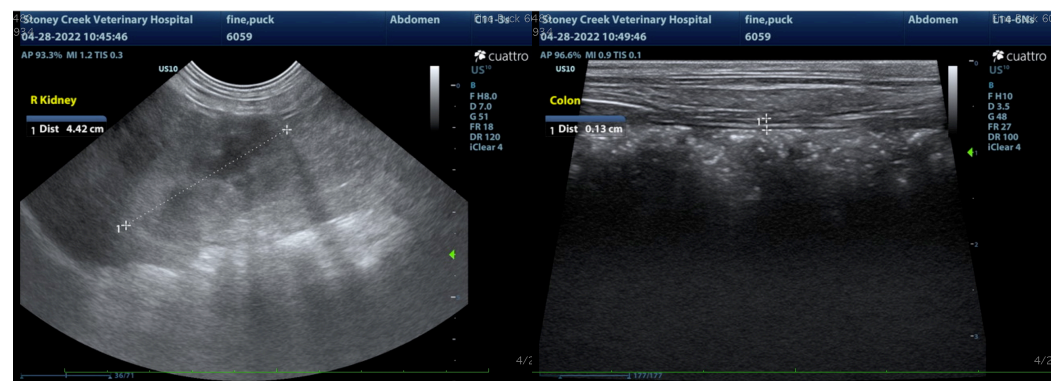
**WEIGHT**

10.2 Pounds



**INTERPRETED BY**

Kathleen Sennello DVM, MS, Diplomate ACVIM (Small Animal Internal Medicine)



**IMAGING PERFORMED BY**

Dr. Tam Mengine

**HOSPITAL NAME**

Stoney Creek VH

**REFERRING VET**

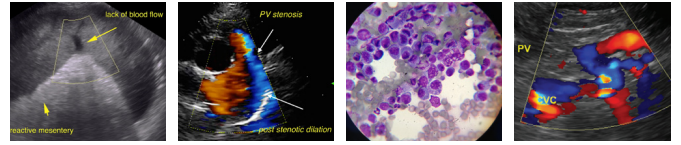
Dr. Tam Mengine

**INVOICE**

37250

**DATE**

4/28/22



**PATIENT**

Puck Fine

**SPECIES**

Canine

**BREED**

Yorkie

**SEX**

Neutered Male

**AGE**

12 Years

**WEIGHT**

10.2 Pounds

**INTERPRETED BY**

Kathleen Sennello DVM,  
MS, Diplomate ACVIM  
(Small Animal Internal  
Medicine)

**IMAGING  
PERFORMED BY**

Dr. Tam Mengine

**HOSPITAL NAME**

Stoney Creek VH

**REFERRING VET**

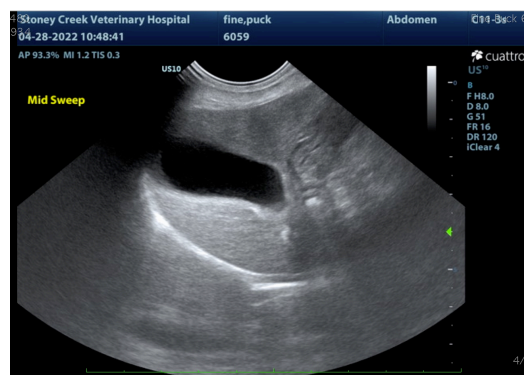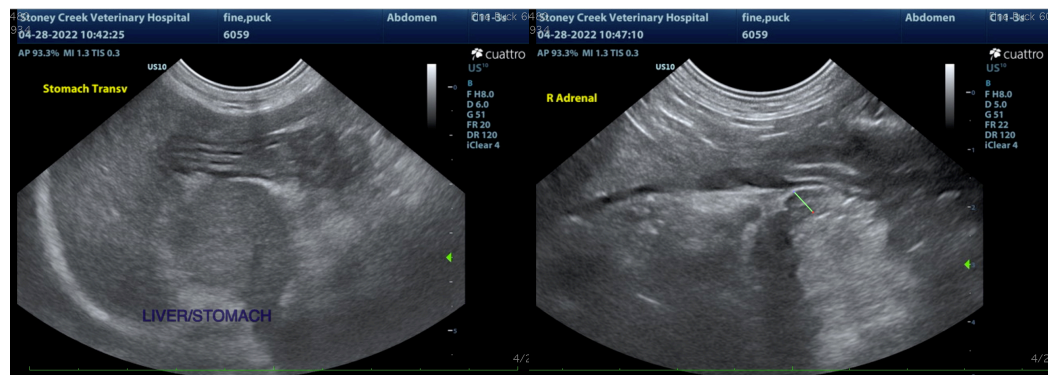
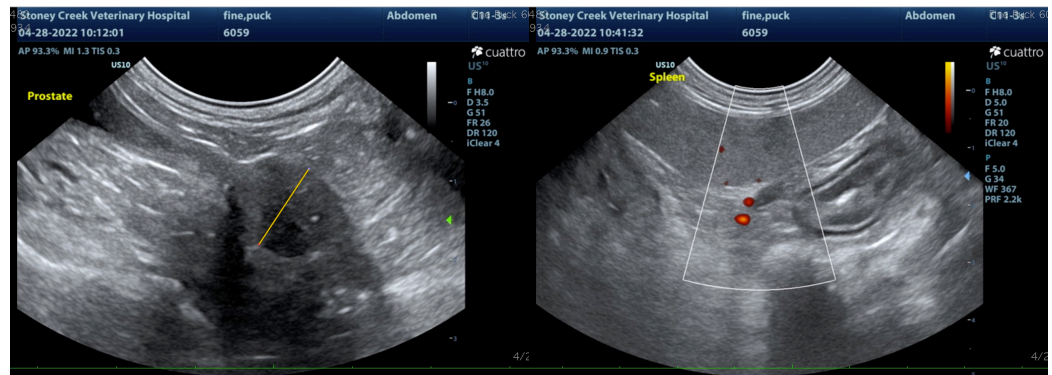
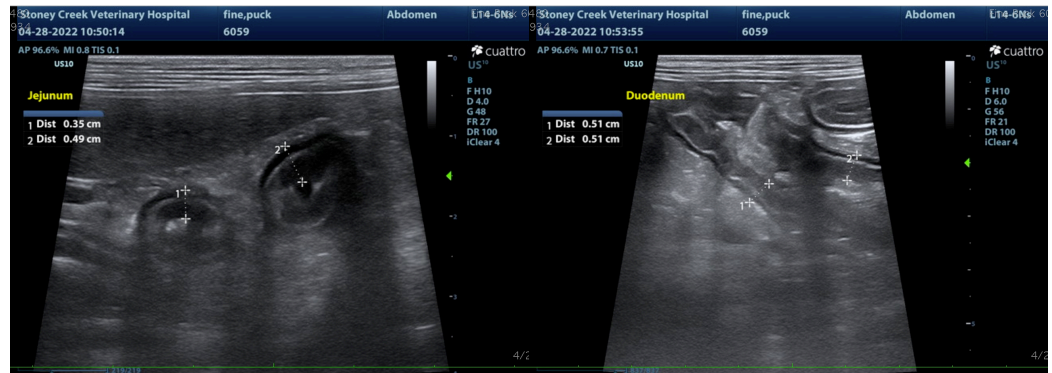
Dr. Tam Mengine

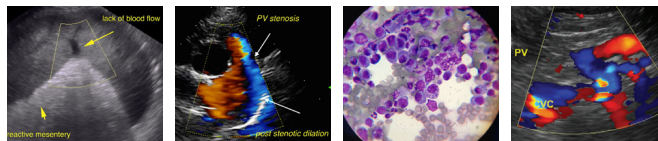
**INVOICE**

37250

**DATE**

4/28/22





**PATIENT**

Puck Fine

The information and recommendations provided are based on the images presented by the referring veterinarian/sonographer. No evaluation can be communicated regarding pathology that was not visible in the image/video clips provided.

**SPECIES**

Canine

Thank you for this referral. If the clinical or image interpretation does not parallel your findings or if I can be of any further assistance please contact me.

Kathleen Sennello DVM,MS, Diplomate ACVIM (Small animal Internal Medicine)

**BREED**

Yorkie

kathleen.sennello@sonopath.com

**SEX**

Neutered Male

**AGE**

12 Years

**WEIGHT**

10.2 Pounds

**INTERPRETED BY**

Kathleen Sennello DVM,  
MS, Diplomate ACVIM  
(Small Animal Internal  
Medicine)

**IMAGING  
PERFORMED BY**

Dr. Tam Mengine

**HOSPITAL NAME**

Stoney Creek VH

**REFERRING VET**

Dr. Tam Mengine

**INVOICE**

37250

**DATE**

4/28/22