

PATIENT PRESENTING CLINICAL SIGNS

Echo Okraski Hypercalcemia and weight loss.

SPECIES

Feline

Abnormal PE/Chem/CBC/UA Results: Sedated- Chemistry screen: Increased calcium. Corrected calcium also increased CBC: No significant finding Fecal: No O & P seen Urinalysis: Increased pH likely causing falsely increase protein. Also contributing is occult blood from cystocentesis. Total T4: Within normal limits FeLV antibody test: Negative FIV antigen test: Negative A: Hypercalcemia.

BREED

Siamese

ULTRASONOGRAPHIC EXAMINATION OF THE ABDOMEN

SEX

Urinary System

Spayed Female

The urinary bladder is moderately distended with anechoic urine. The Bladder wall, trigone, ureteral papillae, and visible urethra (to a depth of 2cm) appear normal with no evidence of wall thickening, mucosal irregularities, masses, or cystic calculi.

AGE

5y

The left kidney is small and irregular measuring 1.39 cm with pyelectasia measuring 0.27 cm. Overall echogenicity is slightly hyperechoic with poor corticomedullary distinction and a typical 1:3 cortex: medulla ratio. There is no evidence of focal perinephric inflammation or effusion. There is no evidence of nephroliths, infarcts, or hydroureter. Renal vasculature is normal.

WEIGHT

4.5kg

The right kidney is borderline large (likely compensatory) measuring at 4.46 cm. Overall echogenicity is slightly hyperechoic with poor corticomedullary distinction and a typical 1:3 cortex: medulla ratio. There is no evidence of focal perinephric inflammation or effusion. There is no evidence of pyelectasia, nephroliths, infarcts or hydroureter. Renal vasculature is normal.

INTERPRETED BY

Kathleen Sennello DVM,
MS, Diplomate ACVIM
(Small Animal Internal
Medicine)

Adrenal Glands

IMAGING PERFORMED BY

Loetitia Saint-Jacques,
LVT

The left adrenal gland is normal in size measuring 0.41 cm at the caudal pole. It is observed in its normal position cranial to the left renal artery. It is normal in appearance (uniformly hypoechoic) and shape with no evidence of a mass effect.

The right adrenal gland is normal in size measuring 0.4 cm at the caudal pole. It is observed in its normal position between the cranial aspect of the right kidney and the caudal vena cava. It is normal in appearance (uniformly hypoechoic) and shape with no evidence of a mass effect.

HOSPITAL NAME

South Reno Veterinary
Hospital

Spleen

The spleen is subjectively normal in size (0.9 cm), echotexture is homogenous, and the splenic capsule is smooth with no irregularities. The blood flow through the hilus and splenic parenchyma appears normal. No focal parenchymal abnormalities are visualized.

REFERRING VET

Dr. Schmitt

Liver

INVOICE

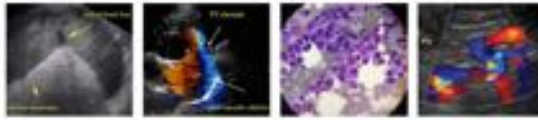
10197

The liver is subjectively normal in size, and echogenicity with smooth peripheral margins. The parenchyma is homogenous echotexture. The visible portions of the vasculature and biliary tract appear normal. No focal nodules or cystic lesions are observed.

DATE

4/27/2023

Gastrointestinal



PATIENT

Echo Okraski

The gall bladder lumen is moderately distended. The wall of the gall bladder is not thickened and has a smooth mucosal surface. There is a mild amount of non-organized echogenic debris. The cystic and common bile ducts are normal/not visible.

SPECIES

Feline

The stomach contains mild fluid in the lumen. It measures at a normal thickness of <0.36cm with some variability due to the presence of rugal folds. The distinction of the gastric wall layers is adequate and there is no impression of reduced peristaltic activity. No masses or focal lesions were observed.

BREED

Siamese

The visualized areas of duodenum, jejunum and ileum have a relatively uniform diameter with minimal fluid distension. Wall thickness is normal. Bowel loops follow a curvilinear path with distinct wall layering maintaining the typical 1:3 muscularis: mucosa layer ratio. The duodenum measured as normal (0.22 cm), and the jejunum measured as normal (0.2 cm.) Visualized peristalsis appears appropriate.

SEX

Spayed Female

There were no focal lesions consistent with obstruction or a mass effect observed.

AGE

5y

The ileocecal junction was visualized and exhibited normal intact wall layering and is subjectively of normal thickness. Sections of colon are visualized with formed fecal material and gas shadowing distally. There is no observed focal or generalized colon wall thickening or loss of layering.

WEIGHT

4.5kg

Pancreas

The area of the pancreas is normal and isoechoic to surrounding mesentery. There is no evidence of nodules or cystic lesions. There is no evidence of regional mesenteric inflammation or fluid.

Free Abdomen

INTERPRETED BY

Kathleen Sennello DVM,
 MS, Diplomate ACVIM
 (Small Animal Internal
 Medicine)

Evaluation of the peritoneal cavity did not reveal any evidence of effusion, or subjective lymphadenomegaly. The Medial iliac nodes appear normal and there was no evidence of a caudal aortic thrombus at the bifurcation. The omentum is of normal uniform echogenicity.

IMAGING PERFORMED BY

Loetitia Saint-Jacques,
 LVT

PRIMARY FINDINGS

- Small irregular left kidney with minimal normal architecture and pyelectasia. Findings are most consistent with a shrunken fibrotic kidney.
- Borderline large right kidney with decreased corticomedullary distinction. Mild loss of corticomedullary distinction in both kidneys could be consistent with chronic degenerative disease or interstitial nephrosis. This kidney is likely large due to compensation for the small left kidney.
- Mild gallbladder debris. The significance of the aggregated gallbladder debris is unclear. This could represent an early mucocele, cholestasis, or may be secondary to fasting but seems unlikely to be causing a current issue. Recommend continued monitoring.

HOSPITAL NAME

South Reno Veterinary
 Hospital

REFERRING VET

Dr. Schmitt

INTERPRETATION OF THE FINDINGS & FURTHER RECOMMENDATIONS

INVOICE

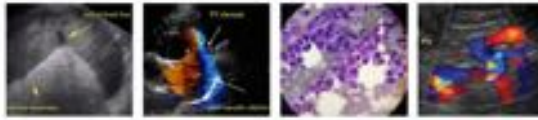
10197

The left kidney is somewhat shrunken and has minimal normal architecture and the right kidney is larger and likely compensating for the left kidney. I suspect this is unrelated to the hypercalcemia reported and is either likely due to a congenital issue or a previous injury to the left kidney. The remainder of the scan is relatively normal and no obvious cause for the hypercalcemia is visualized.

DATE

4/27/2023

Recommend hypercalcemia of malignancy panel to Michigan State University with ionized calcium, PTH, PTHrP. If the ionized calcium is elevated and this is not diagnostic then recommend continued



PATIENT

Echo Okraski

SPECIES

Feline

BREED

Siamese

SEX

Spayed Female

AGE

5y

WEIGHT

4.5kg

INTERPRETED BY

Kathleen Sennello DVM,
MS, Diplomate ACVIM
(Small Animal Internal
Medicine)

**IMAGING
PERFORMED BY**

Loetitia Saint-Jacques,
LVT

HOSPITAL NAME

South Reno Veterinary
Hospital

REFERRING VET

Dr. Schmitt

INVOICE

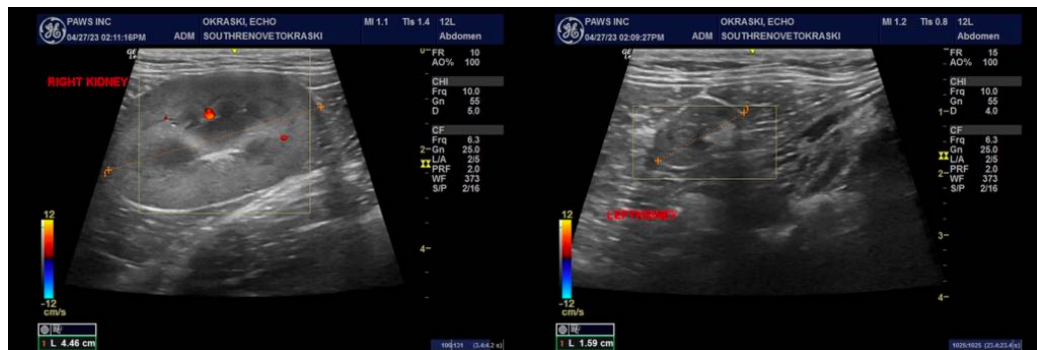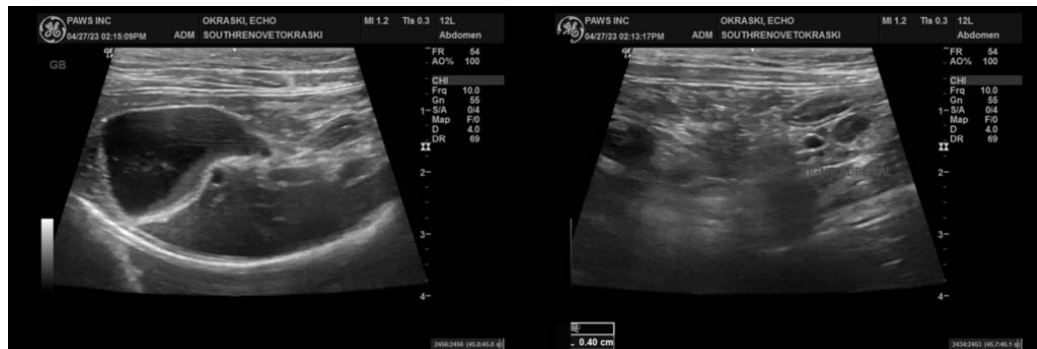
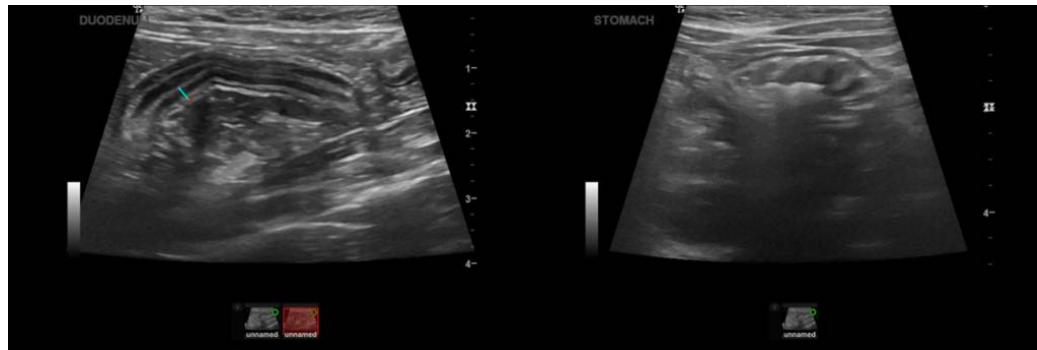
10197

DATE

4/27/2023

evaluation for possible underlying neoplastic process, (good oral exam if possible) a rectal exam to palpate the anal glands, and three view thoracic radiographs, as well as CBC looking for any criteria of leukemia.

Additionally, there are some toxins and causes for granulomatous disease that can cause hypercalcemia. If an identifiable cause cannot be determined, then this is likely idiopathic hypercalcemia. Depending on the degree of hypercalcemia this can make cats not feel well and diminish their appetite. At this point consider medical and dietary therapy to try and reduce the calcium levels.





PATIENT

Echo Okraski

SPECIES

Feline

BREED

Siamese

SEX

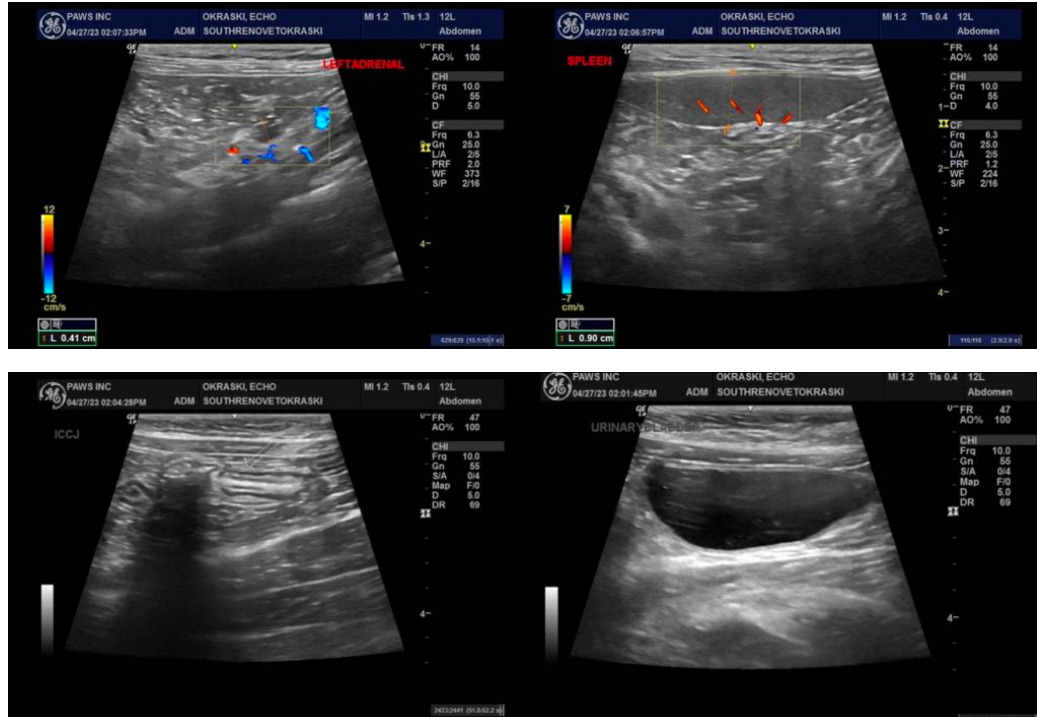
Spayed Female

AGE

5y

WEIGHT

4.5kg



INTERPRETED BY

Kathleen Sennello DVM,
MS, Diplomate ACVIM
(Small Animal Internal
Medicine)

**IMAGING
PERFORMED BY**

Loetitia Saint-Jacques,
LVT

HOSPITAL NAME

South Reno Veterinary
Hospital

REFERRING VET

Dr. Schmitt

INVOICE

10197

DATE

4/27/2023

The information and recommendations provided are based on the images presented by the referring veterinarian/sonographer. No evaluation can be communicated regarding pathology that was not visible in the image/video clips provided.

Thank you for this referral. If the clinical or image interpretation does not parallel your findings or if I can be of any further assistance, please contact me.

Kathleen Sennello DVM, MS, Diplomate ACVIM (Small animal Internal Medicine)

kathleen.sennello@sonopath.com