

IMAGING PERFORMED BY

IntraPet.com



SonoPath

Clinical Sonography & Telecytology

EDUCATIONAL TELECONSULTATION SERVICES™

1-800-838-4268 info@sonopath.com SonoPath.com

DATE PRESENTING CLINICAL SIGNS

4/27/22 Several episodes of vomiting last time went to EVC abdominal US showed changes to small intestine and pancreas.

PATIENT

Speedy Pliska
Current Medications: None.
Lab Results: EVC- Low Folate and Low Iron 3/2022. Unremarkable senior profile done 4/20/22.
Date of Previous IntraPet Ultrasound: No previous.
Sedation: Not required to complete full diagnostic ultrasound.
Stat Report: Not requested.

SPECIES

Feline

ULTRASONOGRAPHIC EXAMINATION OF THE ABDOMEN

BREED

DSH

SEX

Neutered Male

AGE

6/12/15

WEIGHT

9.26 Pounds

INTERPRETED BY

Kathleen Sennello DVM,
MS, Diplomate ACVIM
(Small Animal Internal
Medicine)

IMAGING PERFORMED BY

Andi Parkinson RDMS

HOSPITAL NAME

Frederick Road VH

REFERRING VET

Dr. Cannon

INVOICE

37220

Urinary System

The urinary bladder is moderately distended with mild primarily suspended echogenic debris present. The Bladder wall, trigone, ureteral papillae and visible urethra (to a depth of 2cm) appear normal with no evidence of wall thickening, mucosal irregularities, masses or calculi. Echogenic debris of this type can be associated with small crystals, cellular debris and proteinaceous debris.

The left kidney has a normal shape and size (4.22 cm). Overall echogenicity is normal with adequate corticomedullary distinction and a typical 1:3 cortex:medulla ratio. There is no evidence of perinephric inflammation or effusion. There is no evidence of pyelectasia, nephroliths, infarcts or hydroureter. Renal vasculature is normal.

The right kidney is normal in size (3.9 cm), but somewhat irregular in shape. There is an irregularity in the cranial pole of the right kidney, most consistent with a previous infarct. Overall echogenicity is normal with adequate corticomedullary distinction and a typical 1:3 cortex:medulla ratio. There is no evidence of perinephric inflammation or effusion. There is no evidence of pyelectasia, nephroliths or hydroureter. Renal vasculature is normal.

Adrenal Glands

The left adrenal gland is normal in size measuring 0.33 cm at the caudal pole. It is observed in its normal position cranial to the left renal artery. It is normal in appearance (uniformly hypoechoic) and shape with no evidence of a mass effect.

The right adrenal gland is normal in size measuring 0.38 cm at the caudal pole. It is observed in its normal position between the cranial aspect of the right kidney and the caudal vena cava. It is normal in appearance (uniformly hypoechoic) and shape with no evidence of a mass effect.

Spleen

The spleen is normal/borderline large in size (1.2 cm at the level of the hilus), echotexture is homogenous, and the splenic capsule is smooth with no irregularities. The blood flow through the hilus and splenic parenchyma appears normal. No focal parenchymal abnormalities are visualized.

Liver

The liver is subjectively normal in size, and echogenicity with smooth peripheral margins. The parenchyma is homogenous echotexture. The visible portions of the vasculature and biliary tract appear normal. No focal nodules or cystic lesions are observed.

The appearance of the gallbladder is somewhat abnormal in that it is septate and bilobed. The lumens are mildly/moderately distended. The walls of the gallbladders are not thickened and have a smooth mucosal surface. Luminal contents are primarily anechoic. The cystic and common bile ducts are normal/not visible.

Gastrointestinal

The stomach contains minimal luminal contents. It measures at a normal thickness of <0.36cm with some variability due to the presence of rugal folds. The distinction of the gastric wall layers is adequate and there is no impression of reduced peristaltic activity. No masses or focal lesions were observed.

The visualized areas of duodenum, jejunum and ileum have a uniform diameter with minimal fluid distension. Wall thickness is normal to slightly increased. Bowel loops follow a typical curvilinear path with distinct wall layering, but some areas display a prominent muscularis layer which does not display the typical 1:3 muscularis:mucosa layer ratio. Jejunum wall measured 0.24 cm. Visualized peristalsis appears appropriate. There were no focal lesions consistent with obstruction or a mass effect observed.

The ileocecal junction was visualized and exhibited normal intact wall layering and is subjectively of normal thickness. Sections of colon are visualized with formed fecal material and gas shadowing distally. There is no observed focal or generalized colon wall thickening or loss of layering.

Pancreas

The pancreas is prominent and hypoechoic as compared to the surrounding isoechoic mesentery. There is no evidence of nodules or cystic lesions. There is no evidence of regional mesenteric inflammation or fluid.

Free Abdomen

Evaluation of the peritoneal cavity did not reveal any evidence of effusion. There are occasional prominent mesenteric lymph nodes. A mesenteric lymph node is visualized at 0.21 cm, and a sublumbar lymph node measures at 0.54 cm in diameter.

PRIMARY FINDINGS

- Hypoechoic, prominent pancreas – The pancreatic changes are most consistent with mild pancreatitis or a recent episode of pancreatic inflammation.
- Prominent muscularis layer to the small intestine – The small intestinal wall changes are most consistent with an inflammatory process (i.e., inflammatory bowel disease) with a low possibility of emerging lymphoma.
- Prominent, but not enlarged mesenteric lymph nodes – The prominent abdominal lymph nodes are most consistent with reactive lymphadenitis or lymphoid hyperplasia. Neoplastic infiltration is considered less likely.
- Borderline large spleen – Given the anemia reported, recommend a fine needle aspirate.

SECONDARY FINDINGS

- Echogenic debris within the urinary bladder – The echogenic debris in the bladder lumen could be consistent with cells, crystals, and/or mucus.
- Septate gallbladder – likely an incidental finding.
- Irregularly shaped right kidney – most consistent with previous renal infarct.

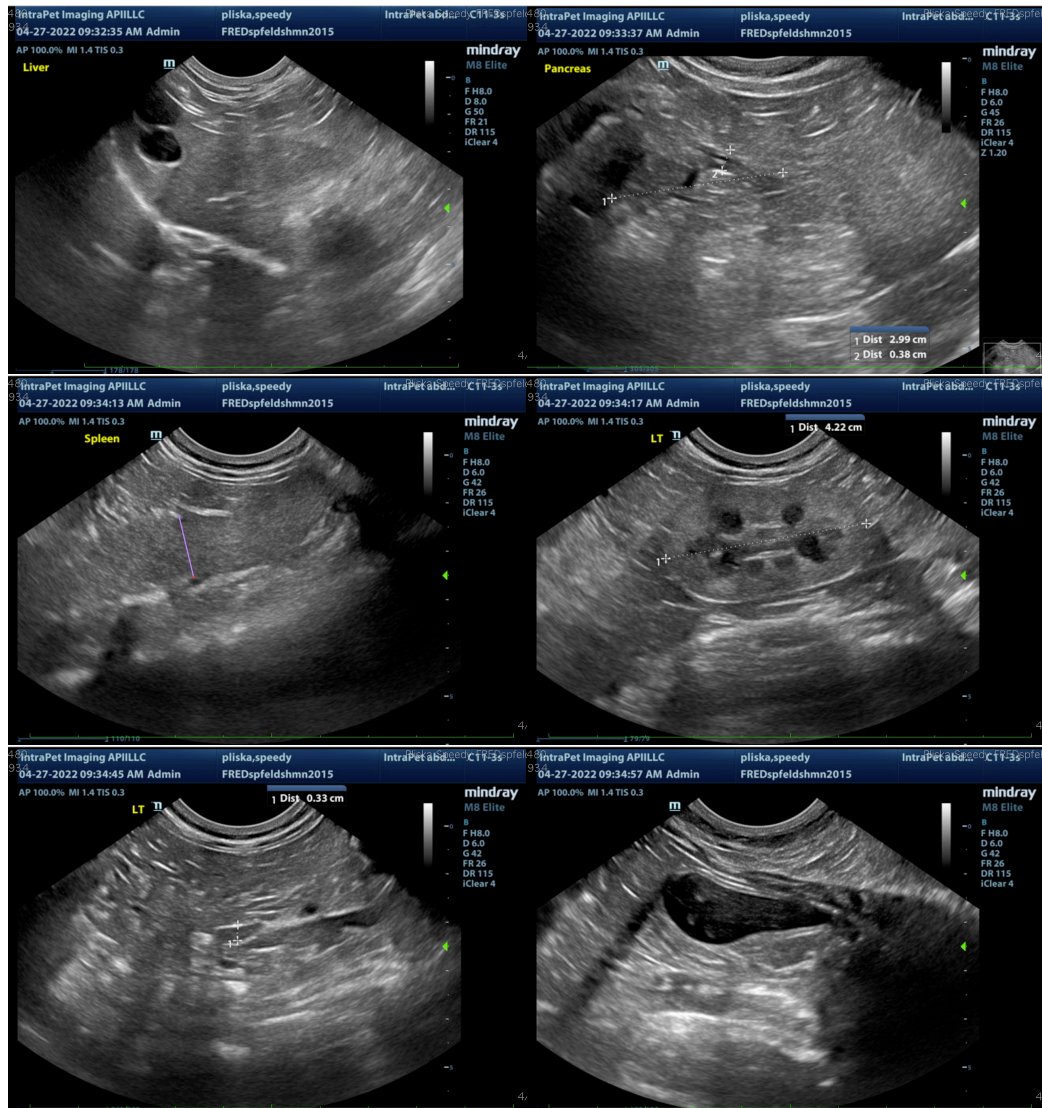
INTERPRETATION OF THE FINDINGS & FURTHER RECOMMENDATIONS

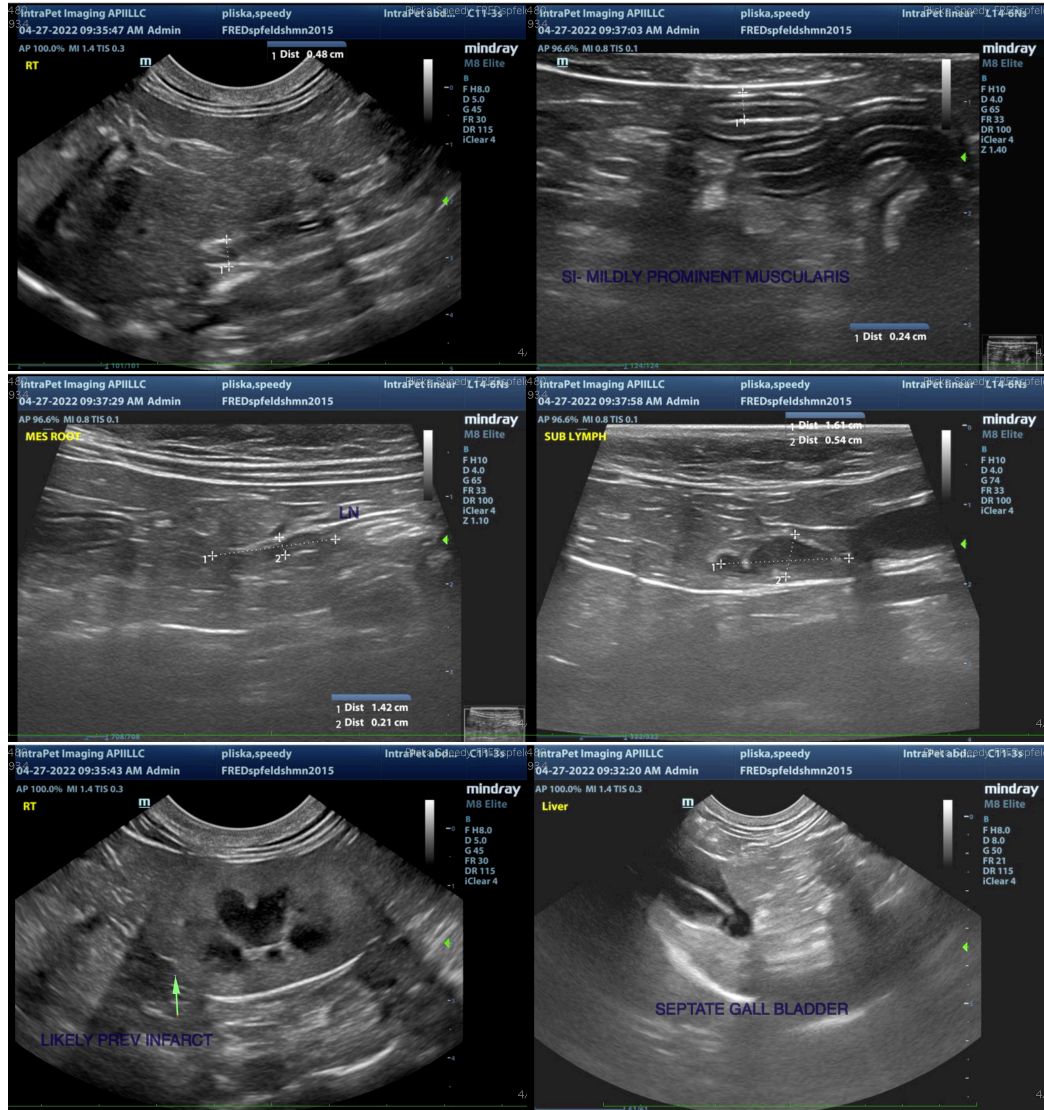
The changes observed on today's scan are relatively mild and subtle. Given the previously reported symptoms and low iron levels, there would be concern for underlying gastrointestinal disease. No focal lesions are visualized on today's scan, but there is a prominent muscularis layer, which can be associated with

underlying inflammation. The mesenteric lymph nodes are somewhat prominent and the pancreas is hypoechoic. Given the normal PLI level, pancreatic changes could be consistent with previous pancreatic disease and remodeling, but the low iron levels are consistent with chronic blood loss from some source (typically GI). Therefore, if symptoms persist, I would consider an upper GI endoscopy to look for any gastric ulceration that is not evident on today's scan. I would consider iron supplementation if a microcytic hypochromic anemia is present, and anti-ulcer therapy. Additionally, you could consider a novel protein/hydrolyzed protein prescription diet in case there is underlying food allergy or IBD.

If 3-view thoracic radiographs have not been performed, recommend doing so to ensure there is not concurrent intrathoracic disease.

Recommend urinalysis and culture to further investigate the echogenic urine visualized.





The information and recommendations provided are based on the images presented by the referring veterinarian/sonographer. No evaluation can be communicated regarding pathology that was not visible in the image/video clips provided.

Thank you for this referral. If the clinical or image interpretation does not parallel your findings or if I can be of any further assistance please contact me.

Kathleen Sennello DVM,MS, Diplomate ACVIM (Small animal Internal Medicine)
 kathleen.sennello@sonopath.com