

IMAGING PERFORMED BY

IntraPet.com



SonoPath

Clinical Sonography & Telecytology

EDUCATIONAL TELECONSULTATION SERVICES™

1-800-838-4268 info@sonopath.com SonoPath.com

DATE PRESENTING CLINICAL SIGNS

4/27/22 Recent PU/PD and lethargy - labwork 4/19/22 reveals SDMA 30, Cr 3.7, BUN 62; CBC wnl; HWT and tick titers neg. Radiographs 4/19/22 reveals likely hepatic mass(es). CBC/Chemistry one month ago was wnl, except mild K elevation - ACTH stim. test neg. for Addison's

PATIENT

Shada Pennell Current Medications: 75mg Carprofen bid indef. - 4/25/22 decreased to 37.5mg bid, 16mg Apoquel sid to qod - recently stopped

SPECIES

Canine Lab Results: See attached. Date of Previous IntraPet Ultrasound: No previous. Sedation: Not required to complete full diagnostic ultrasound. Stat Report: Not requested.

BREED

Labrador Retriever

SEX

Spayed Female

AGE

2/19/08

WEIGHT

77.2 Pounds

INTERPRETED BY

Kathleen Sennello DVM, MS, Diplomate ACVIM (Small Animal Internal Medicine)

IMAGING PERFORMED BY

Andi Parkinson RDMS

HOSPITAL NAME

Essex Middle River VC

REFERRING VET

Dr. Zulty

INVOICE

37215

ULTRASONOGRAPHIC EXAMINATION OF THE ABDOMEN

Urinary System

The urinary bladder is moderately distended with very echogenic urine. The Bladder wall appears diffusely thickened and irregular, measuring at 0.59 cm. The trigone, ureteral papillae and visible urethra (to a depth of 2cm) appear normal with no evidence of wall thickening, mucosal irregularities, or masses. In the dependent portion of the urinary bladder, there is a large amount of shadowing mineralized debris, most consistent with small stones and sandy mineralization.

The left kidney has a normal shape and size (7.83 cm) with a large amount of intrapelvic mineralizations, consistent with numerous mineralized calculi or a grouping of mineralized stones. Overall echogenicity is slightly hyperechoic with poor corticomedullary distinction and a typical 1:3 cortex:medulla ratio. There is no evidence of perinephric inflammation or effusion. There is no evidence of pyelectasia, infarcts or hydroureter. Renal vasculature is normal.

The right kidney has a normal shape and size (7.02 cm) with numerous areas of shadowing mineralization within the renal pelvis. Overall echogenicity is slightly hyperechoic with poor corticomedullary distinction and a typical 1:3 cortex:medulla ratio. There is no evidence of perinephric inflammation or effusion. There is no evidence of pyelectasia, nephroliths, infarcts or hydroureter. Renal vasculature is normal.

Adrenal Glands

The left adrenal gland is normal in size measuring 0.98 cm at the caudal pole. It is observed in its normal position cranial to the left renal artery. It is normal in appearance (uniformly hypoechoic) and shape with no evidence of a mass effect.

The region of the right adrenal (between right cranial kidney and vena cava) is unremarkable, but the adrenal is not distinctly visualized. No evidence of a mass effect.

Spleen

The spleen is subjectively normal in size. The spleen echotexture is heterogenous and mildly mottled, the splenic capsule is smooth with no irregularities. The blood flow through the hilus and splenic parenchyma appears normal. There is at least one ill-defined, hypoechoic nodule visualized in the parenchyma, measuring 1.4 cm.

Liver

The liver is subjectively normal in size, and echogenicity with smooth peripheral margins. The parenchyma is heterogenous in echotexture with subtle, indistinct focal mottling. The visible portions of the vasculature and biliary tract appear normal. No focal nodules or cystic lesions are observed.

The gallbladder lumen is moderately distended. The gallbladder has a large amount of mineralized, sandy dependent debris, but the wall appears normal. The cystic and common bile ducts are normal/not visible.

Gastrointestinal

The stomach contains minimal luminal contents. It measures at a normal thickness of <0.7cm with some variability due to the presence of rugal folds. The distinction of the gastric wall layers is adequate and there is no impression of reduced peristaltic activity. No masses or focal lesions were observed.

The visualized areas of duodenum, jejunum and ileum have a relatively uniform diameter with minimal fluid distension. Wall thickness is normal. Bowel loops follow a curvilinear path with distinct wall layering maintaining the typical 1:3 muscularis:mucosa layer ratio. The duodenum measured as normal (between 0.3-0.5cm in wall thickness) and the jejunum measured as normal (between 0.2-0.47cm.) Visualized peristalsis appears appropriate. There were no focal lesions consistent with obstruction or a mass effect observed.

The ileocecal junction was visualized and exhibited normal intact wall layering and is subjectively of normal thickness. Sections of colon are visualized with formed fecal material and gas shadowing distally. There is no observed focal or generalized colon wall thickening or loss of layering.

Pancreas

The pancreas is normal and isoechoic to surrounding mesentery. There is no evidence of nodules or cystic lesions. There is no evidence of regional mesenteric inflammation or fluid.

Free Abdomen

Evaluation of the peritoneal cavity did not reveal any evidence of effusion, or subjective lymphadenomegaly. The Medial iliac nodes appear normal and there was no evidence of a caudal aortic thrombus at the bifurcation. The omentum is of normal uniform echogenicity.

Other

A large intraabdominal lipoma is visualized on the left side, measuring 8.8 cm x 5.64 cm.

ULTRASONOGRAPHIC FINDINGS

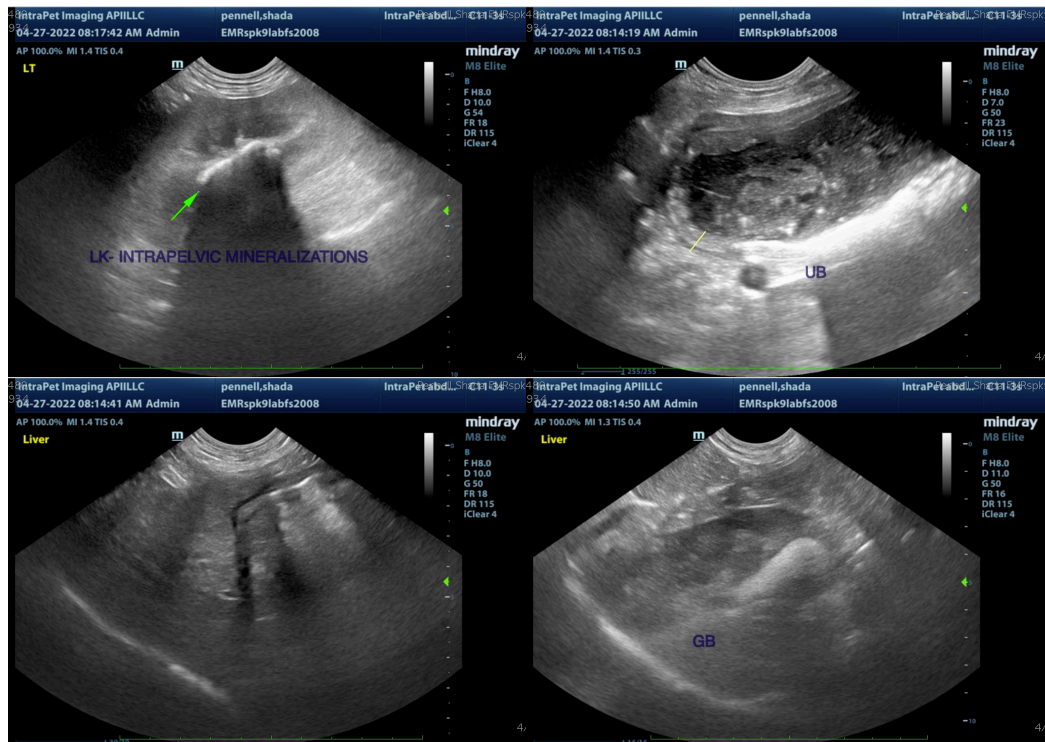
- Decreased corticomedullary distinction in both kidneys with intrapelvic mineralization – Mild loss of corticomedullary distinction in both kidneys could be consistent with chronic degenerative disease or interstitial nephrosis. The mineralizations in the region of the renal pelvises likely represent numerous calculi. No evidence of obstruction visualized.
- Large amount of echogenic shadowing debris within the urinary bladder – most consistent with sandy debris, stones. Recommend urinalysis and culture.
- Mildly mottled spleen with ill-defined, hypoechoic nodule – There is a non-cavitated, hypoechoic splenic nodule visualized. Differentials include lymphoid hyperplasia, extramedullary hematopoiesis, infiltrative neoplasia, inflammation, other. Cytology or histopathology would be necessary to get a definitive diagnosis.
- Mildly heterogeneous liver – The diffuse hepatic changes are non-specific and could be consistent with vacuolar hepatopathy, nodular hyperplasia, inflammatory/immune-mediated disease, fibrosis, extramedullary hematopoiesis, toxic hepatopathy (e.g., copper), infiltrative neoplasia (less likely) or other hepatopathy. This could be a normal finding in an older dog.
- Mineralized, shadowing debris within the gallbladder lumen – most consistent with sandy debris or gall stones.

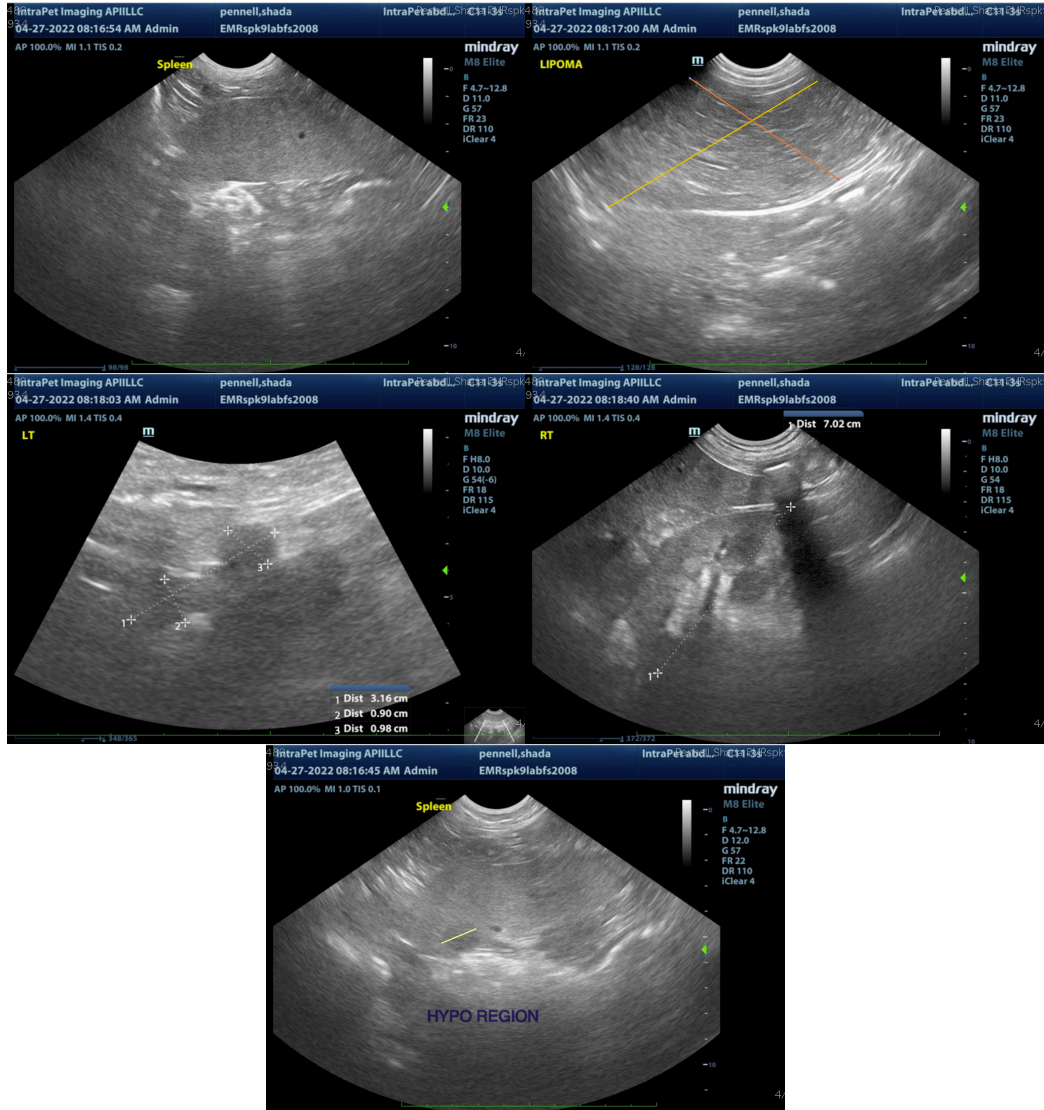
- Isoechoic mass effect in the left abdomen – most consistent with an intraabdominal lipoma. Recommend fine needle aspirate to confirm.

INTERPRETATION OF THE FINDINGS & FURTHER RECOMMENDATIONS

There are mineralizations and stones evident in both the urinary bladder and in the kidneys themselves. There is no obvious evidence of dilation or obstruction present, but there would be concern based on these findings for possible pyelonephritis. Recommend urinalysis and culture and diuresis with continued monitoring of the kidneys in case a stone should shift and cause an obstruction. Recommend blood pressure evaluation. I suspect the stones in the urinary bladder may be small enough to pass, but recommend abdominal radiographs to confirm the size and number of stones visualized in the urinary bladder and in the kidneys. Avoid any potential nephrotoxic medication such as nonsteroidals, aminoglycosides, etc.

The spleen is mildly mottled, and there is a small, ill-defined, hypoechoic nodule visualized. Options moving forward would include either a fine needle aspirate of this area of the spleen or continued monitoring. Additionally, there is mineralized debris within the gallbladder. If liver enzyme elevations are not present, then this could be an incidental finding, and continued monitoring is warranted.





The information and recommendations provided are based on the images presented by the referring veterinarian/sonographer. No evaluation can be communicated regarding pathology that was not visible in the image/video clips provided.

Thank you for this referral. If the clinical or image interpretation does not parallel your findings or if I can be of any further assistance please contact me.

Kathleen Sennello DVM,MS, Diplomate ACVIM (Small animal Internal Medicine)
 kathleen.sennello@sonopath.com