



PATIENT

Apollo Borovoy

SPECIES

Feline

BREED

DLH

SEX

Neutered Male

AGE

16 Years

WEIGHT

9.6 Pounds

INTERPRETED BY

Kathleen Sennello DVM,
MS, Diplomate ACVIM
(Small Animal Internal
Medicine)

IMAGING PERFORMED BY

Sorbo

HOSPITAL NAME

Back Bay Vet Clinic

REFERRING VET

Dr. Wheeler

INVOICE

37213

DATE

4/27/22

PRESENTING CLINICAL SIGNS

16yo CM DLH. 6-12m hx of intermittent (once every 4-8 weeks) episodes of V/anorexia that usually self resolve in 24-48h. Hx of gradual wt loss over past 4 years: 16# 2017 (overweight), 12# in 2020, 9.6# in Nov 2021, stable at 9.6# in April 2022. CKD diagnosed 2021, initially IRIS stage 1 and gradually progressed past 12 months to IRIS Stage 2 (creat 1.9, BUN39, SDMA 16, phos 3.6, USG1.014). Recent new mild total Ca (11.6) and proBNP (101) elevations on annual labs. Submitting HyperCa of malignancy panel today and echo scheduled next month. Renal diet and dasuquin.

Abnormal PE/Chem/CBC/UA Results: 4/13/22: - CBC: monos 0.684 (sl H) - Chem: SDMA 16, creat 1.9, BUN 39, phos 3.6 (N), Ca 11.6, K+ 6.0, remainder WNL - proBNP 101 - UA: 1.014, trace protein, 2+ blood, 15-20 RBCs, remainder WNL - T4 2.2

ULTRASONOGRAPHIC EXAMINATION OF THE ABDOMEN

Urinary System

The urinary bladder is moderately distended with anechoic urine. The Bladder wall, trigone, ureteral papillae and visible urethra (to a depth of 2cm) appear normal with no evidence of wall thickening, mucosal irregularities, masses or cystic calculi.

The left kidney has a normal shape and size (3.6 cm). Overall echogenicity is slightly hyperechoic with poor corticomedullary distinction and a typical 1:3 cortex:medulla ratio. There is no evidence of perinephric inflammation or effusion. There is no evidence of pyelectasia, nephroliths, infarcts or hydroureter. Renal vasculature is normal.

The right kidney has a normal shape and size (3.68 cm). Overall echogenicity is slightly hyperechoic with poor corticomedullary distinction and a typical 1:3 cortex:medulla ratio. There is no evidence of perinephric inflammation or effusion. There is no evidence of pyelectasia, nephroliths, infarcts or hydroureter. Renal vasculature is normal.

Adrenal Glands

The left adrenal gland is normal in size measuring 0.44 cm at the caudal pole. It is observed in its normal position cranial to the left renal artery. It is normal in appearance (uniformly hypoechoic) and shape with no evidence of a mass effect.

The right adrenal gland is normal in size measuring 0.48 cm at the caudal pole. It is observed in its normal position between the cranial aspect of the right kidney and the caudal vena cava. It is normal in appearance (uniformly hypoechoic) and shape with no evidence of a mass effect.

Spleen

The spleen is subjectively normal in size. The spleen echotexture is heterogenous and mottled, the splenic capsule is smooth with no irregularities. The blood flow through the hilus and splenic parenchyma appears normal. No focal parenchymal abnormalities are visualized.

Liver

The liver is subjectively normal in size, and echogenicity with smooth peripheral margins. The parenchyma is homogenous echotexture. The visible portions of the vasculature and biliary tract appear normal. No focal nodules or cystic lesions are observed.

The gallbladder lumen is moderately distended. The wall of the gall bladder is not thickened and has a smooth mucosal surface. Luminal contents are primarily anechoic. The bile duct appears dilated and tortuous, measuring up to 0.35 cm.



PATIENT

Gastrointestinal

Apollo Borovoy

The stomach contains minimal luminal contents. It measures at a normal thickness of <0.36cm with some variability due to the presence of rugal folds. The distinction of the gastric wall layers is adequate and there is no impression of reduced peristaltic activity. No masses or focal lesions were observed.

SPECIES

Feline

The visualized areas of duodenum, jejunum and ileum have a uniform diameter with minimal fluid distension. Wall thickness is normal to slightly increased. Bowel loops follow a typical curvilinear path with distinct wall layering, but some areas display a prominent muscularis layer which does not display the typical 1:3 muscularis:mucosa layer ratio. Duodenum wall measured 0.41 cm. Jejunum wall measured 0.31 cm. Visualized peristalsis appears appropriate. There were no focal lesions consistent with obstruction or a mass effect observed.

BREED

DLH

SEX

Neutered Male

The ileocecal junction was visualized and exhibited normal intact wall layering and is subjectively of normal thickness. Sections of colon are visualized with formed fecal material and gas shadowing distally. There is no observed focal or generalized colon wall thickening or loss of layering.

Pancreas

AGE

16 Years

The pancreas is large and hypoechoic to surrounding mesentery. There is no evidence of nodules or cystic lesions. There is evidence of regional mesenteric inflammation. Consistent with mild pancreatitis. The pancreatic duct appears severely dilated, measuring approximately 0.40 cm in diameter.

WEIGHT

9.6 Pounds

Free Abdomen

Evaluation of the peritoneal cavity did not reveal any evidence of effusion, or subjective lymphadenomegaly. The Medial iliac nodes appear normal and there was no evidence of a caudal aortic thrombus at the bifurcation. The omentum is of normal uniform echogenicity.

INTERPRETED BY

Kathleen Sennello DVM,
MS, Diplomate ACVIM
(Small Animal Internal
Medicine)

ULTRASONOGRAPHIC FINDINGS

- Large, hypoechoic pancreas with severely dilated pancreatic duct – The pancreatic changes are most consistent with moderate pancreatitis/pancreatic inflammation. Recommend fPLI testing and continued monitoring for improvement or possible development of a pancreatic abscess. Consider fine needle aspirate if not improving.
- Decreased corticomedullary distinction in both kidneys – Mild loss of corticomedullary distinction in both kidneys could be consistent with chronic degenerative disease or interstitial nephrosis.
- Mildly mottled spleen – The diffuse splenic changes are non-specific and could be consistent with lymphoid hyperplasia, extramedullary hematopoiesis, infiltrative neoplasia, inflammation, other. Cytology or histopathology would be necessary to get a definitive diagnosis.
- Mild bile duct dilation – Dilation of the common bile duct could be consistent with a functional obstruction (i.e. primary hepatic disease resulting in hepatocellular swelling) or with an extrahepatic bile duct obstruction (ie. choledocholith, bile duct tumor, pancreatic disease, other).
- Mildly thickened small intestine with prominent muscularis layer – The small intestinal wall changes are most consistent with an inflammatory process (i.e., inflammatory bowel disease) with a low possibility of emerging lymphoma.

IMAGING PERFORMED BY

Sorbo

HOSPITAL NAME

Back Bay Vet Clinic

REFERRING VET

Dr. Wheeler

INVOICE

37213

DATE

4/27/22



PATIENT

Apollo Borovoy

SPECIES

Feline

BREED

DLH

SEX

Neutered Male

AGE

16 Years

WEIGHT

9.6 Pounds

INTERPRETED BY

Kathleen Sennello DVM,
MS, Diplomate ACVIM
(Small Animal Internal
Medicine)

**IMAGING
PERFORMED BY**

Sorbo

HOSPITAL NAME

Back Bay Vet Clinic

REFERRING VET

Dr. Wheeler

INVOICE

37213

DATE

4/27/22

INTERPRETATION OF THE FINDINGS & FURTHER RECOMMENDATIONS

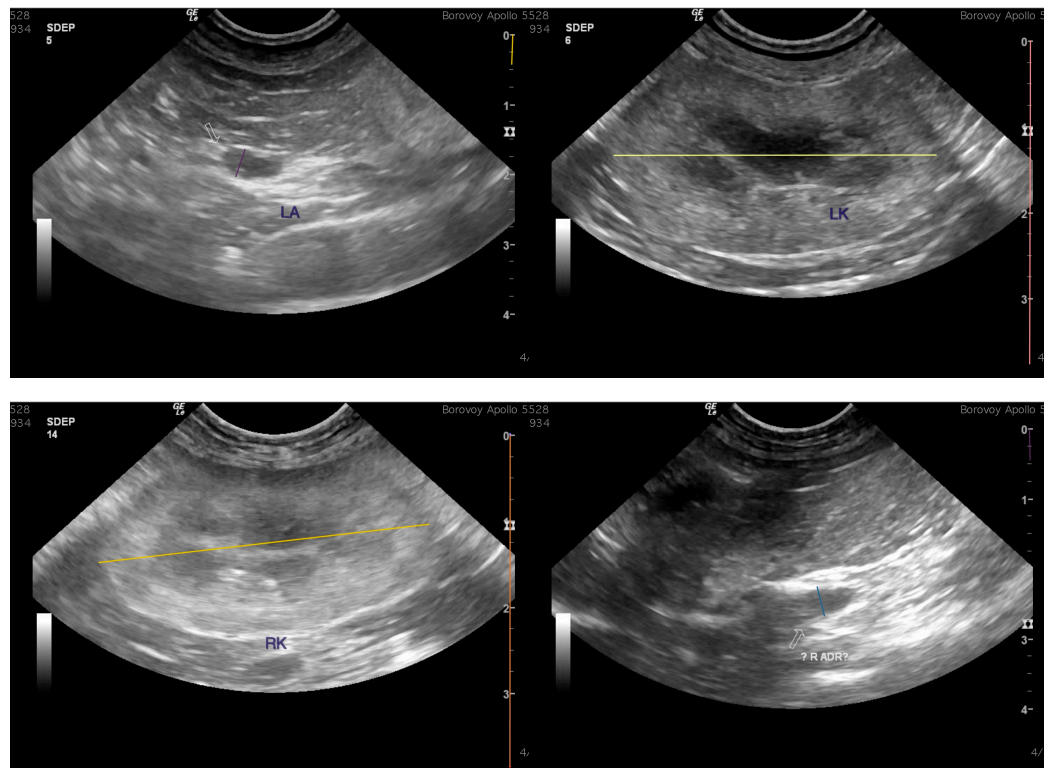
The pancreas is large and hypoechoic with a prominent dilated pancreatic duct. Additionally, the bile duct is somewhat tortuous and dilated. An obstructive process is not visualized, but cannot be ruled out. Consider treatment for cholangiohepatitis/Triaditis with continued monitoring of the bile duct and pancreatic duct. Also consider a GI panel to Texas A&M with a qualitative fPLI, TLI, cobalamin and folate to further evaluate pancreatic and small intestinal changes observed.

The small intestine does appear prominent and “ropey” with a prominent muscularis layer. These changes could represent IBD, intestinal neoplasia, etc., or they could be within normal limits for a geriatric cat.

The renal changes are most consistent with chronic progressive renal disease. Consider blood pressure evaluation and urinalysis and culture in order to obtain a baseline.

Recommend treatment for pancreatitis and possible cholangiohepatitis/Triaditis. If symptoms persist, you could consider a fine needle aspirate of the pancreas, or even biopsies of the small intestine, pancreas, and evaluation of the gallbladder/bile duct.

Consider three view thoracic radiographs to rule out concurrent thoracic disease/involvement.





PATIENT

Apollo Borovoy

SPECIES

Feline

BREED

DLH

SEX

Neutered Male

AGE

16 Years

WEIGHT

9.6 Pounds

INTERPRETED BY

Kathleen Sennello DVM,
MS, Diplomate ACVIM
(Small Animal Internal
Medicine)

**IMAGING
PERFORMED BY**

Sorbo

HOSPITAL NAME

Back Bay Vet Clinic

REFERRING VET

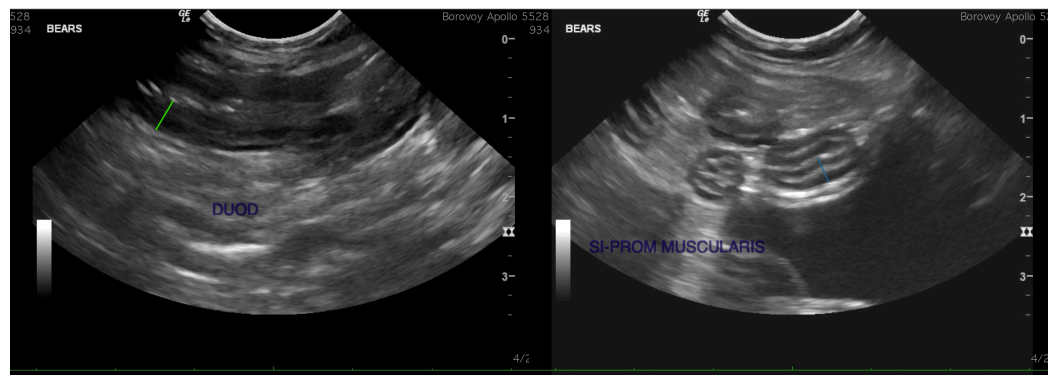
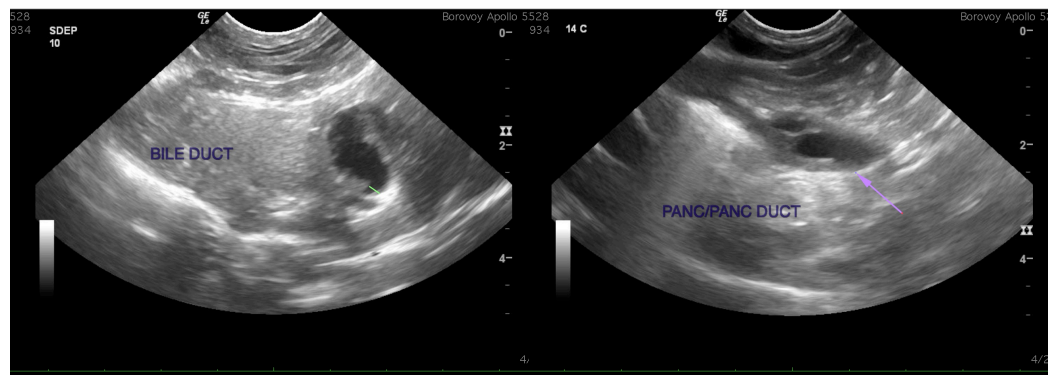
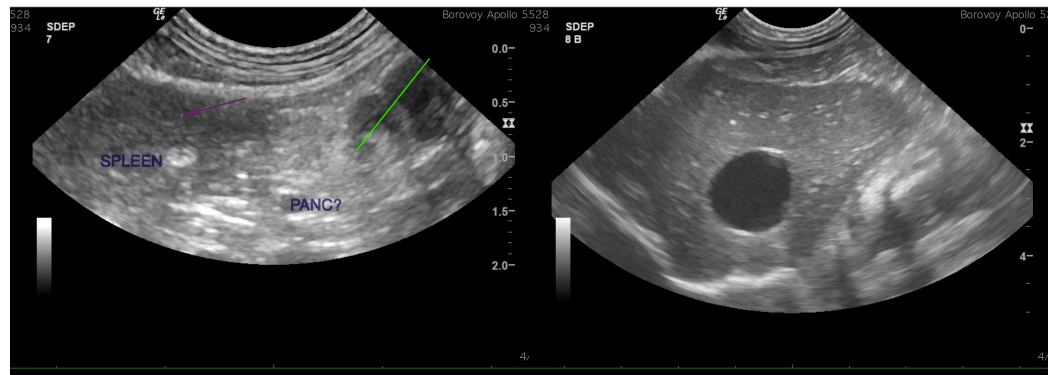
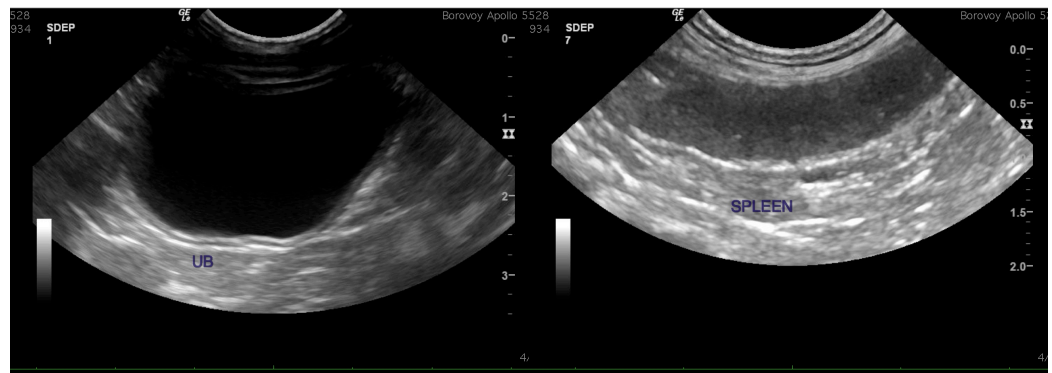
Dr. Wheeler

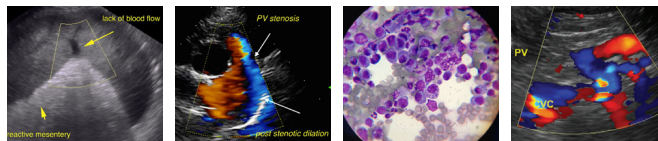
INVOICE

37213

DATE

4/27/22





PATIENT

Apollo Borovoy

SPECIES

Feline

BREED

DLH

SEX

Neutered Male

AGE

16 Years

WEIGHT

9.6 Pounds

INTERPRETED BY

Kathleen Sennello DVM,
MS, Diplomate ACVIM
(Small Animal Internal
Medicine)

**IMAGING
PERFORMED BY**

Sorbo

HOSPITAL NAME

Back Bay Vet Clinic

REFERRING VET

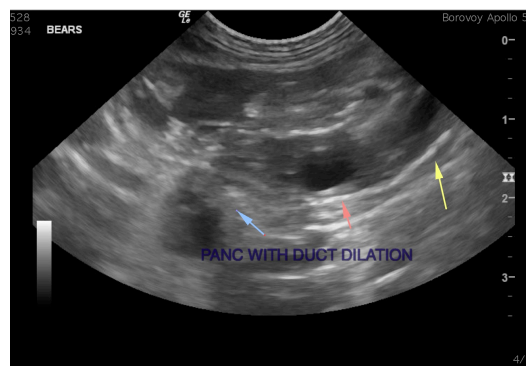
Dr. Wheeler

INVOICE

37213

DATE

4/27/22



The information and recommendations provided are based on the images presented by the referring veterinarian/sonographer. No evaluation can be communicated regarding pathology that was not visible in the image/video clips provided.

Thank you for this referral. If the clinical or image interpretation does not parallel your findings or if I can be of any further assistance please contact me.

Kathleen Sennello DVM,MS, Diplomate ACVIM (Small animal Internal Medicine)

kathleen.sennello@sonopath.com