

IMAGING PERFORMED BY

IntraPet.com



SonoPath

Clinical Sonography & Telecytology

EDUCATIONAL TELECONSULTATION SERVICES™

1-800-838-4268 info@sonopath.com SonoPath.com

DATE PRESENTING CLINICAL SIGNS

4/26/23 Lethargic, weight loss, decreased appetite, Uncomfortable on abdominal palp.

PATIENT

Current Medications: Solensia injections - monthly since Dec.

Wolfie Bopp

Lab Results: BUN- 46, Mild anemia HCT 28%

SPECIES

Feline

Date of Previous IntraPet Ultrasound: no previous.
Sedation: Not required to complete full diagnostic ultrasound.
Stat Report: Not requested.
Imaging Performed By: Rachel Brillhart, RDMS.

BREED

DSH

ULTRASONOGRAPHIC EXAMINATION OF THE ABDOMEN

SEX

Neutered Male

Urinary System

The urinary bladder is moderately distended with anechoic urine. The Bladder wall, trigone, ureteral papillae and visible urethra (to a depth of 2cm) appear normal with no evidence of wall thickening, mucosal irregularities, masses or cystic calculi.

AGE

2012

The left kidney is large (5.65 cm) and irregular with cortical striations, and pyelectasia measuring 0.29 cm. Additionally, there is a small ring of hypoechoic perinephric effusion. Overall echogenicity is slightly hyperechoic with poor corticomedullary distinction and a typical 1:3 cortex:medulla ratio. There is no evidence of nephroliths, infarcts or hydroureter. Renal vasculature is normal.

WEIGHT

14.6 Pounds

The right kidney is large, hypoechoic and irregular, measuring at 4.7 cm with very little normal corticomedullary distinction or architecture. There is the appearance of irregular hypoechoic tissue outside of the right kidney, suggestive of a ruptured capsule and expansion of abnormal tissue. The kidney with this abnormal tissue has a measurement of 5.82 cm and is surrounded by significant inflammation. Additionally, there is an area of hypoechoic abnormal tissue with minimal vascular uptake measuring 1.32 cm x 6.11 cm in the retroperitoneal space, concerning for a possible clot or previous site of hemorrhage. Findings are most consistent with a ruptured renal mass.

INTERPRETED BY

Kathleen Sennello DVM,
MS, Diplomate ACVIM
(Small Animal Internal
Medicine)

HOSPITAL NAME

Mt Airy AH

Adrenal Glands

The region of left adrenal (Cranial to left renal artery) is unremarkable but the adrenal is not distinctly visualized. No evidence of a mass effect is visualized.

REFERRING VET

Dr. Riley

The region of the right adrenal (between right cranial kidney and vena cava) is unremarkable, but the adrenal is not distinctly visualized. No evidence of a mass effect is visualized.

INVOICE

46947

Spleen

The spleen is subjectively normal in size (0.96 cm), echotexture is homogenous, and the splenic capsule is smooth with no irregularities. The blood flow through the hilus and splenic parenchyma appears normal. No focal parenchymal abnormalities are visualized.

Liver

The liver is large in size, and hypoechoic with smooth peripheral margins. The parenchyma is heterogenous in echotexture with subtle, indistinct focal mottling. The visible portions of the vasculature and biliary tract appear normal. No focal nodules or cystic lesions are observed.

The gallbladder lumen is moderately distended. The wall of the gall bladder is not thickened and has a smooth mucosal surface. Luminal contents are mild and primarily anechoic. The cystic and common bile ducts are normal/not visible.

Gastrointestinal

The stomach contains minimal luminal contents. It measures at a normal thickness of <0.36cm with some variability due to the presence of rugal folds. The distinction of the gastric wall layers is adequate and there is no impression of reduced peristaltic activity. No masses or focal lesions were observed.

The visualized areas of duodenum, jejunum and ileum have a relatively uniform diameter with minimal fluid distension. Wall thickness is normal. Bowel loops follow a curvilinear path with distinct wall layering maintaining the typical 1:3 muscularis:mucosa layer ratio. The duodenum measured as normal (between 0.13-0.38cm in wall thickness) and the jejunum measured as normal (between 0.15-0.36cm.) Visualized peristalsis appears appropriate. There were no focal lesions consistent with obstruction or a mass effect observed.

The ileocecal junction was visualized and exhibited normal intact wall layering and is subjectively of normal thickness. Sections of colon are visualized with formed fecal material and gas shadowing distally. There is no observed focal or generalized colon wall thickening or loss of layering.

Pancreas

The pancreas is normal and isoechoic to surrounding mesentery. There is no evidence of nodules or cystic lesions. There is no evidence of regional mesenteric inflammation or fluid.

Free Abdomen

There is scant free abdominal fluid. No lymphadenopathy. The mesentery is significantly inflamed around both kidneys.

Other

There is the suggestion of pleural effusion visualized cranial to the diaphragm, as well as ringdown artifact, which can be an indicator of pulmonary parenchymal disease. Recommend 3-view thoracic radiographs.

ULTRASONOGRAPHIC FINDINGS

- Large, irregular left kidney with abnormal architecture, pyelectasia, and scant perinephric effusion – Differentials would include infection, infiltration, other.
- Large, irregular right kidney with suspected expansile mass effect and retroperitoneal hemorrhage – Findings are highly concerning for renal neoplasia (carcinoma, hemangiosarcoma, lymphoma, other).
- Large, heterogeneous, hypoechoic liver – Hepatic changes are non-specific and could be consistent with inflammation/infection (cholangiohepatitis), infiltrative neoplasia, lipidosis or other hepatopathy.
- Suspect pleural effusion and ringdown artifact – recommend 3-view thoracic radiographs.

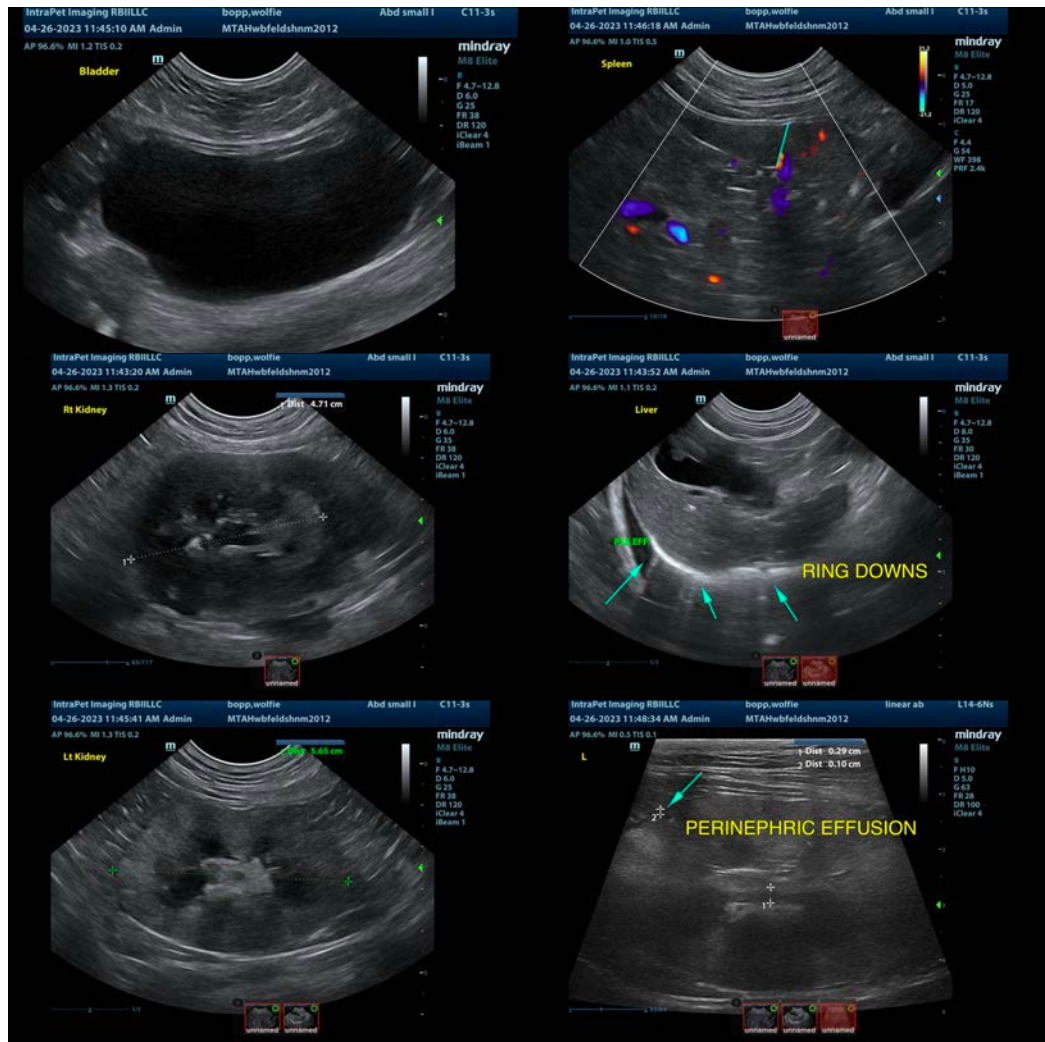
INTERPRETATION OF THE FINDINGS & FURTHER RECOMMENDATIONS

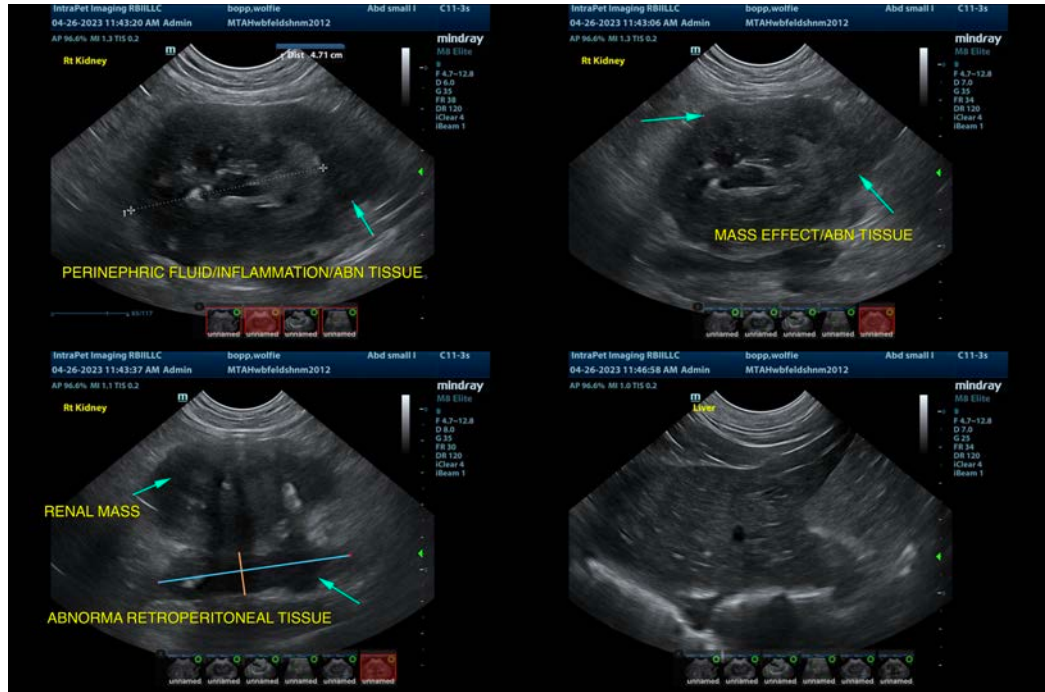
Both kidneys are very abnormal. They are large and irregular with decreased corticomedullary distinction and abnormal architecture. The right kidney in particular appears to have abnormal tissue surrounding, most consistent with infiltrative disease escaping the capsule with associated hemorrhage. Renal trauma could appear similar, so if a hit by car, etc. is suspected, this may need to be ruled out, but otherwise consider a fine needle aspirate of the kidney/abnormal renal tissue, provided a blood pressure and coagulation parameters

are normal.

The liver appears somewhat large and heterogeneous. The significance of this is unclear. Correlate with lab work results, and a fine needle aspirate could be considered to rule out infiltrative disease/metastatic neoplasia.

Recommend three view thoracic radiographs to evaluate for possible concurrent thoracic disease/involvement.





The information and recommendations provided are based on the images presented by the referring veterinarian/sonographer. No evaluation can be communicated regarding pathology that was not visible in the image/video clips provided.

Thank you for this referral. If the clinical or image interpretation does not parallel your findings or if I can be of any further assistance please contact me.

Kathleen Sennello DVM,MS, Diplomate ACVIM (Small animal Internal Medicine)
 kathleen.sennello@sonopath.com