

PATIENT PRESENTING CLINICAL SIGNS

Snuggles Hughes

Geriatric exam only and liver enzyme elevation Working diagnosis Liver enzyme elevation and owner is against trying ursodiol and denamarin due to possible side effects of medications, more holistic approach would be wanted BP 155mmHg

SPECIES

Canine

Abnormal PE/Chem/CBC/UA Results: Globulin 3.8 (mild increase), ALT 257, ALP 1130, GGT 46, Mg 2.6 (H), K+ 5.6 (H), Na/K ratio 26 (L), Chol 531, amylase 1800 (H), PSL 153 (H), thrombocytosis (1000), accuplex negative, fecal negative, UA pH 8.0, 3+ proteinuria, UPCR 4.7 (H), pending and rabies titer non-export. Kidney values are normal at BUN 30/Cr 1.3, UA

BREED

American Eskimo

SEX

Spayed Female

ULTRASONOGRAPHIC EXAMINATION OF THE ABDOMEN

Urinary System

AGE

13 Years

The urinary bladder is moderately distended with anechoic urine. The Bladder wall, trigone, ureteral papillae and visible urethra (to a depth of 2cm) appear normal with no evidence of wall thickening, mucosal irregularities, masses or cystic calculi.

WEIGHT

8.7 kg

The left kidney has a normal shape and size (4.32 cm). Overall echogenicity is slightly hyperechoic with poor corticomedullary distinction and a typical 1:3 cortex:medulla ratio. There is no evidence of focal perinephric inflammation or effusion. There is no evidence of pyelectasia, nephroliths, infarcts or hydroureter. Renal vasculature is normal.

INTERPRETED BY

Kathleen Sennello DVM,
MS, Diplomate ACVIM
(Small Animal Internal
Medicine)

The right kidney has a normal shape and size (5.1 cm). Overall echogenicity is slightly hyperechoic with poor corticomedullary distinction and a typical 1:3 cortex:medulla ratio. There is no evidence of focal perinephric inflammation or effusion. There is no evidence of pyelectasia, nephroliths, infarcts or hydroureter. Renal vasculature is normal.

IMAGING PERFORMED BY

Loetitia Saint-Jacques,
LVT

Adrenal Glands

The left adrenal gland is large and slightly irregular, measuring 0.50 cm at the cranial pole, 0.94 cm at the caudal pole, and 2.0 cm in length. It is observed in its normal position cranial to the left renal artery. It is somewhat abnormal in appearance in that the caudal pole is enlarged with a hyperechoic nodule. No evidence of vascular invasion visualized.

HOSPITAL NAME

Brighton Greens VH

The right adrenal gland is normal in size measuring 0.53 cm at the caudal pole. It is observed in its normal position between the cranial aspect of the right kidney and the caudal vena cava. It is normal in appearance (uniformly hypoechoic) and shape with no evidence of a mass effect.

REFERRING VET

Dr. Robin Janeway

Spleen

The spleen is subjectively normal in size, echotexture is homogenous, and the splenic capsule is smooth with no irregularities. The blood flow through the hilus and splenic parenchyma appears normal. No focal parenchymal abnormalities are visualized.

INVOICE

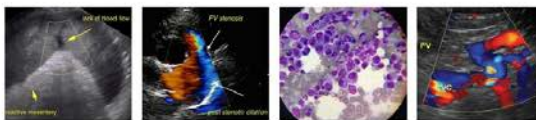
46966

Liver

DATE

3/26/23

The liver is large in size and irregular. The parenchyma is heterogenous in echotexture with subtle, indistinct focal mottling. The visible portions of the vasculature and biliary tract appear normal. There is a very large, mixed echogenic, lobulated, hyperechoic and mildly cystic mass effect arising from the caudal right aspect of the liver, measuring <8.7 cm x 7.59 cm.



PATIENT

Snuggles Hughes

SPECIES

Canine

BREED

American Eskimo

SEX

Spayed Female

AGE

13 Years

WEIGHT

8.7 kg

INTERPRETED BY

Kathleen Sennello DVM,
MS, Diplomate ACVIM
(Small Animal Internal
Medicine)

**IMAGING
PERFORMED BY**

Loetitia Saint-Jacques,
LVT

HOSPITAL NAME

Brighton Greens VH

REFERRING VET

Dr. Robin Janeway

INVOICE

46966

DATE

3/26/23

The gall bladder lumen is significantly distended. Some areas of the wall appear mildly thickened with adherent debris and there is organization and stranding of this debris into a mucocele. There is minimal surrounding inflammation and no obvious free fluid observed. The bile duct is normal/not visible. Findings are consistent with a mucocele. Consider close monitoring and initial medical management.

Gastrointestinal

The stomach contains minimal luminal contents. It measures at a normal thickness of <0.7cm with some variability due to the presence of rugal folds. The distinction of the gastric wall layers is adequate and there is no impression of reduced peristaltic activity. No masses or focal lesions were observed.

The visualized areas of duodenum, jejunum and ileum have a relatively uniform diameter with minimal fluid distension. Wall thickness is normal. Bowel loops follow a curvilinear path with distinct wall layering maintaining the typical 1:3 muscularis:mucosa layer ratio. Duodenum wall measures 0.47 cm. Jejunum wall measures 0.30 cm. Visualized peristalsis appears appropriate. There were no focal lesions consistent with obstruction or a mass effect observed.

The ileocecal junction was visualized and exhibited normal intact wall layering and is subjectively of normal thickness. Sections of colon are visualized with formed fecal material and gas shadowing distally. There is no observed focal or generalized colon wall thickening or loss of layering.

Pancreas

The pancreas is normal and isoechoic to surrounding mesentery. There is no evidence of nodules or cystic lesions. There is no evidence of regional mesenteric inflammation or fluid.

Free Abdomen

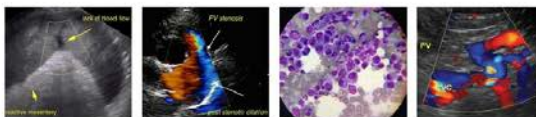
Evaluation of the peritoneal cavity did not reveal any evidence of effusion. There is a prominent lymph node at the ileocecal junction measuring 0.61 cm. The omentum is hyperechoic around the hepatic mass lesion.

PRIMARY FINDINGS

- Hyperechoic nodule in the caudal pole of the left adrenal gland – Left/right adrenomegaly could be consistent with neoplasia (e.g., adenoma, carcinoma, pheochromocytoma), hyperplasia, inflammation, other.
- Large, hyperechoic, lobulated, irregular, mildly cystic hepatic mass lesion – Findings are most consistent with a primary hepatic mass (adenoma, carcinoma, etc.). Other differentials exist.
- Distended gallbladder with organized intraluminal debris and minimal surrounding inflammation – The gall bladder changes are most consistent with a developing mucocele. Consider medical management and close monitoring for progression of this lesion.
- Prominent lymph node at the ileocecal junction – The prominent abdominal lymph nodes are most consistent with reactive lymphadenitis or lymphoid hyperplasia. Neoplastic infiltration is considered less likely.

SECONDARY FINDINGS

- Decreased corticomedullary distinction in both kidneys – The bilateral renal findings are consistent with age-related change.


PATIENT

Snuggles Hughes

SPECIES

Canine

BREED

American Eskimo

SEX

Spayed Female

AGE

13 Years

WEIGHT

8.7 kg

INTERPRETED BY

 Kathleen Sennello DVM,
 MS, Diplomate ACVIM
 (Small Animal Internal
 Medicine)

IMAGING PERFORMED BY

 Loetitia Saint-Jacques,
 LVT

HOSPITAL NAME

Brighton Greens VH

REFERRING VET

Dr. Robin Janeway

INVOICE

46966

DATE

3/26/23

INTERPRETATION OF THE FINDINGS & FURTHER RECOMMENDATIONS

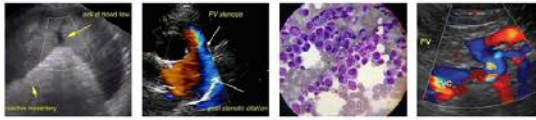
There is a large mass associated with the liver. This is likely significantly contributing to the elevation in ALP reported. This lesion is most consistent with a primary hepatic mass lesion. These lesions tend to be benign or slow to metastasize, and if surgical removal is possible, they can carry a good prognosis. This mass lesion appears to be displacing the gallbladder somewhat, which has a developing mucocele within it. At this time, there is no active inflammation, but this could easily develop into a surgical issue. Recommend starting Ursodiol therapy and consider a contrast CT scan to better evaluate the gallbladder and hepatic mass lesion for possible surgical intervention. If surgery is not an option, then therapy with Ursodiol and continued monitoring is warranted.

Recommend three view thoracic radiographs to evaluate for possible concurrent thoracic disease/involvement.

Additionally, there is a nodule in the caudal pole of the left adrenal gland. This could represent a benign or a neoplastic lesion and could be secreting hormone or be non-active. If this is secreting cortisol, it could as well be contributing to the elevation in ALP reported. These are my recommendations for further evaluation of an adrenal nodule:

- If signs of cushings are present, consider adrenal function testing. I prefer an ACTH stimulation test combined with an adrenal panel to the University of Tennessee's endocrine lab to look for atypical adrenal hormones as well as cortisol. (other testing can suffice)
- If adrenal dependent cushings is suspected and supported by adrenal function testing consider medical therapy with lysodren or trilostane and/or consider surgical removal (recommend referral to a board certified veterinary surgeon and possible pre op CT)-This can be a challenging surgery with significant risk for complication
- Recommend blood pressure evaluation-if hypertensive consider testing catecholamine levels for a possible pheochromocytoma
- Due to the invasive nature of these masses a CT scan is recommended to evaluate for metastasis and vascular invasion.
- If no symptoms of cushings are present, consider either referral for surgery or if surgery is not an option consultation with a veterinary oncologist regarding chemotherapeutic options and continued monitoring with ultrasound (in 4-6 weeks) can be considered.
- Some aggressive adrenal tumors can grow quickly and there is risk for acute hemorrhage from vascular invasion.

This lesion is relatively small at this time and does not appear invasive at this time. If a CT scan is performed to evaluate the gallbladder and liver, the adrenal nodule/mass can be evaluated at that time as well. If further intervention is not desired, I would still strongly recommend a blood pressure evaluation, as this could be contributing to the proteinuria reported.



PATIENT

Snuggles Hughes

SPECIES

Canine

BREED

American Eskimo

SEX

Spayed Female

AGE

13 Years

WEIGHT

8.7 kg

INTERPRETED BY

Kathleen Sennello DVM,
MS, Diplomate ACVIM
(Small Animal Internal
Medicine)

IMAGING PERFORMED BY

Loetitia Saint-Jacques,
LVT

HOSPITAL NAME

Brighton Greens VH

REFERRING VET

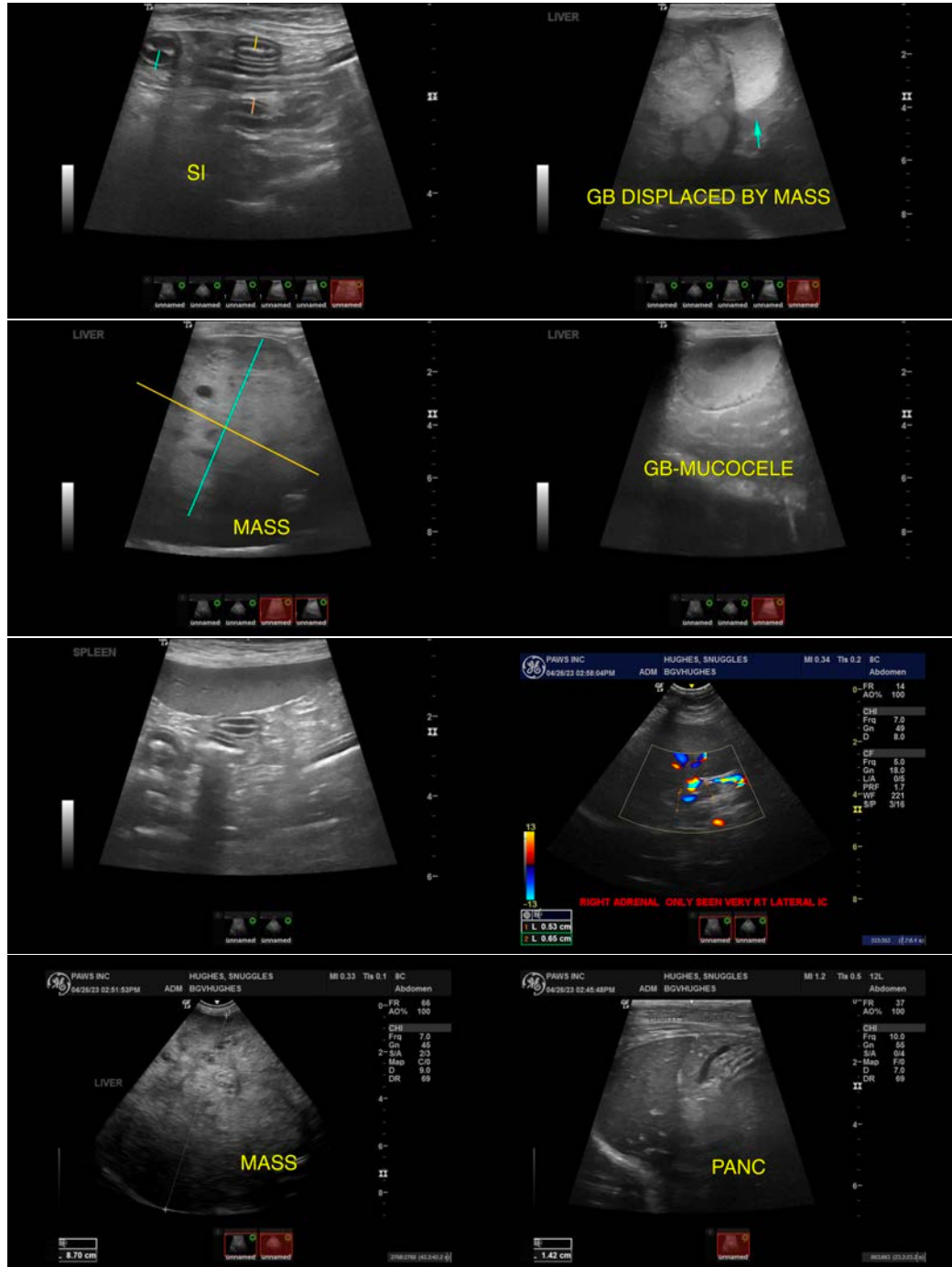
Dr. Robin Janeway

INVOICE

46966

DATE

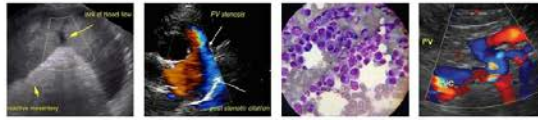
3/26/23



PAWS INC	HUGHES, SNUGGLES	MI 0.34	Tls 0.2	8C
04/26/23 02:58:04PM	ADM BOVHUGHES			Abdomen
				0-FR 14
				AO% 100
				CHF
				FRq 7.0
				Gn 48
				D 8.0
				CF
				FRq 5.0
				GN 18.0
				LIA 0/5
				PRF 1.7
				4-WF 221
				II-FP 316

PAWS INC	HUGHES, SNUGGLES	MI 0.33	Tls 0.1	8C
04/26/23 02:51:53PM	ADM BOVHUGHES			Abdomen
				0-FR 68
				AO% 100
				CHF
				FRq 7.0
				Gn 45
				2-SA 32
				Map C/3
				D 8.0
				DR 68

PAWS INC	HUGHES, SNUGGLES	MI 1.2	Tls 0.5	12L
04/26/23 02:45:48PM	ADM BOVHUGHES			Abdomen
				0-FR 37
				AO% 100
				CHF
				FRq 10.0
				Gn 55
				SA 04
				2-Map F/0
				D 7.0
				DR 68



PATIENT

Snuggles Hughes

SPECIES

Canine

BREED

American Eskimo

SEX

Spayed Female

AGE

13 Years

WEIGHT

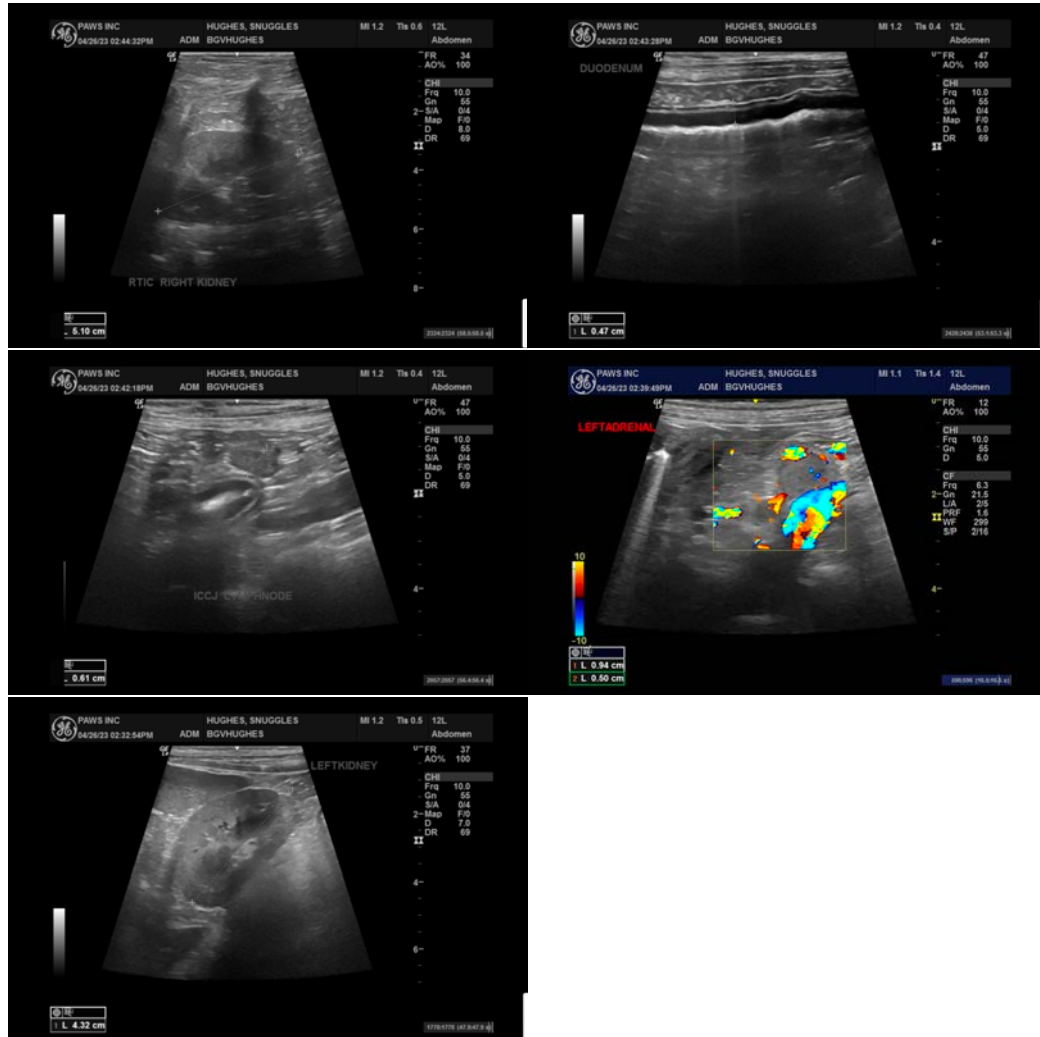
8.7 kg

INTERPRETED BY

Kathleen Sennello DVM,
MS, Diplomate ACVIM
(Small Animal Internal
Medicine)

IMAGING PERFORMED BY

Loetitia Saint-Jacques,
LVT



HOSPITAL NAME

Brighton Greens VH

REFERRING VET

Dr. Robin Janeway

INVOICE

46966

DATE

3/26/23

The information and recommendations provided are based on the images presented by the referring veterinarian/sonographer. No evaluation can be communicated regarding pathology that was not visible in the image/video clips provided.

Thank you for this referral. If the clinical or image interpretation does not parallel your findings or if I can be of any further assistance please contact me.

Kathleen Sennello DVM,MS, Diplomate ACVIM (Small animal Internal Medicine)

kathleen.sennello@sonopath.com